

X-ray diagnosis of gastroesophageal reflux disease

M.D. Levin

Department of Pediatric Radiology of 1st city Hospital, Minsk, Belarus.

Dorot-Netanya Geriatric Medical Center, Israel.

Michel D. Levin, MD, PhD.

Radiologist of State Geriatric Center, Netanya, Israel.

Amnon ve-Tamar, 1/2, Netanya, 42202, Israel.

Tel: 972-53-8281393

Fax: 972-9-8630151.

Nivel70@hotmail.com; michael.levin@dorot.health.gov.il

<http://orcid.org/0000-0001-7830-1944>

<http://www.anorectalmalformations.com>

Scopus Author ID: 7402571390

The aim of this work is to improve the radiological study for detection of the gastroesophageal reflux disease (GERD) in the early stage.

Material and Methods. 372 X-ray studies of the esophageal-gastric junction (EGJ) were selected retrospectively, including 242 patients aged 1 year -15 years, 32 aged 16-45 years and 98 patients aged 62-92 years. Standard X-ray examination of the upper digestive tract was supplemented by the abdominal compression during the barium reception. The radiologic symptoms of GERD which differ from the image of normal GEJ are described, including the shortening and weakness of the lower esophageal sphincter (LES), the expansion and weakness of the phrenic ampulla.

Results. In all children who had at least one of the typical clinical symptoms of GERD, the diagnosis was confirmed by X-ray examination. X-ray signs of GERD were detected in 11 of 23 children who did not have clinical manifestations of GERD. X-ray evidence of GERD was found in 17 of 32 adult patients without clinical symptoms of GERD. The length of the LES in them was significantly shorter than the norm (2.31 ± 0.11 cm vs 3.60 ± 0.08) ($p < 0.001$). The GERD was established in 91 (98%) of 93 elderly with symptoms of intestinal dyskinesia. The length of the LES in them was 1.96 ± 0.19 cm ($p < 0.001$).

Conclusion. We found correlation between the results of histological and radiological studies. In the initial stage of GERD, the penetration of aggressive gastric contents is limited to the intraabdominal part of the LES. This leads to weakness of the sphincter and its expansion. In X-ray examination, this is detected as a shortening of the LES. Diagnosis of GERD is improved due to provocative tests. The described technique allows to diagnose the early stages of the disease, when the acid from the stomach does not yet penetrate esophagus and therefore cannot be registered by pH-metry.

Keywords: diagnosis; gastroesophageal reflux disease; lower esophageal sphincter; pathophysiology; X-ray examination.

Abbreviations:

GERD – gastroesophageal reflux disease; LES – lower esophageal sphincter; PS – proximal sphincter; GEJ – gastro-esophageal junction; SHE - sliding esophageal hernia; SR – Schatzky ring.

Introduction. In the middle of the 20th century, X-ray examination was the main method of instrumental diagnosis of gastroesophageal reflux disease (GERD). The proof of reflux was the spontaneous penetration of barium from the stomach into the esophagus. This method was poorly correlated with the clinical manifestations of the disease. In a significant number of patients with a typical picture of GERD, reflux was not detected in this study. Then a water-siphon test was proposed to increase the accuracy of the radiographic examination. After drinking barium, the patient, while in a horizontal position, drank water through a straw from a glass located at his head. At present, the pH-metry in the supra-diaphragm part of the esophagus is recognized as the gold standard. The X-ray method proved to be highly sensitive because it provoked reflux in 95% of children with positive pH-metry [1]. But it was little specific in comparison with pH monitoring [2]. Since the pH-metry was a priori considered to be an accurate method, compared to which an x-ray study produced about 30% of false positive conclusions, the X-ray study began to be neglected [3].

Limits of the norm with prolonged pH-metry are reflux episodes with $\text{pH} < 4$ over $\geq 4.2\%$ of the time from the 24-hour measurement period [4]. Studies of recent years raise doubts about the accuracy of these criteria. Initially, the pH normal limits were based on the selection of patients without the typical symptoms of GERD and the absence of inflammation in endoscopic examination. First, GERD for a long time can proceed without clinical manifestations. So, for example, with a screening gastroscopy examination of 6,683 healthy Koreans, 14.66% had GERD diagnosed [5]. In another study of 57 healthy subjects, 13 (23%) had an esophageal pathology in endoscopy, and 10 (17%) had an

esophageal hernia [6]. Secondly, patients with GERD could be included in the group of healthy patients with endoscopy-negative reflux disease or (nonerosive reflux disease) [7,8,9]. As a proof of the erroneousness of the pH range, frequent examples of patients with GERD can be used, in which 24-hour pH-metry did not detect reflux disease, including in observations where patients needed surgical treatment [10,11]. Thirdly, as histological studies of recent years have shown, GERD begins with reflux only in the abdominal segment of the esophagus, i.e. intra-abdominal, part of the lower esophageal sphincter (LES), when the acidic gastric contents do not yet enter the esophagus, and, consequently, the disease cannot be detected using pH-metry.[12]

Based on the laws of the physiology of the gastro-esophageal junction (GEJ), we developed a method for radiographic examination of patients with suspected GERD, where the symptoms of the disease are contrasted with the radiographic image of GEJ in healthy people [13].

Material and methods: In retrospectively, 372 X-ray studies of GEJ were selected, which were divided into 4 groups. The first group consisted of 219 children aged 3 months to 15 years who had at least one of the typical symptoms of GERD. Children of the first 1.5 years of life were more likely to have recurrent vomiting, anxiety in feeding, poor sleep, anemia and hypotrophy. In other cases, there were pulmonary manifestations: a persistent cough, repeated pneumonia. The older children were dominated by chest or abdominal pain, heartburn and belching. In 23 children of the 2nd group there were no clinical symptoms of GERD. X-ray examination was conducted for localization of foreign bodies, space-occupying lesions of the chest and abdominal cavity, as well as for determining the cause of abdominal pain. In 32 patients of the 3rd group aged 16-45 years, X-ray examination was performed to determine the cause of anemia and / or recurrent pain in the abdomen. In 98 patients of the 4th group aged 62-92 years, symptoms of functional dyspepsia of an undetermined nature prevailed: belching, constipation, bloating, epigastric pain (**Table 1**).

Table 1. Distribution of patients by age and clinical symptoms.

groups	symptomatology	1 - 15 years	16 – 45 years	62 – 92 years
1st	at least one symptom of GERD	219		
2nd	without GERD symptoms	23 (12)		
3rd	without GERD symptoms		32 (15)	
4th	symptoms of functional dyspepsia			98 (2)
	without X-ray symptoms GERD	12 (52%)	15 (47%)	2 (2%)
Total	372	242	32	98

Red color indicates cases without X-ray confirmation of GERD among patients without typical clinical symptoms GERD.

X-ray examination Standard X-ray examination of the upper parts of the digestive tract was carried out in a horizontal position. The patient lay on his back and drank a barium through a straw from a can that was near his head. After drinking about 200 ml (out of 250), during the last sips, the abdominal wall was compressed by the radiologist hand for 30 seconds. Several X-ray radiographs were made during the study. Babies drank a barium suspension from a bottle with a pacifier.

Statistical analysis was performed by the method of the Student's t-test. The level of significance was set as $P < 0.05$.

Results. Abdominal compression causes an increase an intra-abdominal and intragastric pressure. The level of pressure in the stomach does not depend on the strength of the compression by the hand, but on the reactive contraction of the anterior abdominal wall. This leads to a reflex increase of the LES pressure [14,15]. Normally, the peristaltic wave in the esophagus pushes out bolus into the

stomach without stopping despite an increase of the LES pressure. This was observed in 29 cases, marked in the **Table 1.** in red.

X-ray symptoms GERD. X-ray symptoms GERD is something that is different from the norm. In some patients with GERD, abdominal compression results in LES contraction that prevents the bolus moving from esophagus into the stomach and resulting in a zone without contrast agent between the esophagus and the stomach containing barium (**Figure 1**).

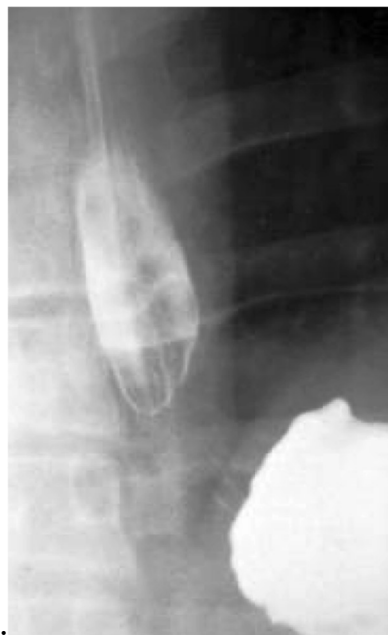

Figure 1. X-ray picture of the GEJ. During the abdominal compression there is a contraction of the LES, which caused the barium bolus to stop moving. The length of the gap between the barium-containing esophagus and the stomach is a LES contraction.

The stop of the bolus over the LES is due to the weakness of the peristaltic wave as a result of the inflammatory process and the dilatation of the lumen in the lower esophagus. The length of the gap without barium is a length of the contracted LES. On the radiographs, we measured the length of the LES and the width of the supra-diaphragmatic esophagus. On radiograph all objects are magnified in

proportion to the distance between the object (LES) and the place of registration of the image (film). The true parameters were calculated using the formula:

$$d = D \times k;$$

where “**d**” is the true size; “**D**” is the value of its image on the radiograph; “**k**” is the coefficient of magnified, which is the ratio of the true height of the first lumbar vertebra to its image on the radiograph. (The true height of L-1 in adults is 2.3 cm. With a focal length of 100 cm, the "k" is from 0.8 in infants to 0.72 in adults).

In 29 patients without GERD (red), the LES cannot be measured, since a barium passed from the esophagus into the stomach without stopping, despite the abdominal compression. To determine the standards, we selected 42 studies, including 15 of the 1st group, 11 of the 2nd group, and 17 of the 3rd group. These were patients with mild GERD, in whom the LES did not change significantly. On the radiographs we measured the length of the LES and the width of the esophagus over the diaphragm (**Table 2**). The measurement results were completely coincided with the results of the measurement by the manometric method [16,17].

Table 2. Normal length of LES in different age groups

	Length of the lower esophageal sphincter (cm)					
Age	Up to 1 year	1-3 years	4-7 years	8-10 years	11-15 years	21 – 65 years
Limits	0.7 – 1.0	1.2 – 1.5	1.5– 1.8	1.9 – 2.3	2.3 – 2.9	3.2 – 4.2
M± M	0.86±0.03	1.40±0.02	1.72±0.07	2.10±0.05	2.45±0.11	3.60±0.08

In healthy patients, the width of the esophagus is almost the same all over its length and does not exceed 1.2 cm in children and 1.5 cm in adults.

All the symptoms of GERD, which distinguish the function of GEJ from the norm, can be divided into 3 categories: 1) fluoroscopic, which are recorded during fluoroscopic observation; 2) changes of the LES and 3) changes of the distal esophagus (**Table 3**).

Table 3. Radiographic symptoms of GERD

Fluoroscopic symptoms	LES changes	Esophageal changes
Free reflux from the stomach to the esophagus	Shortening of the LES with angular opening of its abdominal part (Figure 2)	Expansion of the esophagus more than 1.2 cm in children and 1.5 cm in adults
Provoked reflux during abdominal compression	Shortening of the LES almost twice with respect to the age norm (Figure 3)	Slow and / or incomplete evacuation of barium from the esophagus
LES contraction during abdominal compression	Longitudinal folds at the level of the LES (Figure 4)	Picture of the phrenic ampulla and proximal sphincter (Figure 4)

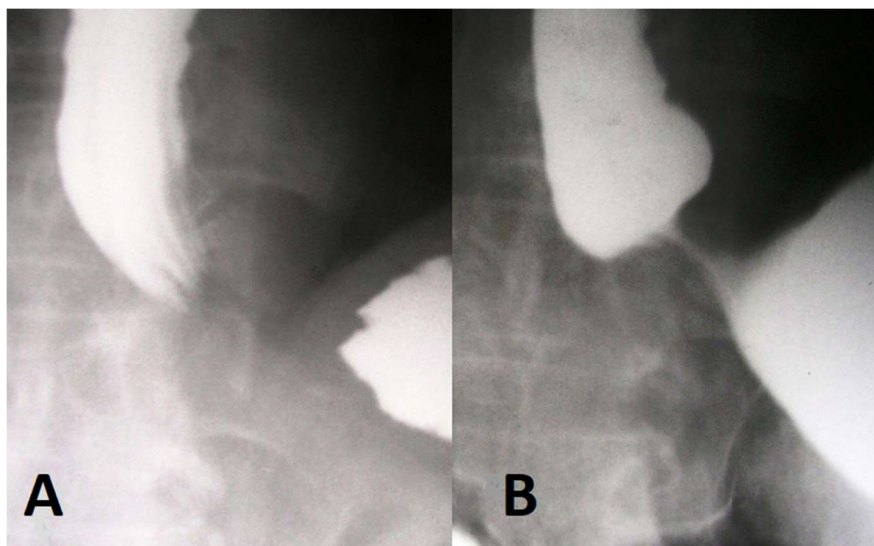


Figure 2. Radiographs of GEJ of adult patient during the abdominal compression. **A)** There was a contraction of the LES; **B)** In the process of compression, angular deformity of the stomach appeared as a result of the opening of the abdominal portion of the LES. The expansion of the esophagus over the LES appeared (Phrenic ampulla).

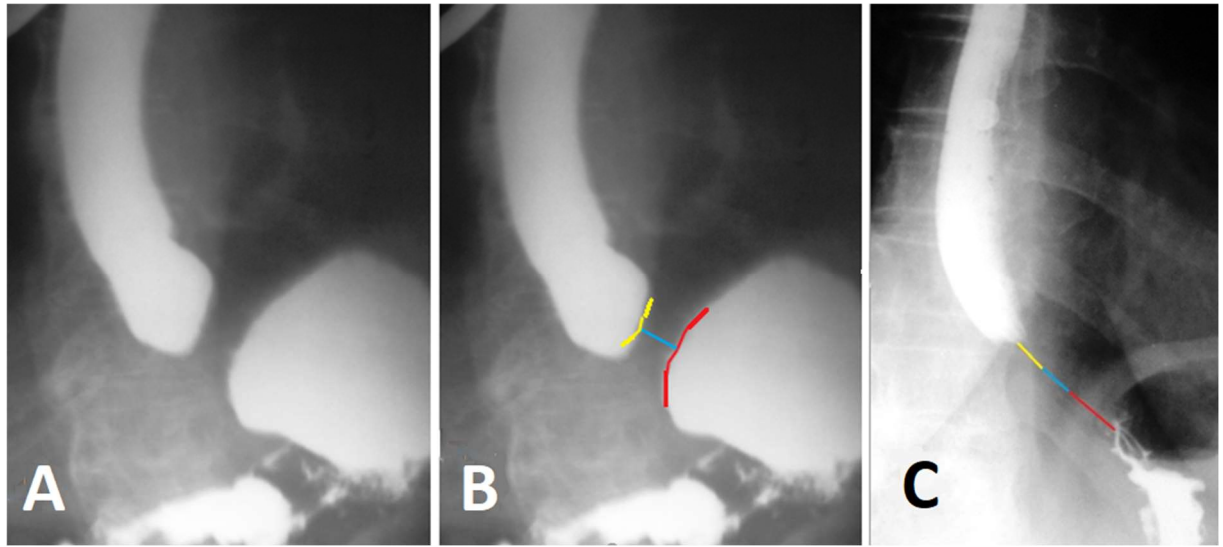


Figure 3 Radiographs of an adult patient with GERD. (A-B) - in a horizontal position with the abdominal compression. The sharp shortening of the LES as a result of the opening of the supra-diaphragmatic part of the LES (its walls are colored yellow) and the intraabdominal part of the LES (red color) is determined. Only the intra-diaphragmatic part of the sphincter is in the contracted state. (C) - in the vertical position all three components of the LES are in the contracted state.

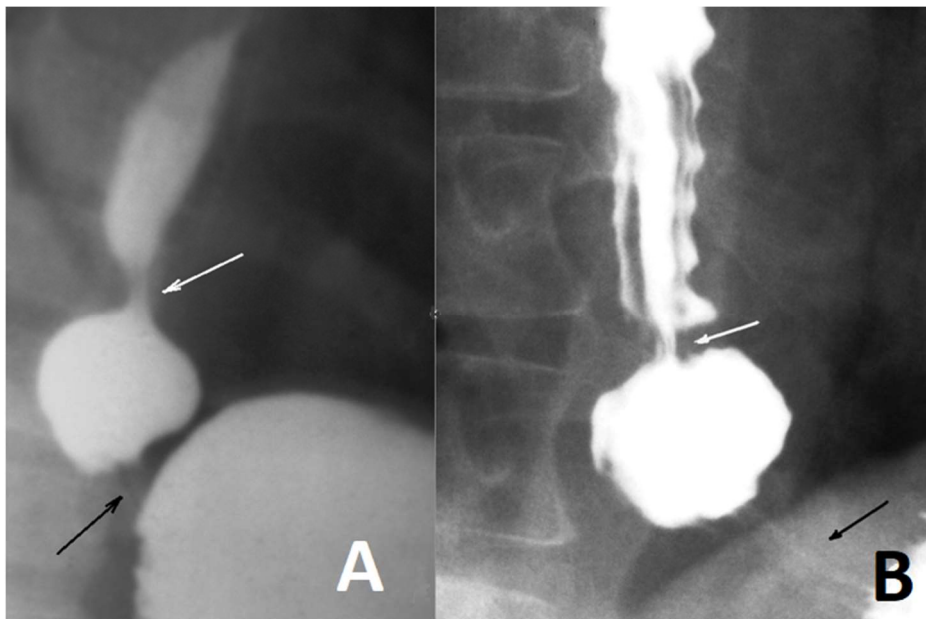


Figure 4. The ampulla of the esophagus appeared as a result of the contraction of the LES in response to the abdominal compression. (A) The child is 7 years old; (B) The elderly person. The black arrow points to the LES, and the white arrow points to the proximal sphincter, which closes the ampulla to create a threshold pressure in it to open the LES.

In all children of the 1st group who had at least one of the typical clinical symptoms of GERD, the diagnosis was confirmed by X-ray examination. X-ray signs of GERD were detected in 11 of 23 patients of the 2nd group who did not have clinical manifestations of the disease. X-ray evidence of GERD was found in 17 of 32 patients in the 3rd group without clinical symptoms of GERD. The length of the LES in them was significantly shorter than the norm (2.31 ± 0.11 cm vs 3.60 ± 0.08) ($p < 0.001$). The GERD was established in 91 (98%) of 93 patients of the 4th group with symptoms of intestinal dyskinesia. The length of the LES in them was 1.96 ± 0.19 cm ($p < 0.001$).

Discussion

The studies of Chandrasoma et al reject two false dogmas that result in two widely believed fundamental errors. 1). These are the belief that cardiac epithelium normally lines the proximal stomach and (2) that the GEJ is defined by the proximal limit of rugal folds. When these false dogmas are eradicated by existing powerful evidence, the pathology of GERD falls into the following stages, all defined by histology: (a) The normal state where the esophageal squamous epithelium transitions at the GOJ to gastric oxyntic epithelium with no intervening cardiac epithelium; (b) cardiac metaplasia of the squamous epithelium due to exposure to gastric juice results in cephalad movement of the squamo-columnar junction (SCJ). This creates the squamo-oxyntic gap and the dilated distal esophagus, which is distal to the endoscopic GOJ. The length of the squamo-oxyntic gap in the dilated distal esophagus is concordant with the shortening of the abdominal segment of the lower esophageal sphincter (LOS); (c) in the early stages, the gap is < 5 mm and the LOS retains its competence. Reflux is uncommon and patients are asymptomatic; (d) the squamo-oxyntic gap increases in length, concordant with the amount of shortening of the LOS, which becomes increasingly incompetent. At a gap length of 5-15 mm, reflux is sufficient to cause symptoms, but in most patients, symptoms are controllable and the patients are normal at endoscopy. The gap is entirely within the dilated distal esophagus, which is mistaken by present criteria for proximal stomach. (e) The last stage of GORD is when the squamo-oxyntic gap is > 15 mm. In these

patients, reflux is severe with increasingly uncontrollable symptoms and columnar lined esophagus, both irreversible states [12,18].

The results of these histological studies correlate with the results of our radiological studies. For example:

1). **A.** Based on histological studies, it has been shown that the reflux of gastric contents begins with reflux into the intraabdominal part of the LES, which is accompanied by damage to this section and its dilation. The authors describe different degrees of damage of the LES, depending on the length of the squamo-oxyntic gap.

B. We described the weakness of the LES as its shortening as result of the expanding of its intra-abdominal part during X-ray study. The degree of its weakness depends on the strength of provocation: the 1st degree - the appearance of angular deformity of the "stomach" only during the abdominal compression; 2nd - without provocation; 3rd - the sharp shortening of the LES [13].

2) **A.** The pH-metry is not able to detect GERD when reflux of acidic gastric contents penetrates only into the abdominal part of the LES. Endoscopy with histological examination diagnoses GERD based on the identification of cardiac mucosa and expansion of LES.

B. X-ray examination records the expansion inside the abdominal portion of the LES. Thus, the statement that x-ray study is produced about 30% of false positive conclusions [3] indicates low sensitivity of pH-metry.

3). **A.** The concept of a sliding esophageal hernia (SHE) is based on two statements: a) cardiac epithelium lining the stomach; b) the GEJ is defined by the proximal limit of rugal folds. Histological studies have shown that these statements are erroneous. In the works of Chandrasoma and co-workers there is no place for SHE.

B. Our x-ray studies confirm the results of histological studies. Expansion of the esophagus occurs in response to the LES contraction. This cannot be a crural diaphragm, (1) because the striated muscle of the crural diaphragm cannot be in a contracted state for 30 seconds. (2) The thickness of the muscular layer of the

diaphragm in an adult does not exceed 0.5 cm. During a contraction, the diaphragm cannot squeeze the esophagus longer than 1 cm. Meanwhile, the contraction length at the level of the GEJ in patients of the 3rd group was 2.31 ± 0.11 cm, and in patients of the 4th group it was 1.96 ± 0.19 cm. (3) Proportional to the severity of GERD, there is a significant widening of the hiatal canal when. Therefore, the crural diaphragm contraction cannot block of the esophagus lumen. (4) In a manometric study, the distal peak of pressure is caused by the contraction of the LES, and the proximal one by the contraction of the functional sphincter, which we call the proximal sphincter (PS) .

X-ray studies indicate that the extended intestinal segment above the diaphragm, formerly considered SEH, is an ampulla of the esophagus, regardless of size [13,19,20].

In contrast to anatomical sphincters which function from birth (upper esophageal sphincter, LES, pyloric sphincter and internal anal sphincter), functional sphincters (Kapanji, Ochsner, several colonic sphincters, etc.) appear during ontogenesis. The ampulla of the esophagus is the last peristaltic wave. As a result of the inflammatory process, expansion the lumen and hypertrophy of the wall, the force of its contraction is insufficient to create a threshold pressure to open the LES. Contraction of the PS closes of the esophageal lumen in the proximal part of the ampoule. At some point, the ampoule is a closed cavity between the LES and the PS. Movement of peristalsis through this segment of the esophagus increases the pressure in the ampoule. When the pressure in the ampulla reaches the threshold level, the LES opens and the ampoule injects its contents into the stomach (see Figure 4. A). If there were no PS, it would be necessary to create a threshold pressure in the entire esophagus over the LES. This is what happens in severe cases of GERD, when the PS ceases to function. If, as a result of the inflammatory process, a fibrous replacement of the muscular segment of PS arises, a rigid narrowing of the esophagus occurs (Schatzki ring) [20] (see Figure 4.B).

Figure 5 shows scheme of the pathogenesis of GERD.

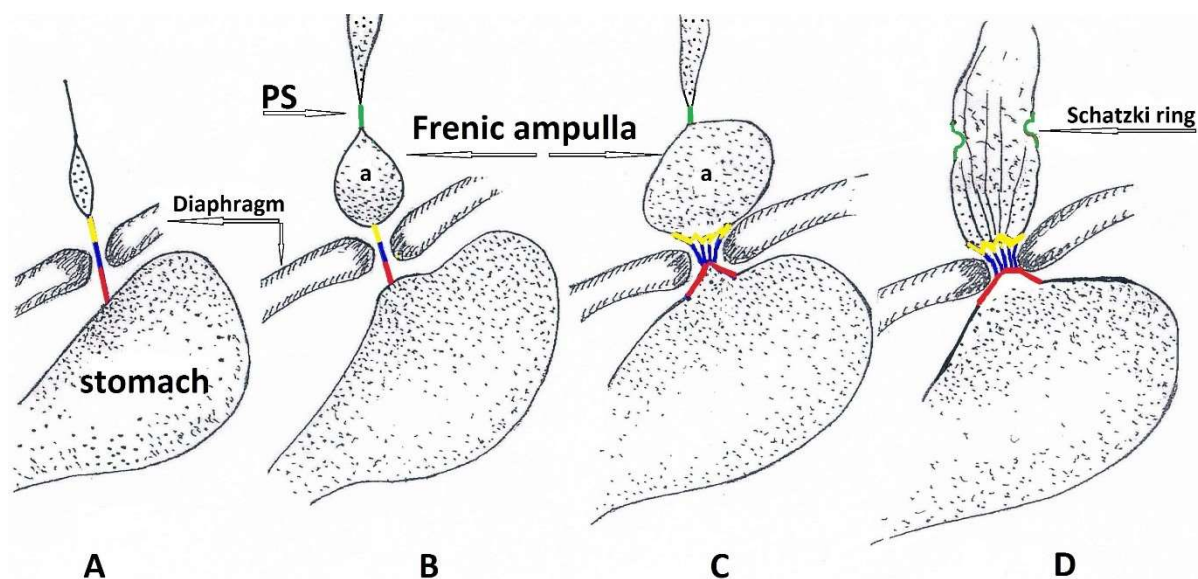


Figure 5. Scheme of progression the LES incompetence.

A. The normal length of the three parts of the LES (red-intraabdominal, blue-diaphragmatic, yellow-supradiaphragmatic). **B.** Shortening of the intraabdominal part of the LES. Ampulla and PS (green) appeared. **C.** The ampulla increased in size. The shortening of the LES due to the disclosure of both supradiaphragmatic and intraabdominal portions during provocations (high intragastric pressure). Expansion of the hiatal hiatus combined with the appearance of folds at the level of the diaphragm. **D.** The shortening of the LES is independent of provocation. Only its diaphragmal part is contracted. The crural hiatus is expanded so the diaphragm does not affect the contraction of the GEJ. In place of the PS, a fibrous tissue appeared (Shatsky's ring).

Conclusion

We found a correlation between the results of histological and radiological studies. In the initial stage of GERD, the penetration of aggressive gastric contents is limited to the intraabdominal part of the LES. This leads to weakness of the sphincter and its expansion. In X-ray examination, this is detected as a shortening of the LES. Diagnosis of GERD is improved due to provocative tests: drinking barium and

abdominal compression. The described technique allows to diagnose the early stages of the disease, when the acid from the stomach does not yet penetrate into the esophagus and therefore cannot be registered by pH-metry.

References

1. Blumhagen JD, Christie DL. Gastroesophageal reflux in children: evaluation of the water siphon test. *Radiology*. 1979 May;131(2):345-9.
2. Fiorentino E¹, Barbiera F, Cabibi D, et al. Barium study associated with water siphon test in gastroesophageal reflux disease and its complications. *Radiol Med*. 2007 Sep;112(6):777-86. Epub 2007 Sep 20.
3. Fiorentino E, Matranga D, Pantuso G, et al. Accuracy of the water-siphon test associated to barium study in a high prevalence gastro-oesophageal reflux disease population: a novel statistical approach. *J Eval Clin Pract*. 2010 Jun;16(3):550-5. doi: 10.1111/j.1365-2753.2009.01158.x. Epub 2010
4. Kandulski A¹, Peitz U, Mönkemüller K, et al. GERD assessment including pH metry predicts a high response rate to PPI standard therapy. *BMC Gastroenterol*. 2013 Jan 16;13:12. doi: 10.1186/1471-230X-13-12.
5. Yoo SS, Lee WH, Ha J, Choi SP, Kim HJ, Kim TH, Lee OJ. The prevalence of esophageal disorders in the subjects examined for health screening. *Korean J Gastroenterol*. 2007 Nov;50(5):306-12.
6. Stål P, Lindberg G, Ost A, Iwarzon M, Seensalu R. Gastroesophageal reflux in healthy subjects. Significance of endoscopic findings, histology, age, and sex. *Scand J Gastroenterol*. 1999 Feb;34(2):121-8.
7. Jones R, Galmiche JP. Review: what do we mean by GERD? –definition and diagnosis. *Aliment Pharmacol Ther*. 2005 Aug, 22 Suppl 1:2-10.

8. Enerenziani S, Silfrim D. New development in detection of gastroesophageal reflux. *Curr Opin Gastroenterol*. 2005 Jul; 21 (4)450-453.
9. Weber C, Davis CS, Fisichella PM. Current applications of evolving methodologies in gastroesophageal reflux disease testing. *Dig Liver Dis*. 2011 May;43(5):353-7.
10. Angulo JM, Tovar JA, Eizaguirre I. False negatives in pH measurement. A retrospective study of 12 surgical cases. *Cir Pediatr*. 1990 Jan;3(1):3-7.
11. Tovar JA, Angulo JA, Gorostiaga I, Arana J. Surgery for gastroesophageal reflux in children with normal pH studies. *J Pediatr Surg*. 1991 May; 26(5): 541-545.
12. Chandrasoma P^{1,2}, DeMeester T³. A New Pathologic Assessment of Gastroesophageal Reflux Disease: The Squamo-Oxyntic Gap. *Adv Exp Med Biol*. 2016;908:41-78. doi: 10.1007/978-3-319-41388-4_4.
13. Levin MD, Korshun Z, Mendelson G. Pathological physiology of gastroesophageal reflux disease. Hypothesis (Review). *Experimental and clinical gastroenterology (Moscow)* 2013; 5: 72-88.
14. Cohen S. Esophageal motility disorders and their response to calcium channel antagonists. The sphinx revisited. *Gastroenterology*. 1987 Jul;93(1):201-3.
15. Shafik A¹, Shafik I, El-Sibai O, Shafik AA. On the pathogenesis of gastroesophageal reflux: the concept of gastroesophageal dyssynergia. *J Thorac Cardiovasc Surg*. 2005 Aug;130(2):401-7.
16. Ackermann C¹, Rothenbühler JM, Martinoli S, Müller C. Esophageal manometry prior to and following anti-reflux surgery. *Schweiz Med Wochenschr*. 1991 May 25;121(21):797-800.
17. Marshall RE¹, Anggiansah A, Anggiansah CL, et al. Esophageal body length, lower esophageal sphincter length, position and pressure in health and disease. *Dis Esophagus*. 1999;12(4):297-302.

18. Chandrasoma P. How the pathologist can aid in the assessment of gastroesophageal reflux disease. *Curr Opin Gastroenterol*. 2018 Apr 27. doi: 10.1097/MOG.0000000000000446.
19. Levin MD, Korshun Z, Mendelson G. Gastric Motility. Hypothesis. *Eksp Klin Gastroenterol*. 2016; 134(10):88-96.
20. Levin MD, Mendelson G. Schatzki ring as a symptom gastroesophageal reflux disease. *Vestn Rentgenol Radiolog*. 2015 Jan-Feb; (1):5-15.