

Aorto-Esophageal Sphincter and its role in the pathogenesis of the gastroesophageal reflux: cases report and analysis

Abstract

Conventional methods of radiographic examination in gastroesophageal reflux disease (GERD) are not used due to low reliability. A new method of radiographic examination of the esophagus is described in 7 patients with GERD, in whom, unlike 79 examined patients, examined by the same method a physiological sphincter was found at the level of the aortic arch, which was responsible for the occurrence of non-esophageal symptoms. We call it aorto-esophageal sphincter (AES). It has been shown that in healthy individuals, two anatomical sphincters (upper esophageal sphincter and lower esophageal sphincter - LES) ensure normal functioning of the esophagus. LES prevents reflux of aggressive gastric contents into the esophagus. The crural diaphragm contracts briefly during deep inspiration and increased gastric pressure, which enhances the antireflux function of the LES. The LES does not move into the chest. In patients with GERD, the esophagus expands, and its peristalsis weakens. For the last peristaltic wave to be able to create a pressure in the dilated esophagus that can open the LES and is greater in magnitude than the pressure in the stomach, an injection chamber (phrenic ampulla) arises above the LES. Contraction of the peristaltic wave above the ampulla allows creating a pressure above the LES that is necessary for the contracting ampulla to inject a bolus into the stomach. This is how a functional proximal sphincter (PS) of 0.5-0.7 cm in length arises above ampulla. The article describes for the first time a functional sphincter at the level of the aortic arch, which occurs in patients with GERD over the age of 50. This AES plays a role in the occurrence of non-esophageal symptoms.

Keywords: x-ray diagnosis GERD, gastroesophageal reflux disease, esophageal sphincters, esophageal pathophysiology, pH monitoring

Volume 16 Issue 1 - 2025

Michael D Levin, MD, PhD, DSc^{1,2}

¹Department of Pediatric Radiology of the 1-st State Hospital, Belarus

²Dorot. Medical Center for rehabilitation and geriatrics, Israel

Correspondence: Michael D Levin, Department of Radiology, Dorot, Medical Center for rehabilitation and geriatrics, Netanya, Israel, Email nivel70@hotmail.com

Received: January 10, 2025 | **Published:** January 17, 2025

Abbreviations: GERD, Gastroesophageal Reflux Disease; UES, Upper Esophageal Sphincter; LES, Lower Esophageal Sphincter; EGJ, Esophagogastric Junction; PS, Proximal Sphincter; AES: Aorto, Esophageal Sphincter, IR, Index Reflux.

Introduction

The aortic arch normally exerts pressure on the left wall of the esophagus at the level of the 5-6 thoracic vertebrae, which causes a slight physiological narrowing. In healthy individuals, this anatomical feature does not cause any symptoms. There is no information in the literature about the role of this narrowing in gastroesophageal reflux disease (GERD). We present a series of seven patients with GERD, in whom the inflammatory process in the esophagus caused by the effect of hydrochloric acid led to the formation of a functional sphincter at the level of the aortal narrowing of the esophagus.

Materials and methods

Seven patients aged 46–72 (mean age 62 years) (M: F=4:3) had a long history of peptic disease. Symptoms changed during different periods of the disease. Usually the first symptom was heartburn, which became less frequent with age and replaced by pressing pain behind the breastbone, postprandial pain in the hypochondrium, or non-localized abdominal pain. Six patients had nonesophageal symptoms, and one of them had only nonesophageal symptoms: debilitating cough, voice change, and night awakenings since patient was choking on their own saliva.

The method of X-ray examination is based on a well-known physiological pattern: an increase in pressure in the stomach causes a reflex contraction of the upper and lower esophageal sphincters.^{1,2}

The patient, lying on the X-ray table, continuously drinks barium suspension through a straw from a jar standing at his head. When the barium runs out (200-250 ml), he immediately raises his straightened legs. At this moment, an x-ray was taken from the pharynx to the body of the stomach. A delay between the last swallow and the x-ray might necessitate a repeat examination because the x-ray will only show traces of barium in the esophagus. After the first radiograph, the subject gets up, but after 5 minutes, he lies down again on the X-ray table. A second radiograph taken at rest to determine the completeness of barium evacuation into the stomach and the possibility of free reflux.

Radiometric analysis. As shown in previous studies, in healthy individuals the peristaltic wave overcomes the high tone of the LES, caused by increased pressure in the stomach, and expels the bolus into the stomach despite the high pressure in it. Therefore, it is impossible to see a contracted LES in healthy people. The inflammatory process in GERD weakens the force of the peristaltic wave, resulting in the LES contraction and barium being trapped between the contracted upper and lower esophageal sphincters. The distance between the barium in the esophagus and in the stomach, which does not contain a contrast agent, is equal to the length of the LES. The true length of the LES in adults ranges from 3.2 to 4.2 cm (3.60±0.08 cm).³ However, on the radiograph all values are greater than the true ones due to projection magnification. For an average patient size and standard shooting conditions, the projection distortion coefficient is 0.72. If the first lumbar vertebra is visible on the radiograph, the projection distortion coefficient can be accurately calculated. It is equal to the ratio of the true height of L-1 (2.2 cm in adults) to its height on the radiograph. Shortening of the LES relative to the minimum limit of the norm indicates GERD.³⁻⁵

The tight filling of the esophagus allows determining its width and contours, as well as the presence of constrictions and erosions. A sign of pathological expansion is the detection of the phrenic ampulla, which is located above the LES. Between the body of the esophagus and the ampulla, a functional sphincter (proximal sphincter - PS) is determined, 0.5-0.7 cm long, which during contraction maintains pressure in the ampulla higher than in the stomach. If this sphincter cannot withstand the pressure and relaxes during the LES opening, the pressure in the ampulla drops and the contents of the stomach penetrate the esophagus. In addition, contraction of the PS during relaxation of the LES can prevent the penetration of gastric contents into the proximal parts of the esophagus.⁶ Some authors believe that this narrowing, which we call the PS, is caused by the LES displaced into the chest cavity. This displacement is supposedly due to shortening of the esophagus.^{7,8} Due to this error, a phrenic ampulla more than 2 cm wide suddenly turns into a sliding hiatal hernia. As shown by numerous evidence, the LES is fixed and does not move. The idea that the esophagus shortens is based on the shortening complex (esophagus + LES) in GERD. However, this complex is shortened only due to the shortening of the LES in GERD, the anatomy and physiology of which differs from the esophagus.^{3,6} These comments are essential to understanding the radiographs where we found pathological narrowing of the esophagus that occurs in GERD and often causes nonesophageal symptoms.

Case 1:

A 72-year-old man had a debilitating cough, a change in voice, and a feeling of a foreign body in the throat for 4 months. Very rarely, small pieces of food appear in the mouth. Within a month, he wakes up at night, as he chokes on saliva. He does not feel any acid or bitterness in his mouth. He has not heartburn, pain, or dysphagia. About 15 years ago, he had heartburn and chest pressure. PPI treatment did not bring relief. The symptoms disappeared immediately after he swallowed tablet with diameter ≈ 3 cm. Since then, he felt healthy, did not go to the doctors, did not take any treatment, and did not follow any dietary restrictions. In Table 1, the patient rated the severity of symptoms before treatment with a black color and 25 days later with a red one. The results of the study are presented in Figure 1.

Table 1 Gastroesophageal reflux disease screening questionnaire (Case 1)

How bothersome are you by the symptoms described below?						
There is no symptom - 0; a strong symptom - 5.						
	0	1	2	3	4	5
Hoarseness or alteration of voice			x		x	
Sore throat or desire to get rid of a throat irritant		x		x		
Excessive mucus discharge from the back of the nose or runny nose		x				x
Difficulty swallowing food, liquids, or pills	x					x
Cough after drinking, eating or in lying down		x			x	
Shortness of breath or cases of sudden asphyxia	x	x				
Importunate cough			x			x
Sensation of foreign body in throat	x		x			
Heartburn, chest pain, or an acid sensation in the throat or mouth	x	x				
Reflux Index (RI) before treatment Σ =	23					
RI after treatment Σ =	7					

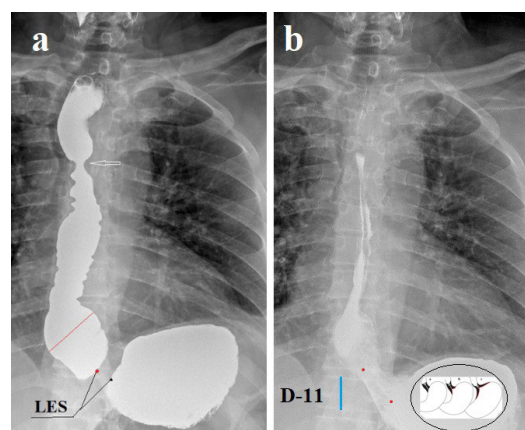


Figure 1 (Case 1) (a). High pressure in the stomach led to a reflex contraction of the UES and LES with tight filling of the esophagus. Assuming that the height of L-11 is approximately 2 cm, the length of the LES is 0.8 cm, which is significantly shorter than the minimum limit of normal (3.2 cm). This shortening indicates that the distal part of the LES has opened, and its walls are the walls of the stomach. The phrenic ampulla (red line) is sharply dilated (4.2 cm versus 1.5 cm in normal). The walls of the esophagus are uneven with asymmetric waviness. At level D-5, a symmetrical constriction 6 mm wide with smooth contours is determined (arrow). Between this narrowing and the lower point of the UES, a tight filling of the esophagus with smooth contours is determined. Barium lodged in the hypopharynx is visible at the very top of the x-ray indicates an inflammatory process. (b). After 5 minutes of rest, a spontaneous reflux of barium from the stomach into the esophagus is seen with a wide opening of the EGJ. The phrenic ampulla is smaller than in radiograph (a), but its distal contour is in the same place, on the lower contour of D-10 (upper red dot). The length of the open LES (between the two red dots) is 2.9 cm. Thus, the difference in length of the LES between (a) and (b) is due to the difference pressure in the stomach. At high pressure, the intra-abdominal portion of the LES opens. During reflux, the barium reached the level of D-5, where there was a narrowing in radiograph (a). Radiograph 1 b in the projection of the stomach shows a diagram of gradual shortening of the LES. From the norm to a sharp shortening of the LES, because of the opening of its distal part, which became the walls of the stomach.

Analysis. A sharp shortening of the LES, widening of the ampulla, asymmetrically uneven contours, and free reflux of barium from the stomach into the esophagus indicate GERD. Physiological narrowing at the D-5 level plays an important role in the clinical picture of the disease. It does not interfere with food intake, but during reflux, its contraction prevents acid from entering the mouth. Therefore, the patient never feels acid in the mouth. During sleep, this narrowing does not allow saliva to enter the distal esophagus. When a large volume of saliva accumulates between this narrowing and the UES, the esophagus between the narrowing and the UES contracts, and throws saliva into the pharynx, because of which the patient chokes on saliva and wakes up. This narrowing has symmetrical and smooth contours, which excludes stenosis. Its anatomy and physiology correspond to the sphincter that arises at the site of an anatomical narrowing of the esophagus, resulting from the retention of an acid bolus. We called this sphincter the “aorto-esophageal sphincter (AES). Barium lodged in the hypopharynx is visible on both radiographs. It indicates an inflammatory process, which is the cause of voice changes and a debilitating cough.

Diagnosis GERD, pharyngitis, contraction of the AES. To reduce the tone of the AES, the patient swallowed a dense tablet with a diameter of 1.9 cm in the X-ray room. Complex treatment of GERD prescribed and a consultation with an otolaryngologist recommended.

Results Starting from the next night, the patient did not wake up. The otolaryngologist confirmed the inflammatory process in the hypopharynx and prescribed pathogenic treatment. The treatment results are noted in Table 1. After a month, the index reflux (IR) decreased from 23 to 7.

Case 2:

A 67-year-old man presented with heartburn, pressing chest pain, and abdominal pain. A year before his presentation, he had undergone gastroscopy. Erosive esophagitis was diagnosed, but PPI treatment did not bring relief. Symptoms at presentation shown in Table 2 with black color. IR=7. Figure 2 shows the results of the X-ray examination.

Table 2 Gastroesophageal reflux disease screening questionnaire (Case 2)

How bothersome are you by the symptoms described below?						
There is no symptom - 0; a strong symptom - 5.						
	0	1	2	3	4	5
Hoarseness or alteration of voice	x					
Sore throat or desire to get rid of a throat irritant		x				
Excessive mucus discharge from the back of the nose or runny nose		x	x			
Difficulty swallowing food, liquids, or pills	x					
Cough after drinking, eating or in lying down	x					
Shortness of breath or cases of sudden asphyxia		x				
Importunate cough		x				
Sensation of foreign body in throat	x					
Heartburn, chest pain, or an acid sensation in the throat or mouth			x			
Reflux Index (RI) before treatment Σ =	7	Chronic sinusitis.				
RI after treatment Σ =	1					

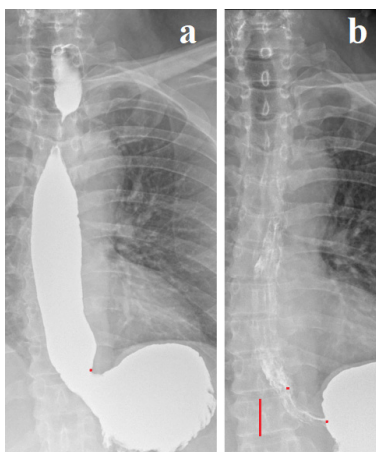


Figure 2 (Case 2) (a). During continuous drinking of barium, wide opening of the EGJ with angular deformation of the stomach occurred, as it occurs during the water-siphon test in GERD. The width of the esophagus at the level of the ampulla is 2.6 cm. At the level of the aortic arch in projection D-4, a contraction of the esophagus of 1.8 cm in length is determined. This is contracted AES. **(b).** After 5 minutes of rest, 5 to 7 longitudinal folds are determined in the esophagus,

indicating an inflammatory process. They end near the lower left corner of D-10 (upper red dot), which corresponds to the base of the ampulla in the figure (a). Between the two red dots, only two folds are visible in the contracted LES. Its length is 3.2 cm.

Analysis of radiographs The different number of folds in the esophagus (5-7) and in the LES (2) is due to the different tone and different width of these sections. This observation also confirms that the length of the esophagus does not change in different periods of functioning. The complex (esophagus + LES) shortened due to the shortening of the LES. The patient swallowed a dense tablet with a diameter of 2.5 cm. After 2 years, he reported that since he swallowed this tablet, abdominal pain, heartburn and bloating after eating had disappeared. Since then, he has not consulted a doctor. ID = 1 (red). **Diagnosis:** GERD, increased AES tone.

Case 3:

A 68-year-old woman first became ill at the age of 16-18 when heartburn periodically occurred. At the age of 25, severe coughing attacks with bronchospasm appeared. Throughout the year she received treatment against bronchial asthma. X-ray examination revealed GERD. The cough disappeared, but the patient for many decades first took H2-histamine blockers, and in the last 15 years - PPI. Currently a single 40 mg PPI relieves her of heartburn and chest pain. After a hearty holiday meal, it sometimes causes vomiting. In the vomit may be the remains of food eaten a day ago. She fights putrid breath. At 28, she noticed that after drinking milk, belching and heartburn appeared, but she continued to drink coffee with milk. For the past five years, she has not eaten food cooked with milk. If cow's milk accidentally enters the coffee instead of a substitute, severe heartburn and pain behind the breastbone occur after 15 -30 minutes. At the age of 58 years, an HRM of the esophagus was done with the following conclusion: Normal pressure in the LES with normal relaxation. Low pressure in the UES. Low pressure waves throughout the esophagus. Repeated endoscopy always reveals a medium-sized hiatal hernia. Table 3 shows the patient's complaints. IR = 5. **Figure 3** shows an X-ray examination using the method described above.

Table 3 Gastroesophageal reflux disease screening questionnaire. Case 3

How bothersome are you by the symptoms described below?						
There is no symptom - 0; a strong symptom - 5.						
	0	1	2	3	4	5
Hoarseness or alteration of voice	x					
Sore throat or desire to get rid of a throat irritant	x					
Excessive mucus discharge from the back of the nose or runny nose	x					
Difficulty swallowing food, liquids, or pills	x					
Cough after drinking, eating or in lying down	x					
Shortness of breath or cases of sudden asphyxia	x					
Importunate cough	x					
Sensation of foreign body in throat	x					
Heartburn, chest pain, or an acid sensation in the throat or mouth						x
Reflux Index (RI) before treatment Σ =	5	Milk causes heartburn after 15-30 minutes of consumption				
RI after treatment Σ =	5					

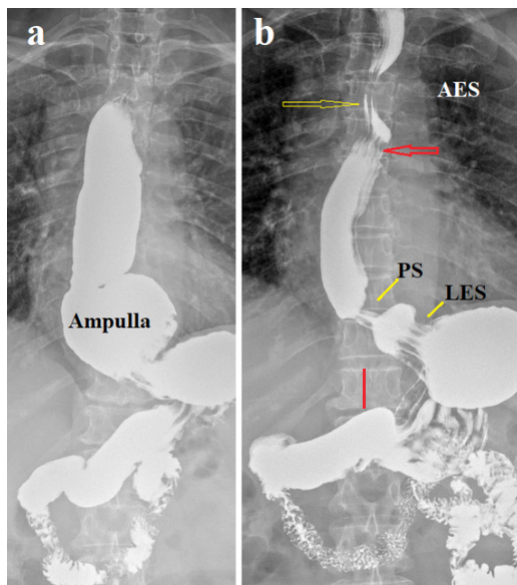


Figure 3 Case 3 (a). The wide esophagus (2.9 cm) distal to the contraction zone at the level of the aortic arch (D-4), the sharply dilated ampulla (5.6 cm) and the widely opened LES (1.1 cm) are filled with barium. **(b).** After 5 minutes of rest, spontaneous reflux occurred, and the esophagus was filled with barium again. In the contraction zone at the level of the aortic arch (yellow arrow) two folds are determined, while above and below (red arrow) multiple folds are determined. We see three zones of functional contraction of the esophagus. In the upper part of the esophagus at the level of the aortic arch, the AES is visible, between the body of the esophagus and the ampulla – the proximal sphincter (PS) 7 mm long and a sharply shortened gaping LES in the form of multiple folds at the level of the opening in the diaphragm 1 cm long.

Analysis A patient with lactose intolerance developed symptoms of GERD in adolescence. At age 25, severe coughing attacks with bronchospasm developed. Treatment with bronchodilators, which decrease smooth muscle tone, similarly decreased LES tone, worsening the pathophysiology of GERD.⁹ Chronic use of drugs that reduce hydrochloric acid secretion often allowed symptoms to be controlled despite disease progression. This is facilitated by decreased sensitivity due to damage by hydrochloric acid to sensitive elements in the esophageal wall. As a result, LES insufficiency to the degree of chaliasia of the cardia developed, with constant reflux of stomach contents into the esophagus. This typical observation contradicts modern ideas: (1) It is known that the genetic mechanism of lactase persistence in adult Caucasians mediated by a single C→T nucleotide polymorphism at the LCTbo -13'910 locus on chromosome-2.¹⁰ The question arises, why did the patient become convinced that milk (lactose) provoked heartburn only after age 60, when, on the advice of a doctor, she stopped drinking milk? This was facilitated by chaliasia of the cardia, because of which acid with a low pH penetrated the esophagus immediately after its appearance in the stomach, i.e., 15-30 minutes after milk intake. In the previous period, with a weak but functioning LES, heartburn appeared after a long period after taking lactose, so the patient was not associated the symptoms of GERD with taking dairy products. 15-30 minutes after drinking milk, lactose could not penetrate the colon. This is one of numerous confirmations of the fact that lactose leads to hypersecretion of hydrochloric acid, causing the release of mediators from mast cells of the small intestine that stimulate the release of hydrochloric acid.¹¹ This fact does not exclude the hypothesis that the hydrolysis lactose into glucose and galactose by microorganisms in the large intestine. However, the statement that lactose intolerance is the occurrence of symptoms such as abdominal pain, bloating or diarrhea after ingestion of lactose does

not have any evidence. I have never been encountered in my practice, and I have not seen a description of such cases in the literature. (2) A sharp expansion of the esophagus is a consequence of the failure of the LES. During contraction of the stomach, its contents are thrown into the esophagus, because of which the pressure in the esophagus becomes equal to the pressure of the stomach. The AES contraction does not allow the refluxant to penetrate the pharynx, despite the weak UES. (3) The HRM results stated “normal pressure in the lower esophageal sphincter with normal relaxation and low pressure in the upper esophageal sphincter” contradict objective radiographic data, which is explained in a scientific review.⁶ The hypertrophied PS was replaced by fibrous tissue over time. It expands together with the esophagus, but to a lesser extent. Without contents, the distended esophagus, as well as the LES, gather into folds, which are mistakenly considered folds of the stomach.^{4,6} The esophagus, including the ampulla, regardless of its size, does not shorten, and the LES does not shift into the chest.

Diagnosis: GERD with LES function insufficient in the degree of cardiac achalasia. Megaesophagus. Lactose intolerance. Contraction of pathological AES.

The patient swallowed a tablet about 2 cm in diameter, but she did not feel any effect. The combination of low IR (5) with severe GERD supports other evidence that chronic refluxant exposure results in decreased esophageal sensitivity.

Case 4:

Woman 63 years old considers herself sick from the age of 54 years when there was severe pain in the epigastrium. Antral gastritis caused by *Helicobacter pylori* was diagnosed with gastroscopy. After a course of eradication, all symptoms disappeared, and the patient considered herself healthy for 3 years. At the age of 57, when epigastric pain reappeared, a small hiatal hernia with red stripes leading to cardiac was shown during gastroscopy. At the age of 61, every morning, she was worried about a painful cough and a sore throat. Several times at night, she woke up with attacks of suffocation and with a feeling of strong acid in her mouth. At the same time, pain in the epigastrium and in the left hypochondrium often bothered her. 3-4 months after the onset of symptoms, she turned to the otolaryngologist, who discovered laryngopharyngeal inflammation, which served as the basis for the diagnosis of gastroesophageal-pharyngeal reflux. She began to take 20 mg of Esomeprasol per day, however, there was no significant effect. Gastroscopy was performed twice with an interval of 2 months. The endoscopic diagnosis was antral gastritis with the histologic conclusion: oxyntic mucosa showing mild chronic gastritis and focus erosion. pH monitoring did not confirm the diagnosis of GERD since the DeMeester score was 3.2. The X-ray examination was performed twice (Figure 4). In the first image, attention was focused only on the EGJ (a). In the process of practicing the technique, we began to include the entire esophagus in the X-ray (b).

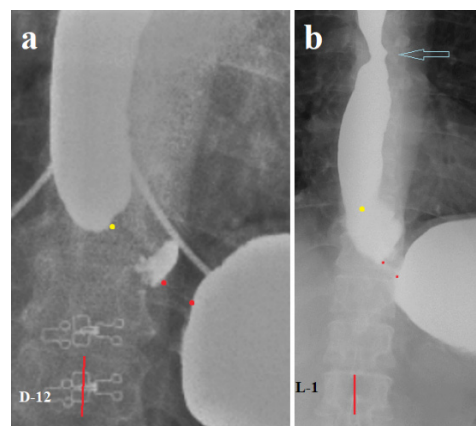


Figure 4 Case 4 (a). The contracted LES is defined between the stomach and the barium residues in the contracted phrenic ampulla (between the two red dots). Its true length is 1.1 cm, which is significantly shorter than the minimum normal limit (3.2 cm). The width of the esophagus is 2.4 cm, which is significantly wider than the normal limit (1.5 cm). Such a false diverticulum in the contracted ampulla is always located on the left and is an additional sign of GERD. **(b).** The true length of the LES is 1.2 cm, and the width of the esophagus is 2.0 cm. The blue arrow shows an asymmetric narrowing at the level of D-5 above the aortic arch.

Diagnosis: GERD, hypertonia of the AES? Suspected erosion.

Endoscopic examination did not reveal any pathology in the esophagus.

After the patient swallowed a tablet of about 2 cm in diameter, all symptoms disappeared, but after 6 months, heartburn and pain in the hypochondrium reappeared. The patient swallowed the tablet two more times. The positive effect lasted for up to 4 months. Currently, when she began to go to bed with an empty stomach (last meal at 4 p.m.), she is free of symptoms, even though she stopped taking PPI.

Analysis. X-ray examination revealed a sharp shortening of the LES, expansion of the esophagus with the formation of an ampulla, which does not raise doubts in the diagnosis of GERD. Laryngopharyngeal inflammation confirmed this diagnosis. Endoscopic examination diagnosed chronic gastritis with erosion, which is evidence of hypersecretion of hydrochloric acid. However, no changes were detected in the esophagus and no histological studies were performed. This confirms the data known from the literature that endoscopy reveals only complications of GERD in the esophagus: erosions, stenosis, Barrett's esophagus and tumors. As shown in this observation, monitoring the pH of the esophagus cannot serve as a diagnostic method, since it is based on the false idea of the possibility of physiological reflux in healthy individuals.⁶ This observation also shows that non-esophageal symptoms (a painful cough, a sore throat attacks of suffocation and with a feeling of strong acid in her mouth) were caused by the AES and were relieved by stretching this sphincter with a swallowed large tablet.

Case 5:

A 46-year-old man complained of inability to eat solid food, vomiting, heartburn, and belching. Half of the 26 reflux index points noted by the patient in Table 4 (Figure 5) are non-esophageal symptoms. He considers himself ill for about 10 years. But all this time, back pain from an injury was predominant. Therefore, he began to be examined only in the last year. An ultrasound examination revealed a gallstone. A gastroscopy revealed a small hiatal hernia with a diameter of 2 cm. X-ray examination was performed twice: (a) – before treatment, and (b) – after 4 months against the background of conservative treatment. The patient was unable to swallow the tablet. Complex treatment of GERD included fractional meals, horizontal position only with an empty stomach, taking PPI and esophageal mucosa protectors, as well as refusal to take products containing lactose. During the treatment, he several times drank his favorite milk drink and each time he had heartburn and vomiting. This proved that he had lactose intolerance, which the patient had not suspected before. **Figure 5** shows the X-ray examination, and Table 4 shows the treatment results.

Table 4 Gastroesophageal reflux disease screening questionnaire (Case 5)

How bothersome are you by the symptoms described below?						
There is no symptom - 0; a strong symptom - 5.						
	0	1	2	3	4	5
Hoarseness or alteration of voice	x x					
Sore throat or desire to get rid of a throat irritant	x			x		
Excessive mucus discharge from the back of the nose or runny nose		x		x		
Difficulty swallowing food, liquids, or pills			x		x	
Cough after drinking, eating or in lying down		x		x		
Shortness of breath or cases of sudden asphyxia		x				
Importunate cough				x x		
Sensation of foreign body in throat				x	x	
Heartburn, chest pain, or an acid sensation in the throat or mouth				x		x
Reflux Index (RI) before treatment Σ =	26	Vomiting after drinking milk				
RI after treatment Σ =	14					

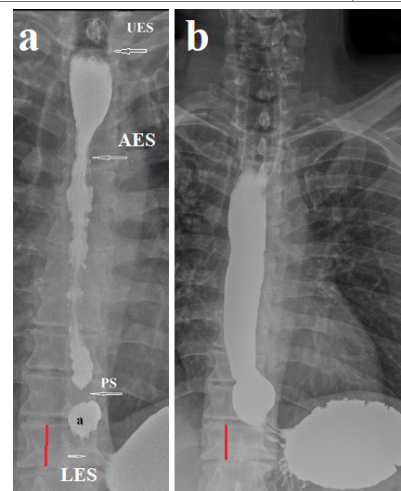


Figure 5 (Case 5) (a). Barium filled the entire esophagus from the UES to the LES. The lumen of the esophagus is unevenly narrow, indicating a high tone. The contours are uneven. The length of the LES is 1.2 cm, which is significantly less than the minimum normal limit (3.2 cm). Mucosal folds indicate an inflammatory process. The width of the ampulla (a) is 1.7 cm. The length of the PS is 0.7 cm. Above the level of the aortic arch (D-5) and up to the UES, the esophagus is dilated with smooth contours, which may indicate a contraction of the AES at rest. **(b).** After 4 months, the tone of the esophagus decreased, its width is 2 cm, the contours are smooth, the width of the ampulla is 2.3 cm, the length of the LES is 1.2 cm. RI decreased from 24 to 14 mainly due to nonesophageal symptoms.

Analysis. As shown in the study, Chandrasoma in a normal state, the gastrointestinal epithelium passes into the GEJ into the squamous epithelium of the esophagus. Cardiac epithelium appears because of metaplasia of esophageal squamous epithelium under the influence of hydrochloric acid. At first the process of metaplasia captures the intra-abdominal segment of the LES. In the absence of treatment, the cardiac epithelium displaces the squamous epithelium along the entire length of the LES and then moves into the esophagus.⁴ The erroneous idea that the cardiac epithelium is the normal epithelium of the stomach was one of the proofs of displacement of the stomach into the chest, i.e. hiatal hernia. Figure 5 confirms the histological studies of Chandrasoma that the folds of the mucosa both in the esophagus and in the LES are caused by the inflammatory process and differ in shape because the intraluminal pressure in the esophagus is much less than inside the LES. Radiographic data are in complete agreement with histological data: GERD is characterized by shortening of the LES, not the esophagus, regardless of swallowing. Cranial displacement of the cardiac epithelium and mucosal folds above the stomach have no relation to the stomach. Dilation of the esophagus above the LES, called the ampulla, is caused by GERD, and the ampulla does not become a hernia if it is more than 2 cm wide. The discovery by Chandrasoma of the transition of gastric oxyntic epithelium to esophageal squamous epithelium is convincing evidence of the correctness of this theory. Although none of the histologists disputed the fact of such a phenomenon, this theory, which contradicts outdated views, is not even considered as a hypothesis in the literature. This can only be explained by the fact that by accepting this theory, it will be necessary to revise all modern gastroenterology. For example, then the DeMeester score more than 4 will not be an indicator of the norm, and the results of HRM will have no meaning. And the LES supposedly displaced into the chest cavity will turn out to be the proximal sphincter, which closes the ampulla during the evacuation of the bolus into the stomach.

Both radiographs (a, b) indicate increased esophageal tone at the level of the aortic arch, which was responsible for most of the non-esophageal symptoms of GERD. Combined treatment of GERD reduced the inflammatory process in the esophagus, which was accompanied by a decrease in tone, including AES, and a decrease in nonesophageal symptoms.

Cases 6-7:

We combined these cases because we could not obtain objective treatment results.

Case 6. A 53-year-old man complained of pain in the epigastric region. In the morning, he drinks coffee with milk. Abdominal pain appears 30 minutes after breakfast. The family has dinner at 8-9 pm. After that, he feels heaviness in the abdomen. A high-pressure study in the stomach (Figure 6 a) reveals a 3-cm wide esophageal ampulla and a contraction of the esophagus at the level of the aortic arch (AES). Between the ampulla and the AES, two wide, uneven folds are determined in the contracted esophagus. In his conclusion about GERD, he was recommended to give up dairy products and go to bed with an empty stomach, as well as a course of PPI. The patient reported that after giving up milk, he feels healthy. He completed the questionnaire only before starting treatment (Table 5).

Table 5 Gastroesophageal reflux disease screening questionnaire

How bothersome are you by the symptoms described below?						
There is no symptom - 0; a strong symptom - 5.						
	0	1	2	3	4	5
Hoarseness or alteration of voice						x

Sore throat or desire to get rid of a throat irritant					x	
Excessive mucus discharge from the back of the nose or runny nose						x
Difficulty swallowing food, liquids, or pills	x					
Cough after drinking, eating or in lying down			x			
Shortness of breath or cases of sudden asphyxia			x			
Importunate cough					x	
Sensation of foreign body in throat			x			
Heartburn, chest pain, or an acid sensation in the throat or mouth					x	
Reflux Index (RI) before treatment Σ =	28	Feeling unwell after eating dairy products. Vomiting after a late dinner.				
RI after treatment Σ =						

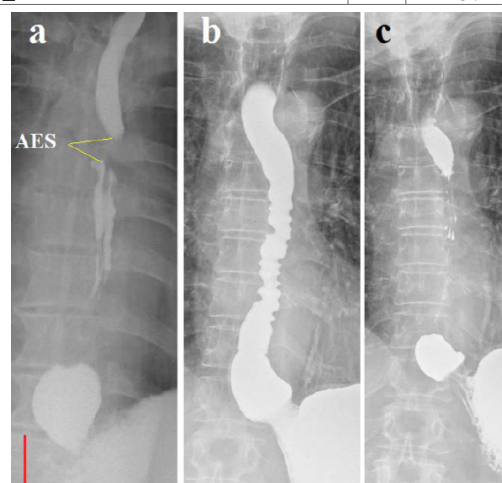


Figure 6 Case 6 (a). Radiograph recorded the moment of contraction of the PS, resulting in the contracting ampulla could create a pressure for opening the LES, which was higher than the pressure in the stomach. This allows the ampulla to inject a bolus into the stomach. The true length of contraction of the AES at the level of D5-6 is 0.7 cm.

Case 7 (b-c). (b). With tight filling of the esophagus, pressure on its left wall and its displacement to the right caused by the aortic arch are visible (c). After emptying, at low pressure in the esophagus, a delay of the contrast medium is observed above the contraction zone (D-5).

Discussion

These 7 observations were selected from 86 radiographic studies performed using the technique we developed. The basis for inclusion in this list was an obvious narrowing of the esophagus at the level of the aortic arch. Having reviewed all the studies repeatedly, I did not find a single study where the functional narrowing (not stenosis) was located elsewhere, except for the anatomical UES and LES, as well as the functional PS. Thus, this is not a coincidence, but a pattern. This narrowing has the following characteristics: (a). It is always detected in GERD, mainly in people over 50 years old, many years after the onset of the disease. (b). As a rule, it is combined with widespread esophagitis. (c). It is usually accompanied by non-esophageal symptoms. (d). It has the characteristics of a sphincter: it does not interfere with the movement of the food bolus, prevents retrograde movement of chyme, and retains saliva, which can accumulate between this contraction and the UES.

These observations suggest that the functional narrowing at the level of the aortic arch, which we call the aortic esophageal sphincter (AES), results from the retention of some refluxant in anatomical narrowing of the esophagus. It causes local irritation and inflammation, which leads to an increase in tone. The frequent association of AES with non-esophageal symptoms of GERD is probably due to inflammation of the upper esophagus, weakness of the UES,^{12,13} and the possibility of laryngopharyngeal reflux.

Four of the seven patients had lactose intolerance, which they learned about after the age of 50, that is, many years after the onset of GERD. Milk in very small quantities (coffee with milk) provoked typical GERD symptoms (heartburn and/or abdominal pain). With a functioning LES, heartburn may appear several hours after drinking milk, so patients do not associate drinking milk with the onset of symptoms. With cardiac chaliasia, heartburn appears immediately after the appearance of acid in the stomach, i.e. after 15-30 minutes, which indicates hypersecretion of hydrochloric acid, which occurs due to the release of mediators from mast cells of the small intestine. Histamine causes the release of hydrochloric acid in the gastric mucosa. First, lactose could not penetrate the large intestine during this time. Secondly, the breakdown of lactose into glucose and galactose by intestinal flora cannot cause heartburn. Knowledge of lactose intolerance is of great importance, since no treatment can be effective unless the intake of the provocateur of hypersecretion of hydrochloric acid in the diet is stopped. The assertion that in case of lactose intolerance the amount of milk should be reduced to a level at which it does not cause symptoms is erroneous, because a small amount of milk causes hypersecretion of hydrochloric acid. In addition, the patient often cannot determine the reason for the lack of effect from the use of PPIs. Finally, it is known that refractory GERD is very common and may affect up to 40% of patients who use a PPI once daily.¹² Therefore, the lack of response to PPI treatment does not exclude GERD.

de Bortoli et al.,¹³ using MII-pH analysis, confirmed the diagnosis of GERD in less than 40% of patients with a previous diagnosis of laryngopharyngeal reflux. They suggested that “most likely due to the low specificity of laryngoscopic findings”.¹³ These authors ignored the absolutely reliable fact that all patients had laryngopharyngeal inflammation and no other causes except GERD were suggested. At the same time, in 60% of patients with laryngopharyngeal reflux, the authors excluded GERD based on the pH of the study, since the total acid exposure time, defined as the percentage of time when the esophageal pH was below 4, was considered pathological if it was more than 6% of the total recording time. Does this mean that gastric contents containing hydrochloric acid and pepsin, which destroy protein foods, can remain in the esophagus for about 1.15 hours per day without damaging the esophageal wall? And if the pH of the contents is greater than 4, which does not prevent protein degradation, can such reflux be safe, i.e. physiological? Unlike the mucous membrane of the stomach and the bulb of the duodenum, which are protected from damage by acid and pepsin, the esophagus has no protection. How did it happen that the idea of the possibility of physiological reflux, which is contrary to common sense, became the “generally accepted” hypothesis?

In 1976, DeMeester et al.¹⁴ published an article proposing a normal range for esophageal pH monitoring. It was defined as pH < 4 for 4% of the 24 hours of monitoring 5 cm proximal to the LES. The authors examined 15 individuals who believed that they had no problems with the digestive system.¹⁴ The very idea of diagnosing reflux by examining pH in the esophagus suggested the possibility of physiological reflux, which contradicted scientific data. The authors selected 15 people without typical complaints as a control, even though it was known that reflux esophagitis occurs in asymptomatic patients. The authors had the opportunity to exclude reflux using objective research methods (endoscopy with histology, radiographic examination, and EGJ manometry), which these authors used when

examining patients.¹⁵ As a result of violating the basic principle of scientific methodology, unreliable selection of individuals as controls, they came to a false conclusion about the possibility of so-called physiological reflux. Sometime later, DeMeester co-authored numerous histological studies of Chandrasoma. In them it was shown that because of the action of hydrochloric acid, metaplasia of the esophageal epithelium into the cardiac occurs. At the beginning of this process, reflux affects only the intraabdominal part of the LES, when the acid has not yet entered the esophagus. Thus, DeMeester's co-authorship with histologists has crossed out his work on the introduction of pH monitoring in the esophagus, since histological studies exclude the possibility of physiological reflux. Numerous studies have proven that pH monitoring does not diagnose GERD in at least 30% of patients.¹⁶⁻¹⁸ Our observation (case 4) confirms that pH monitoring diagnoses only severe forms of GERD.

Authors promoting pH monitoring periodically have to resort to explanations that contradict common sense. For example, 21 authors from different cities and countries claim that “later studies have demonstrated grade A oesophagitis in 5%–7.5% of healthy subjects. In contrast, LA grades B, C and D oesophagitis are highly uncommon in healthy subjects”.¹⁹ Firstly, how can 21 researchers write an article while being in different cities and countries? They can get together and approve by majority vote any statements that cannot be considered scientific, because no science uses voting to determine the truth. Secondly, esophagitis, from a scientific point of view, is an inflammation of the esophagus. Therefore, people with esophagitis cannot be considered healthy.

This false statement is based on pH-monitoring, which, as shown above, has low diagnostic reliability. Accurate diagnosis of GERD is possible using histological examination based on the detection of pathological changes in the mucosa compared to the norm.^{4,20,21} But these simple, cheap and accurate methods will destroy the successful businesses of the equipment manufacturers. In addition, it will be necessary to revise all theoretical hypotheses and recommendations based on the false assertion that pH-metry is the gold standard for GERD diagnostics, which were imposed by voting. For example, as shown in some studies, all so-called functional disorders, in which GERD was excluded, since the Demeester score was less than 4, have organic damage to the mucosa. To explain this phenomenon, advocates of pH-monitoring came up with a new direction in science - visceral hypersensitivity and “gut-brain interaction”.^{22,23} We are talking about patients with GERD who do not receive pathogenetic treatment due to factitious diagnoses: hypersensitive esophagus, functional heartburn, functional non-cardiac chest pain, functional dyspepsia, irritable bowel syndrome, chronic constipation with megaecolon.²⁴

Conclusion

In healthy individuals, two anatomical sphincters (UES and LES) ensure normal functioning of the esophagus. LES prevents reflux of aggressive gastric contents into the esophagus. The crural diaphragm contracts briefly during deep inspiration and increased gastric pressure, which enhances the antireflux function of the LES. The LES does not move into the chest. In patients with GERD the LES is shortened. The esophagus expands, and its peristalsis weakens. For the last peristaltic wave to be able to create a pressure in the dilated esophagus that can open the LES and is greater in magnitude than the pressure in the stomach, an injection chamber (phrenic ampulla) arises above the LES. The contraction of the peristaltic wave above the ampulla allows creating a pressure above the LES that is necessary for the contracting ampulla to inject a bolus into the stomach. This is how a functional proximal sphincter (PS) of 0.5-0.7 cm in length arises above ampulla. The article describes for the first time a functional sphincter at the level of the aortic arch, which occurs in patients with GERD over the age of 50. This aorto-esophageal sphincter (AES) plays a role in the occurrence of non-esophageal symptoms.

References

1. Shafik A, El-Sibai O, Shafik AA, et al. Effect of straining on the lower esophageal sphincter: identification of the “straining–esophageal reflex” and its role in gastroesophageal competence mechanism. *J Invest Surg.* 2004;17(4):191–196.
2. Levin MD, Korshun Z, Mendelson G. [Pathological physiology of gastroesophageal reflux disease. Hypothesis (Literature review)]. *Eksp Klin Gastroenterol.* 2013;(5):72–88.
3. Levin MD. Reaction to articles on high resolution manometry, the length of the lower esophageal sphincter and the diagnosis of gastroesophageal reflux disease. *Arq Gastroenterol.* 2019;56(2):209–210.
4. Chandrasoma P, DeMeester T. A new pathologic assessment of gastroesophageal reflux disease: the squamo–oxyntic gap. *Adv Exp Med Biol.* 2016;908:41–78.
5. Levin MD, Mendel’son G. [Schatzki ring as a symptom of gastroesophageal reflux disease]. *Vestn Rentgenol Radiol.* 2015;(1):5–15.
6. Levin MD. Gastrointestinal motility and law of the intestine. Preprint. Posted December 26, 2023.
7. Kwiatek MA, Nicodème F, Pandolfino JE, et al. Pressure morphology of the relaxed lower esophageal sphincter: the formation and collapse of the phrenic ampulla. *Am J Physiol Gastrointest Liver Physiol.* 2012;302(3):G389–G396.
8. Masuda T, Kovacs B, Csucska M, et al. Pathological implications of swallow–associated transient lower esophageal sphincter elevation. *J Gastrointest Surg.* 2020;24(12):2705–2713.
9. Cazzola M, Rogliani P, Calzetta L, et al. Bronchodilators in subjects with asthma–related comorbidities. *Respir Med.* 2019;151:43–48.
10. Misselwitz B, Butter M, Verbeke K, et al. Update on lactose malabsorption and intolerance: pathogenesis, diagnosis, and clinical management. *Gut.* 2019;68(11):2080–2091.
11. Aguilera–Lizarraga J, Florens MV, Viola MF, et al. Local immune response to food antigens drives meal–induced abdominal pain. *Nature.* 2021;590(7844):151–156.
12. Fass R, Gasiorowska A. Refractory GERD: what is it? *Curr Gastroenterol Rep.* 2008;10(3):252–257.
13. de Bortoli N, Nacci A, Savarino E, et al. How many cases of laryngopharyngeal reflux suspected by laryngoscopy are gastroesophageal reflux disease–related? *World J Gastroenterol.* 2012;18(32):4363–4370.
14. Demeester TR, Johnson LF, Joseph GJ, et al. Patterns of gastroesophageal reflux in health and disease. *Ann Surg.* 1976;184(4):459–470.
15. Demeester TR, Johnson LF, Kent AH. Evaluation of current operations for the prevention of gastroesophageal reflux. *Ann Surg.* 1974;180(4):511–525.
16. Tseng D, Rizvi AZ, Fennerty MB, et al. Forty–eight–hour pH monitoring increase sensitivity in detecting abnormal esophageal acid exposure. *J Gastrointest Surg.* 2005;9(8):1043–1052.
17. Yoo SS, Lee WH, Ha J, et al. The prevalence of esophageal disorders in the subjects examined for health screening. *Korean J Gastroenterol.* 2007;50(5):306–312.
18. Stål P, Lindberg G, Ost A, et al. Gastroesophageal reflux in healthy subjects: significance of endoscopic findings, histology, age, and sex. *Scand J Gastroenterol.* 1999;34(2):121–128.
19. Gyawali CP, Yadlapati R, Fass R, et al. Updates to the modern diagnosis of GERD: Lyon consensus 2.0. *Gut.* 2024;73(2):361–371.
20. Tobey NA, Carson JL, Alkief RA, et al. Dilated intercellular spaces: a morphological feature of acid reflux–damaged human esophageal epithelium. *Gastroenterology.* 1996;111(5):1200–1205.
21. Johannessen R, Skogaker N, Halgunset J, et al. A standardized method for measuring intercellular spaces in esophageal biopsies in patients with suspected gastroesophageal reflux disease (the intercellular space ratio). *Scand J Gastroenterol.* 2013;48(11):1235–1241.
22. Remes–Troche JM. The hypersensitive esophagus: pathophysiology, evaluation, and treatment options. *Curr Gastroenterol Rep.* 2010;12(5):417–426.
23. Drossman DA, Hasler WL. Rome IV–Functional GI Disorders: Disorders of gut–brain interaction. *Gastroenterology.* 2016;150(6):1257–1261.
24. Levin MD. Hydrochloric acid hypersecretion is the cause of pathology of the upper digestive tract. Literature analysis. Preprint. Published January 8, 2025.