

Radiological Anatomy of the Colon and Rectum in Children

Levin M^{1,2*}¹Department of Pediatric Radiology of 1st city Hospital, Minsk, Belarus²State Geriatric Center, Netanya, Israel

Article Information

Received date: Feb 01, 2019

Accepted date: Mar 01, 2019

Published date: Mar 06, 2019

*Corresponding author

Levin M, Department of Pediatric Radiology of 1st city Hospital, Minsk, Belarus, Israel, Tel: 972-53-8281393; Fax: 972-9-8630151;

Email(s): nivel70@hotmail.com (or) michael.levin@dorot.health.gov.il

Distributed under Creative Commons CC-BY 4.0

Keywords Anal canal length; Colon volume; Hydrostatic enema; Rectal width; X-ray anatomy

Abstract

Objective: To determine the width of the rectum and different parts of the colon, as well as the length of the anal canal in children of different ages without chronic constipation for the precise diagnosis of megarectum, megacolon and the pathology of the puborectalis muscle.

Material and method: We analyze the results of X-ray investigation of the colon in 65 children of different ages, without the pathology of the colon and anorectum. The barium enema was conducted to determine the cause of the acute and chronic abdominal pain, anemia and for tumor localization. The barium was injected under the same hydrostatic pressure up to the reflux into the ileum.

Results: The true width of the rectum, the different parts of the colon and anal canal length in different age groups were determined. Method for analysis of X-ray data was proposed. Examples of diagnostics for various diseases are given.

Conclusion: Hydrostatic barium enema and the proposed method for estimating the magnitude of the rectum, colon and anal canal length, as well as the state of the puborectalis muscle are the precise diagnostic methods can be used for diagnosis and scientific analysis of the functional constipation, anorectal malformation, and other diseases of this area.

Introduction

In the 21st century, X-ray study of the colon has been used much less frequently than before, while other methods (manometry, ultrasound, scintigraphy, study with radiopaque markers, defecography, CT and MRI) began to play important role in the diagnostic process. However, contrast enema is a main method in the determination of the rectal and colon dimensions in Hirschsprung's disease, anorectal anomalies and functional constipation [1]. In most cases assessment of the colon is empirical, because it is impossible to determine precisely about the expansion of any parts of the colon without knowing of their normal limits. The methods previously proposed has not found practical application, as the normal and pathological indicators overlap [2,3]. The maximum norm of the rectal width for adults [4-6] cannot be used to diagnose a megarectum in childhood.

Material and Methods

In the years 1980-1983 in the Belarusian center of pediatric surgery 589 X-Ray studies of the colon were produced. This was the period when the barium enema has been the standard method for the diagnosis of acute (acute appendicitis) and chronic abdominal pain, anemia, and for localization of the abdominal space-occupying lesions. 65 studies without pathology of the colon and anorectal area were retrospectively selected. The results of the survey in this group of patients were accepted as the norm.

The study was conducted by the hydrostatic barium enema [7,8]. Only in infants up to 3 months the bowel filling was made from a rubber bulb. In other cases, barium was introduced from the graduated bag. The bottom of this bag at the beginning of the study was located 40 cm above the deck of the table. Barium was introduced into the colon up to the reflux into the terminal ileum. The difference of barium volume in the bag before and after the colon filling corresponds to the colon volume. The radiopaque marker is strung on the tip of the enema. It is in contact with the anus during the study. At least two radiographs (frontal and lateral) have been made after the filling of the colon. On a frontal radiograph the widths of the different parts of the colon are measured (Figure 1).

Since the rectum forms two bends in two projections, it cannot be differentiated on the frontal radiograph, which makes it impossible to measure its width. On a lateral radiograph were measured the maximum width of the vertical portion of the rectum, as well as interval not containing contrast medium between the rectum and a contrast marker on the posterior contour of the tip (Figure 2).

Figure 2 Lateral x-ray image of the anorectal zone of a child of 13 years and its schematic representation. The axis of the anal canal (AC) is displaced anteriorly from the axis of the vertical branch of the rectum (OK). Its true diameter is 1.6 cm. The distance between the rectum and the

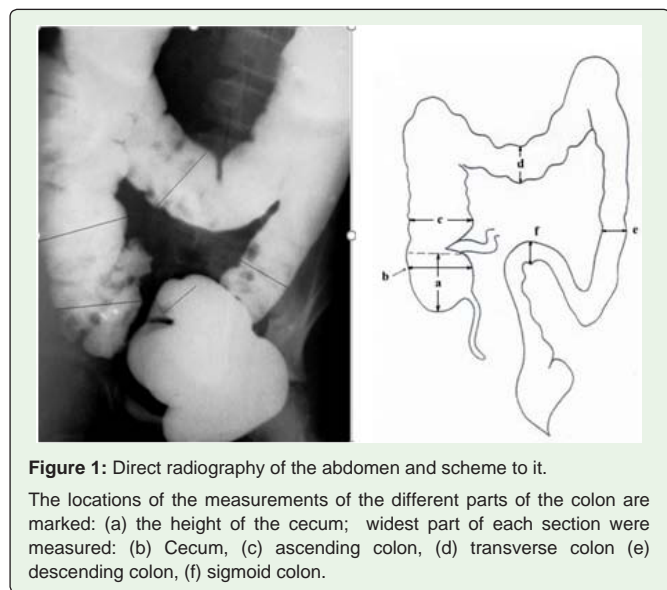


Figure 1: Direct radiography of the abdomen and scheme to it. The locations of the measurements of the different parts of the colon are marked: (a) the height of the cecum; widest part of each section were measured: (b) Cecum, (c) ascending colon, (d) transverse colon (e) descending colon, (f) sigmoid colon.

marker lying along the posterior contour of the tip is the length of the closed anal canal. The black line is the place of measurement of the width of the rectum.

Method of the analysis of the radiographs

The distance between the marker (anus) and the rectum, which does not contain a contrast agent is equal to the anal canal length measured by the manometric method. This is a zone of the anal canal

Table 1: The table shows the results of measuring the width of the rectum, all parts of the colon, as well as the length of the anal canal, the height of the dome of the cecum and the volume of the colon in milliliters of barium injected.

Age	Statistical indicators	Anal canal length	Widths of different parts of the intestine (cm)						Height of the cecum dome	volume of the colon (ml)
			Rectum	sigmoid colon	descending colon	transverse colon	ascending colon	cecum		
1-11 months	n	7	12	12	11	10	10	10	9	9
	fluctuations	1.7 - 2.5	1.3 - 3.0	1.4 - 2.0	1.7 - 2.4	2.3 - 2.7	2.4 - 3.4	2.4 - 3.0	1.4 - 2.7	350-800
	mean (M±m)	2.2±0.15	2.24±0.09	1.73±0.06	2.05±0.06	2.51±0.07	2.71±0.13	2.62±0.10	2.13±0.12	562±38
3-Jan years	n	7	9	9	8	7	6	6	6	6
	fluctuations	2.3 - 2.8	3.0 - 3.7	1.8 - 2.4	2.3 - 2.5	2.4 - 3.8	2.5 - 3.6	2.5 - 3.6	2.4 - 3.5	600 - 800
	mean (M±m)	2.55±0.10	3.21±0.11	2.11±0.08	2.54±0.08	3.02±0.23	3.09±0.27	3.26±0.21	2.95±0.13	675±12
4 - 7 years	n	9	9	8	9	8	7	6	7	8
	fluctuations	2.5 - 3.6	3.0 - 3.9	2.4 - 2.6	2.6 - 2.9	2.9 - 4.2	3.2 - 5.4	3.2 - 4.6	3.5 - 4.2	650 - 1100
	mean (M±m)	3.17±0.14	3.43±0.14	2.52±0.03	2.76±0.07	3.75±0.15	4.24±0.35	3.95±0.26	3.72±0.10	910±16
8 - 10 years	n	18	19	19	19	18	18	15	13	17
	fluctuations	2.6 - 3.7	3.2 - 4.1	2.1 - 2.6	2.5 - 3.2	3.0 - 4.3	3.6 - 5.7	3.6 - 5.4	3.5 - 4.9	750 - 1200
	mean (M±m)	3.11±0.10	3.72±0.05	2.41±0.03	2.81±0.06	3.56±0.09	4.62±0.17	4.35±0.16	4.02±0.24	1000±21
11 -15 years	n	13	15	13	15	14	11	13	11	15
	fluctuations	3.1 - 3.9	3.6 - 4.6	2.2 - 2.6	2.5 - 3.2	3.6 - 4.4	3.9 - 6.4	3.9 - 6.0	3.8 - 5.2	900 - 1200
	mean (M±m)	3.43±0.10	3.95±0.07	2.36±0.03	2.82±0.05	3.89±0.15	5.28±0.32	5.10±0.21	4.46±0.19	1050±32

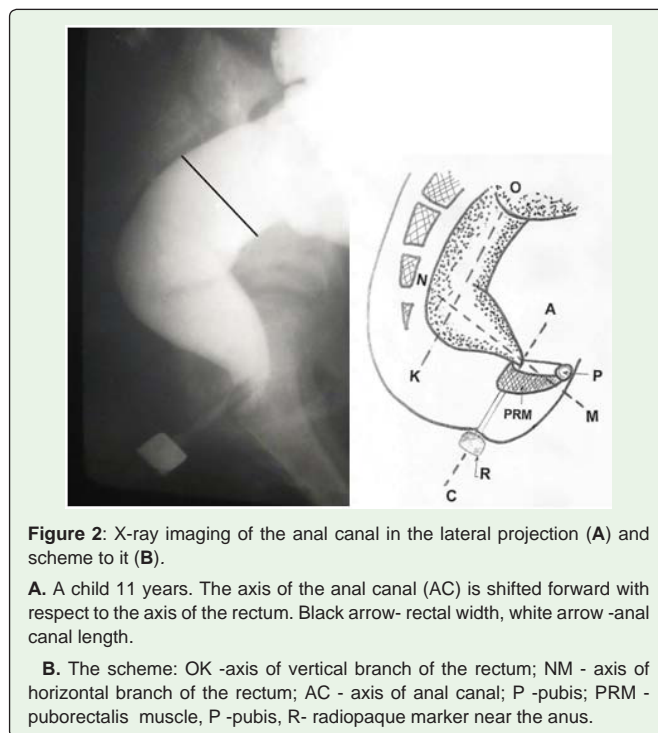


Figure 2: X-ray imaging of the anal canal in the lateral projection (A) and scheme to it (B).

A. A child 11 years. The axis of the anal canal (AC) is shifted forward with respect to the axis of the rectum. Black arrow- rectal width, white arrow -anal canal length.

B. The scheme: OK -axis of vertical branch of the rectum; NM - axis of horizontal branch of the rectum; AC - axis of anal canal; P -pubis; PRM - puborectalis muscle, P -pubis, R- radiopaque marker near the anus.

contraction (Table 1).

The true values were obtained by multiplying of the size measured on radiographs, on a factor of projection magnification (k). In order

to compare the different studies as well as studies of the same patient at different ages, we calculate the constant (C), which is the integral characteristic of the colon value.

It is calculated using the following formula:

$$C = \frac{V \times R \times \kappa}{h}$$

Where: C-constant, V- colon volume (ml); R- rectal width (cm); K-projection distortion factor, which is the ratio of the true width of the marker to its image on the radiograph;

h- Patient height (cm).

Results

In newborns with a high intestinal obstruction the colon width was the same on all extent. The true width is equal to 0.7 cm. In infants with normal digestive tract the width of the colon ranged from 1 to 1.5 cm with no significant differences between its parts. Uneven expansion of all parts of the colon occurs with the growth of the child. However, the ratio between them is always the same. Sigmoid colon is always the narrower part. The descending colon is somewhat broader of the sigmoid colon. The cecum and ascending colon is the widest sections. The rectum and transverse colon width take an intermediate position (Figure 3).

In children older than 3 years, the loop of the sigmoid colon is always located in the pelvis. The dome of the cecum in infants has a symmetric semi-oval shape. In older age groups, sometimes a deformation of the dome appears. In infants, the appendix was filled with barium in 89% of cases, but in other age groups, only in 39% of cases. Haustration of the colon from 4 years appears, at first in the right half of the colon, and then in the left. In babies, the rectum looks rectilinear. Its axis practically coincides with the axis of the anal canal (Figure 4A). With age, the bending of the rectum forward at the level of S-5 is formed (Figures 2 and 4B). In lateral projection the rectum is actually represented by two parts: vertical and horizontal.

Figure 4 Lateral radiographs of the anorectal zone. Radiological representation of the rectoanal inhibitory reflex.

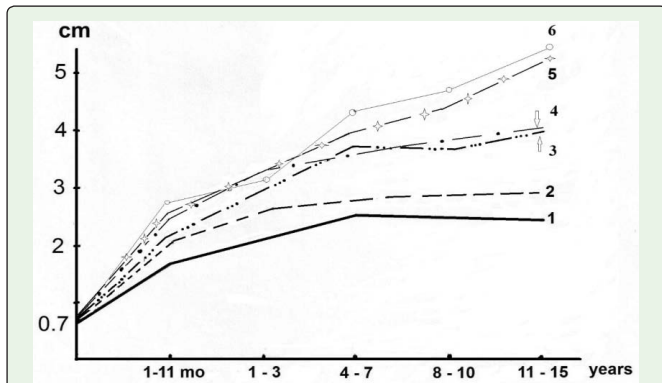


Figure 3: Scheme of expansion of the different parts of the colon and rectum in different age groups: 1-sigmoid colon; 2-descending colon; 3- rectum; 4-transverse colon; 5-cecum; 6-ascending colon.

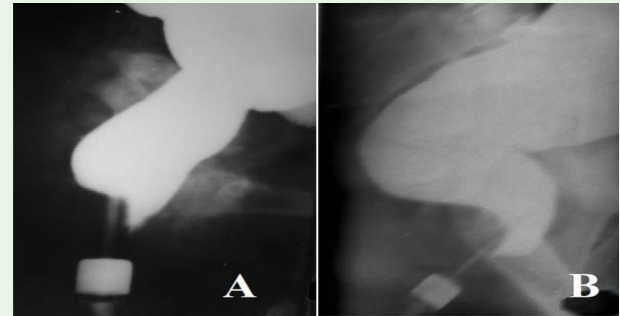


Figure 4: The lateral radiograph of the 4 months baby. The anal canal is a direct continuation of the rectum. The penetration of contrast agent into the top of the anal canal in front of the enema tip determined while the posterior wall is pressed tightly to the tip.

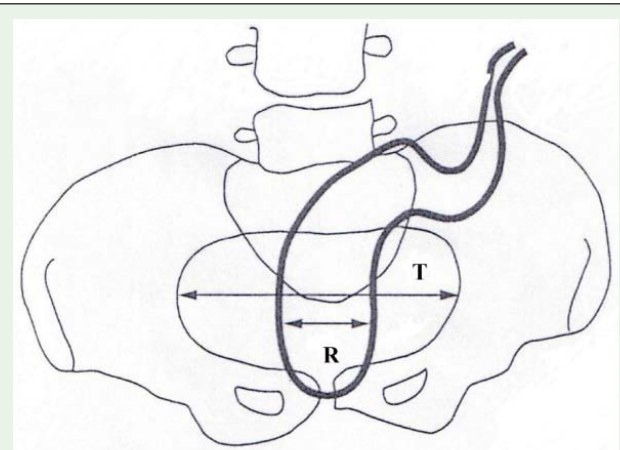


Figure 5: Determination of the RPR. The maximal pelvis diameter (linea transversa -T) and the rectum diameter (R) at this level are shown [2].

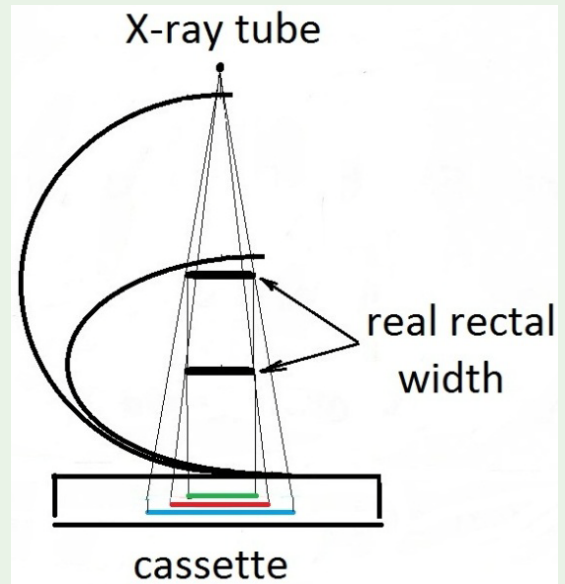


Figure 6: The enlargement of the rectal image on the X-ray depending on the width of the pelvis (Scheme). Green line-the real rectal width; red line-its image in small pelvis; blue line- its image in large pelvis.

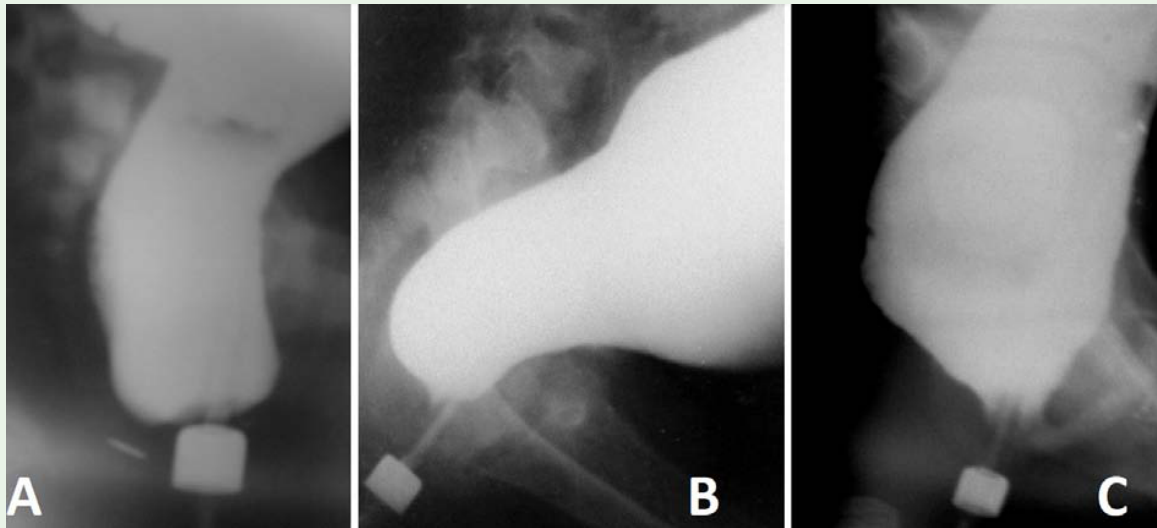


Figure 7: Lateral radiographs of patients with different diseases. The true width of the marker near the anus is 1.6 cm. **A)** A 1.5-year-old girl with vestibular fistula during anal canal opening. The width of the rectum is 3.7 cm. The maximum limit of the norm for children under 3 years old is ~2.8 cm. Conclusion: Anorectal malformation with ano-vestibular fistula and megarectum. The distance between the distal wall of the anal canal and the button near the anal dimple is 0.5 cm. **B)** A 12-year-old boy with chronic constipation. The rectum is wider than the maximum limit of the norm (6 cm vs. 4.6 cm), but the recto-sigmoid index is < 1 . The length of the anal canal is at the lower limit of the norm (3 cm \approx 3.1 cm). The shape of the rectum as in newborns. There is no horizontal branch of the rectum. This indicates a violation of innervation. Puborectalis is not contracted due to the absence of ganglia in the rectum. Conclusion: Hirschsprung disease with a short area of agangliosis not complicated by enterocolitis. **C)** A 9-year-old boy with chronic constipation and encopresis. The rectal width is 9.4 cm vs. the maximum normal limit of 4.1 cm. The anal canal length is 1.8 cm vs. the minimum normal limit of 2.6 cm. Conclusion: Functional constipation of the 3rd stage, stretching of the pelvic floor muscles (descending perineum syndrome).

Penetration of barium from the rectum into the upper part of the anal canal in front of the enema tip as a result of relaxation of the internal anal sphincter. The posterior wall of the anal canal at this level is pressed against the tip of the enema by the contracted puborectalis muscle. A. A four month old child. B. A 15-year-old teenager. The axis of the anal canal is shifted forward. The rectum has vertical and horizontal branches (See also Figure 1).

Between the horizontal part of the rectum and the anal canal an acute (anorectal) angle is formed. In children with a normal physique the retro-rectalspace, i.e., the interval between the posterior wall of the rectum and the anterior surface of the sacrum increases from 0.1 cm in the first year of life, up to 0.5 cm in the older age group.

The length of the rentgen negative space between the rectum and the marker around the anus was 1.7 cm in newborns, and increased up to 3.9 cm in older children. During the barium enema a barium penetration in the upper part of the anal canal in front of the enema tip is observed. At this time, the posterior wall of the anal canal at this level is tightly pressed against the tip. This pattern continued less than one minute and then the barium disappeared from the anal canal. Such a situation arose during barium enema from one to three times. Capacity, i.e. the volume of the colon, increased from 562 ± 38 ml in children of the first year of life up to 1050 ± 32 ml in older children. Integral characteristic quantities of the colon (C) are in the range 19-31.

Discussion

In most cases, the magnitude of the colon evaluated empirically based on previous experience. However, it is impossible to determine precisely about the expansion of any parts of the colon without

knowing of their normal limits. For example in the article of Woody and co-workers on the frontal radiography of the abdomen, which is cited as an example of the norm, a significant extension and elongation of the sigmoid colon is defined. It is wider than the descending colon and extends beyond the pelvis [1].

Meunier et al in 1984 proposed to measure the width of the rectum on the basis of Recto-Pelvic Ratio (RPR). The RPR was obtained by dividing the diameter of the rectal width by the diameter of the linea transversa (T) of the pelvis (Figure 5) [2].

The mean RPR in patients with fecal impaction was 0.68 (range 0.32-0.83). The rectal width in control was 0.52 with upper limit of 0.61 [3]. This method has not found practical application, as the normal and pathological indicators overlap. There are limitations of this method due to two reasons. First, standardization by minimal volume of barium is incorrect. When rectum is empty, it is in the contracted state due to the tonus of its wall. The introduction of 10 ml of barium, regardless of age to a greater extent reflects the tone of the rectum and sigmoid colon, than their size. Secondly, it should be remembered that the rectum is the straight bowel only in dogs. In humans, it is the most curved section. It makes the S-bends in two projections. On the frontal image different segments of the rectum overlap (see Figure 1). The width of the rectum can be measured only in the lateral projection.

Gladman M.A. et al, who examined adults, concluded that the maximum limit of normal width of the rectum in lateral projection is 6.3 cm [4,5]. The width of the rectum increases with age as a result of the increasing the pelvic size and diameter of the stool accumulating in the rectum. This means that the maximum size of the rectum corresponds to the maximum size of the stool. It is enough to draw a

circle with a diameter of 6.3 cm, to ensure that such a diameter of stool may not be the norm. These authors filled of the rectum with barium of volume to 500 ml under minimal pressure. During introduction of 500 ml under minimal pressure, the width of the rectum on the radiograph in patients with megarectum will more reflect the tone of the rectum, than the true diameter, since a contrast medium is unable to stretch of the rectum to its maximum size, and will be distributed into the left part of the colon. Analysis of these papers indicates that the authors did not take into account the increase in the projection, significance of which depends on the distance from the object being studied (rectum) to the cassette. The greater the patient's pelvis, the more its image will increase relative to the norm. At full and large people on the lateral radiograph the rectal size can be 2-fold greater than in reality (Figure 6).

Koppen et al. measured the lengths and diameters of the various colonic segments and rectal diameter on radiographs of children aged 0-5 years who had undergone air contrast enemas for intussusception [6]. However, the results of this study cannot be applied in practice even for young patients. First, all colonic sizes in children with intussusception cannot be considered normal, since intussusception is a serious illness, in which intestinal tone decreases as a result of compression of the mesentery. The decreased tone manifests by widening of the intestinal lumen. Secondly, it is obvious that a higher pressure would lead to more rectal and colonic distension. The mean pressure during hydrostatic diagnostic enema is ranging 40-80 cm H₂O while with pneumatic reduction of intussusception it was more than 100 mmHg. Third, the measurement of the rectum on the frontal radiograph gives a false impression of its width due to the overlap of the loops on each other. Thus, the sizes of the colon and rectum obtained by these authors cannot be considered an age standard for young children, since they are much wider than in healthy patients. The same authors in their subsequent work "... the prevalence of the megarectum / megacolon was determined using the predefined cut-off value of the rectal / colonic width of > 6.5 cm" [8,9].

Hydrostatic barium enema is free from the disadvantages described above. It is standardized by the hydrostatic pressure, on the volume of the colon in each case and the real sizes of all parameters. It differs from the standard method of investigation only by the presence of the contrast marker near the anus and the radiometric analysis of the radiographs. It has never been used in healthy patients to determine normal values. In 1980-1983 barium enema was used for diagnosis of various diseases of the abdomen, including the acute and chronic appendicitis. For this purpose, the cecum and the appendix were filled with the barium [10-13]. The distance between the marker near the anus and rectum ranged from 2.21 ± 0.15 cm in the first year of life up to 3.43 ± 0.10 cm over the age of 10 years. The length of this interval is equal to the length of the anal canal, according to the manometric studies (1.67 ± 0.34 cm in neonates), (1-3 cm in infants), (3.03 ± 0.52 cm in more than one year) [14], 3.5 cm in adults (2.5-4.2 cm) [15]. Since, this area, performs the retention function, as the anal canal, and it has full equality on the length, we have every reason to believe that the distance between the rectum and the marker near the anus represents a contracted anal canal and its length is equal to the length of the anal canal.

We measured the pressure in the anal canal during the filling of the colon with barium. On the lateral view a barium penetration from the rectum into the upper part of the anal canal in front of the

enema tip was sometimes observed. At this time, the posterior wall of the anal canal was pressed against the enema tip (see Figure 4). This phenomenon is accompanied by a decrease in pressure in the anal canal. This situation lasted less than 15 second, after that the barium which penetrated into the anal canal, was squeezed back into the rectum, and this by a rise of anal pressure to basal level was accompanied [16]. It is known that "PRM (puborectalis muscle) contributes to the squeeze pressure in the proximal part of the anal canal and EAS (external anal sphincter) to the distal anal canal. PRM squeeze-related increase in anal canal pressure might be important in the anal continence mechanism" [17]. The peak pressure of the IAS (internal anal sphincter) is seen at a level of 1.6 cm from the anal verge, which corresponds to the peak relaxation pressure. The EAS is the only muscular structure located from 0.5 cm to 1 cm from the anal verge. Finally, the posterior-superior location of the PRM from 2.4 cm to 4.0 cm from the anus was defined [18]. Thus, the X-ray picture of the penetration of barium only to the upper part of the anal canal in front of the enema tip is the radiological equivalent of the rectoanal inhibitory reflex - relaxation of the IAS and contraction of the PRM and EAS.

The proposed method of the barium enema makes it possible to estimate with mathematical precision the magnitude of the rectum and colon. The megarectum determines if the true width of the rectum on the lateral radiograph larger than the maximal size of norm for this age. Megacolon determined by a constant, if it exceeds 31. It has been possible to differentiate megacolon varying degrees depending on the constant (C): 1st degree - (C = 31- 45); 2nd degree - (C = 45-60) and 3rd degree - C > 60. For the first time on the radiographs the length of the anal canal has been measured, allowing to determine the state of the PRM: hypertrophy, weakness or complete failure, in patients with functional constipations and anorectal malformations [8,16].

For each contrast medium have its indications and contraindications. The barium enema is used in diagnosis of the megacolon, including Hirschsprung disease, functional constipation and anorectal malformations. Water-soluble contrast enema is used: after surgery, where possible leakage of the contrast medium into the abdominal cavity; in colostography for visualization of the urethral fistula; in the treatment of the sigmoid colon volvulus.

Conclusion

Hydrostatic barium enema is an accurate method for estimating the magnitude of the rectum and colon, as well as the state of the puborectalis muscles. It can be used for diagnosis of the pelvic floor problem, anorectal and colonic diseases as well as for the scientific analysis of the diseases associated with megarectum and megacolon.

References

1. Wood RJ, Yacob D, Levitt MA. Surgical options for management of severe functional constipation in children. *Curr Opin Pediatr.* 2016; 28: 370-379.
2. Meunier P, Louis D, Jaubert de Beaujeu M. Physiologic investigation of primary chronic constipation in children: comparison with the barium enema study. *Gastroenterology* 1984; 87: 1351-1357.
3. van der Plas RN, Benninga MA, Staalman CR, Akkermans LM, Redekop WK, Taminiou JA, et al. Megarectum in constipation. *Arch Dis Child.* 2000; 83: 52-58.
4. Gladman MA, Dvorkin LS, Scott SM, Lunniss PJ, Williams NS. A novel technique to identify patients with megarectum. *Dis Colon Rectum.* 2007; 50: 621-629.

5. Gladman MA, Knowles CH. Novel concepts in the diagnosis, pathophysiology and management of idiopathic megacolon. *Colorectal Dis.* 2008; 10: 531-538.
6. Koppen IJ, Yacob D, Di Lorenzo C, Saps M, Benninga MA, Cooper JN, et al. Assessing colonic anatomy normal values based on air contrast enemas in children younger than 6 years. *Pediatr Radiol.* 2017; 47: 306-312.
7. Misharev OS, Levin MD. Functional and roentgenological studies of the anorectal area in intestinal diseases. *Khirurgiia (Mosk).* 1984; 12: 78-82.
8. Levin MD, Korshun Z, Mendel'son G. The method of radiographic examination anorectal area. *EkspKlin Gastroenterol.* 2011; 12: 15-21.
9. Koppen IJN, Thompson BP, Ambeba EJ, Lane VA, Bates DG, Minneci PC, et al. Segmental colonic dilation is associated with premature termination of high-amplitude propagating contractions in children with intractable functional constipation. *Neurogastroenterol Motil.* 2017; 29: 1-10.
10. Fee HJ Jr, Jones PC, Kadell B, O'Connell TX. Radiologic diagnosis of appendicitis. *Arch Surg.* 1977; 112:742-744.
11. Hatch EI Jr, Naffis D, Chandler NW. Pitfalls in the use of barium enema in early appendicitis in children. *J Pediatr Surg.* 1981; 16: 309-312.
12. Lewin GA, Mikity V, Wingert WA. Barium enema: an outpatient procedure in the early diagnosis of acute appendicitis. *J Pediatr.* 1978; 92: 451-453.
13. Jona JZ, Belin RP, Selke AC. Barium enema as a diagnostic aid in children with abdominal pain. *Surg Gynecol Obstet.* 1977; 144: 351-355.
14. Kumar S, Ramadan S, Gupta V, et al. Manometric tests of anorectal function in 90 healthy children: a clinical study from Kuwait. *J Pediatr Surg.* 2009; 44:1786-1790.
15. Knowles AM, Knowles CH, Scott SM, Lunniss PJ. Effects of age and gender on three-dimensional endoanal ultrasonography measurements: development of normal ranges. *Tech Coloproctol.* 2008; 12: 323-329.
16. Levin MD. The pathological physiology of the anorectal defects, from the new concept to the new treatment. *Eksp Klin Gastroenterol.* 2013; 11: 38-48.
17. Liu J, Guaderrama N, Nager CW, Pretorius DH, Master S, Mittal RK. Functional correlates of anal canal anatomy: puborectalis muscle and anal canal pressure. *Am J Gastroenterol.* 2006; 101: 1092-1097.
18. Cheeney G, Nguyen M, Valestin J, Rao SS. Topographic and manometric characterization of the recto-anal inhibitory reflex. *Neuro gastroenterol Motil.* 2012; 24: e147-154.