

**Dear Colleagues,**

Superior mesenteric artery syndrome (SVA) is a rare form of duodenal obstruction. Professor Carl von Rokitansky in 1842 first observe that superior mesenteric vessels may compress and obstruct the duodenum over the lumbar spine. Over time, this suspicion has become an axiom. In recent years, the number of descriptions of SMAS has increased dramatically. Diagnostic principles have changed. For its diagnosis and indications for surgery, the presence of obstruction of the duodenum became optional. The gold standard is a decrease in the aortomesenteric angle  $<25^{\circ}$  and a decrease in the distance between vessels  $<8-10$  mm. Surgeons typically perform duodenojejunostomy and report superior results.

It turned out that in the United States and other countries there is a community of patients suffering from SMAS who do not receive proper medical care and are looking for a solution to their problems in other ways. I asked the co-chairman of American society to send me the medical records of their members. I offer you an analysis of the first medical history.

### **1. Anamnesis**

“I was a restless infant, but I spent the first 2 months of life in the NICU due to prematurity and a congenital heart defect (coarctation of the aorta), with open-heart surgery. I tolerated feedings well. The only struggle and something I have struggled with my whole life has been weight gain. Always super thin, always eating small meals throughout the day. I grew up without much of an appetite; ate because I knew I needed to. I was very rarely hungry. I would have cravings often, like normal”.

“I was diagnosed with asthma back around 2010 due to recurrent episodes of pneumonia. After months of treatment for a chronic infection, I have not had any episodes of pneumonia. With that said, I have had a lot of issues since the acid reflux worsened. I continue to have a productive cough that worsens when reflux flares (or off meds). I currently use meds (Xopenex) as needed for acute symptoms. I rarely use the inhaled corticosteroids due to ineffectiveness on symptoms long term”.

Those symptoms that bother me so far appeared at the age of 15. There was post-prandial abdominal pain, which was the stronger, the larger the volume of food. As time went on, the vomiting, nausea, epigastric fullness, and early satiety began. At my worst, there was bilious vomiting, heartburn, and reflux. Throughout the years from symptom onset in 2015, the volume tolerated lessened to about 400kcal/day. At that time, my weight was 50.8kg (BMI- 17.2 (kg / m<sup>2</sup>) and total weight loss was 10kg

Associated Problems and Diseases: Dysautonomia, small fiber neuropathy (SFN), ligament tears, hypoglycemia, cardiac arrhythmias.

C 2015 года for two years, I worked on my diet and limiting things like dairy and gluten thinking it was a food sensitivity. Then I treated for heartburn. By 2017, I had lost quite a bit of weight due to abdominal pain. I was diagnosed SMAS via CTA and was immediately admitted to the hospital for NG tube feeds. The treating hospital was aware of SMAS but was not extremely familiar with treatment options.

Over the next year, I continued to fight with weight loss, nausea, vomiting, heartburn, and flares that would lead to hospitalization. Another scan revealed worsened compression, so an NJ tube was placed. 4 short months later, I tried to eat again, which induced vomiting. The tube was subsequently dislodged. At that time, a new "so trusted" physician said it was all an eating disorder and removed the tube. I spent 8 months going to an eating disorder treatment center. They determined it was not an eating disorder, but something mechanical and I needed to see a specialist.

In August 2019, I ended up admitted again, due to worsening pain, and received a diagnosis of SMAS, and nutcracker syndrome. I was discharged shortly later with a referral to a surgeon.

In October 2019, I underwent a laparoscopic duodenojejunostomy. Initial recovery was quite smooth aside from a couple of minor complications (ileus, anemia). I was released from local lodging 2 weeks post-op and was able to fly home.

« In December, I started experiencing lower right quadrant pain, and fevers (temps up to 39C). I was a little less than 8 weeks post-op from laparoscopic duodenojejunostomy, so my surgeon recommended evaluation in ED for suspected abscess. CT showed a large amount of free fluid throughout the abdomen (I do not have access to the report at this time). CT was cleared for abscess. Since, I have dealt with flares of this, with lower right quadrant pain, fevers up to 39C, diarrhea, mucus in stool, nausea, lack of appetite, and at times, elevated CRP. WBC has been normal. Flares are typically around 2 weeks long. It starts with a fever, loss of appetite, nausea, malaise for the first day or so, then the pain begins in the lower right quadrant. By the first week, there is a roughly 2-inch circle around the belly button with the same pain that began in the right lower quadrant. By the end of the flare, I have lost roughly 3-4kgs. Each flare has gotten worse from when they started in December. Each hit me harder, and last longer, with more weight loss. By the time it starts restoring, another flare hits, and I lose weight again». Weight 48 kg; BMI - 16.2 kg/m<sup>2</sup>.

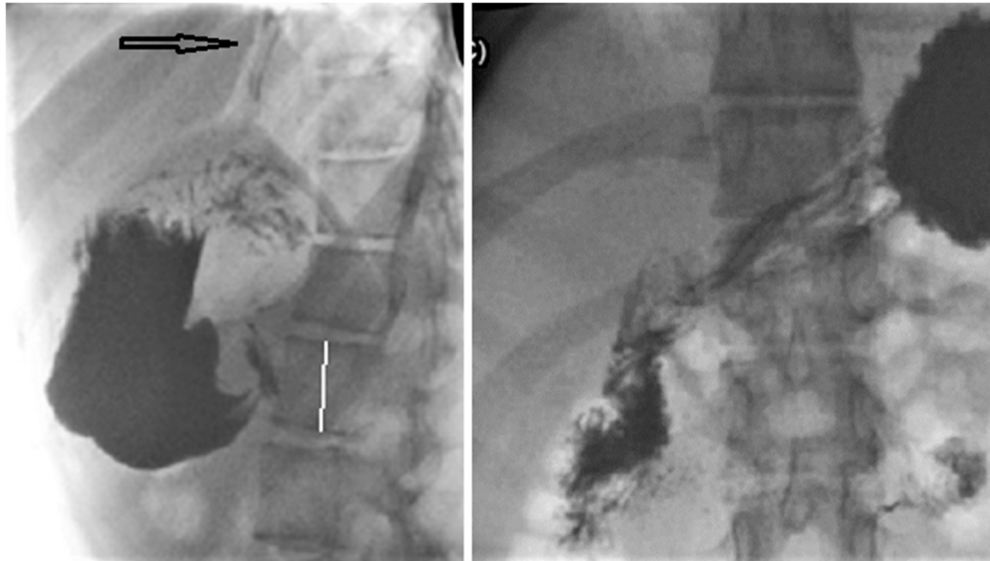
## II. Examinations

1) I had 4 gastroscopy (2017, 2018 [x2], 2019). All 4 were normal, including biopsies. Biopsies looked for inflammation, celiac, disaccharidase. 4th EGD was right after duodenojejunostomy but was not diagnostic towards GERD/heartburn.

2) pH Manometry was delayed due to COVID-19.

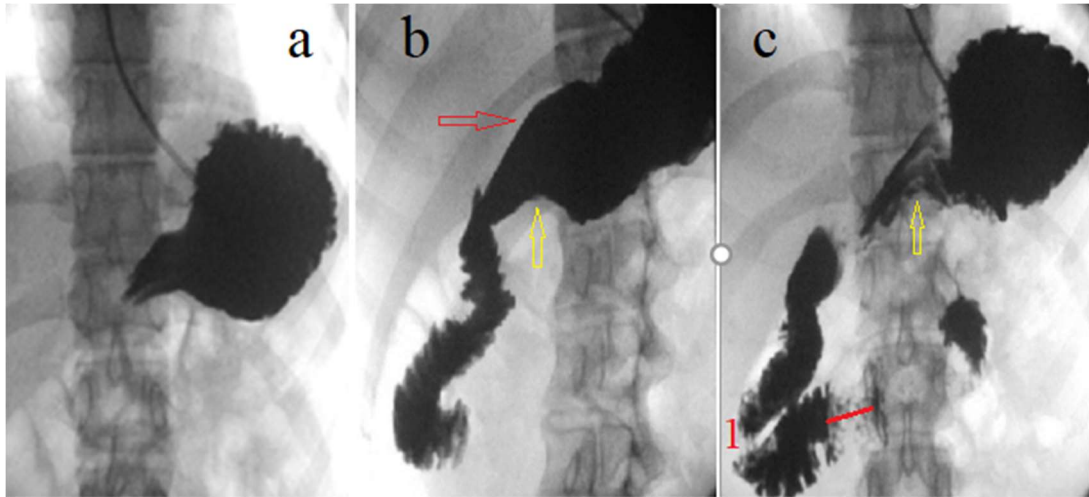
3) X-ray studies

UGI 05/30/2017 (**Figure 1**).

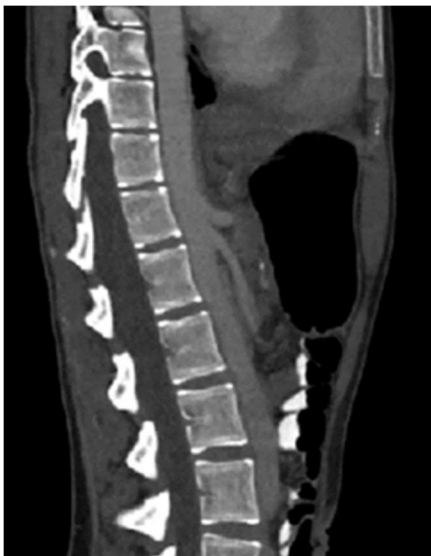

**FINDINGS:** Scout: Nonobstructive bowel gas pattern. The patient swallowed barium without difficulty. The esophagus distends well and shows no mucosal or mural abnormalities. Esophageal motility is normal. No gastroesophageal reflux. No hiatal hernia. No abnormal esophageal impressions identified. Mildly delayed gastric emptying was noted. The stomach distends well and shows no mucosal or mural abnormalities. The ligament of Treitz is in the normal anatomic position with no evidence of malrotation. Normal appearing jejunum is in the left upper abdomen.

UGI 03/21/2018 (**Figure 2**).



**FINDINGS:** Injection of contrast through an enteric catheter into the gastric fundus which is normal opacification of the stomach without evidence of gastroesophageal reflux. Contrast progresses through the duodenal C-loop in a normal fashion. The duodenum appears to demonstrate normal peristalsis. Mild distension of the second portion of the duodenum with focal narrowing of the third portion which could be seen with SMA syndrome.



**Figure 3.** CTA 10/26/2017.

The aortomesenteric angle measures 18 degrees (normal between 25-60 degrees). The aortomesenteric distance measures 8 mm (normal between 10-28 mm) The left renal vein is patent with normal course and caliber.

### **MRI 07/24/2019**

There is compression of the third portion the duodenum as it passes between the aorta and superior mesenteric artery with reduced aortomesenteric artery angle of 15 degrees and reduce aortomesenteric distance of 6 mm. In the presence of a dilated stomach, these findings are suspicious for SMA syndrome.

## CTA 08/21/2019

The stomach is mildly distended with oral contrast but is otherwise unremarkable. The duodenal C-loop is decompressed. Passage of oral contrast material into small bowel with no evidence of bowel obstruction. The appendix is normal. Large fecal burden in the sigmoid colon and rectum.

Abdominal aorta is normal in caliber. Celiac artery, SMA, bilateral renal arteries are patent. Aortomesenteric angle measures approximately 17 degrees. Aortomesenteric distance measures 4 mm. Narrowing of the left renal vein between the SMA and aorta. The left gonadal vein is distended, measuring up to 7mm distally. The right gonadal vein is also distended measuring 7mm in diameter distally with more delayed contrast filling. No mesenteric or retroperitoneal lymphadenopathy. No ascites.

### III. Treatment (05/28/2020).

“Treatment for GERD/Gastritis- initially was on omeprazole for coverage of possible heartburn/reflux in 2017. Continued Omeprazole 40mg for the duration of tube feeds. After an NJ tube in 2018-2019, acid reflux progressed, as well as heartburn. In 2019, I underwent duodenojejunoscopy; hoped that reflux would improve. Throughout post-op, reflux and heartburn became severe, and have been unable to find the right regimen of medications. Awaiting pH study and 5th EGD. October 2019- on Protonix 40mg (Pantoprazole), November 2019-on lansoprazole 30mg (Prevacid), December 2019-back on Omeprazole 40mg. January 2020-Dexlansoprazole 60mg (Dexilant), and Carafate 4x/day.

Currently, treatment for reflux has not been insanely effective, but med choices will expand now that I am of a separate medication unrelated to GI. Dexilant has been the most effective. My current regimen is Dexilant 30mg, Carafate 4x/day, Pepcid PRN, and Maalox (liquid tums) 2x/day. I am also avoiding trigger foods, including tomatoes, onions/garlic, acid foods, greasy foods, etc. Though whole milk has been remarkably effective when drinking multiple times/day... Reflux seems to be the most controlled out of the constant nagging sting/burn in the stomach”.

**IV. Extras.** “I live in an area of the United States that is very rural. In my region, there are no providers familiar with SMAS, nor the surgical options or even the medical options. It would be of benefit for providers to be more "available" even just for diagnosis, so they can refer out to a SMAS specialist. I have to travel >800km, like all SMAS patients, to receive care. Quicker diagnosis leads to a faster recovery, and less risk of developing comorbid conditions, which increases the quality of life. There are complications I will live with for the rest of my life.

Local gastroenterologists are assuming that my reflux is “false reflux”, despite positive improvement in symptoms using dexilant. I was dropped to 30mg 1x/day

in concern of side effects. There is a discussion of going back up to 60mg 1x/day, which worked very well”.

## V. Analysis of the medical history.

### 1. Clinical picture

Table of clinical symptoms and risk factors for the diagnosis of GERD.

Up to 2 years	vomiting	poor weight	dysphagia	fussy infant	cough	putrid breath	wet pillow	anemia
Over 2 years	chest or abdominal pain	heartburn	sinusitis	dental erosion	pulmonary fibrosis	recurrent otitis	cough after eating	asthma
Risk factors	Pre-maturity	Cow's milk intolerance	Acid hyper-secretion	Allergy	Family history		Obesity	Stress

Patient's symptoms and risk factors are marked in red.

a) It is believed that in preterm newborns the LES is functionally underdeveloped, therefore, they often have GERD.

b) In previous works, we showed the relationship of infantile colic syndrome with lactose intolerance. In such people, lactose through mediators (possibly histamine) causes the release of hydrochloric acid. Infant screams because aggressive gastric contents to be thrown into the esophagus, causing severe pain and primary damage to the function of the LES [1,2]. Our patient notes significant relief of abdominal pain and heartburn after drinking milk. This is because milk has a high pH. It suppresses acid, i.e., eliminates the cause of these symptoms. However, after some time, the effect of lactose leads to a sharp increase in hydrochloric acid and the resumption of pain with heartburn with even greater force. Since the relief after drinking milk is not in doubt, and the deterioration after a while is the usual condition, patients are not aware of the trigger of their problems and try to relieve their condition again and again by drinking milk. With age, even a small amount of lactose (in the cake, in a sweet bun or in cottage cheese) can cause a sharp exacerbation of GERD.

c) A baby may have a wet pillow because reflux occurs in a dream. In young children, microaspiration may occur during reflux, which causes bronchospasm and repeated pneumonia. Aspiration of a large volume of stomach contents can cause sudden death syndrome.

d) Coughing, which appears 20-30 minutes after eating, is caused by vertical reflux, due to the large volume in the stomach. Acid causes irritation in the lower part of the esophagus and the reflex response of the esophagus and pharynx,

which secrete mucus to protect the wall of the esophagus. Mucus in the throat causes irritation and coughing.

e) Bronchospasm and chronic cough differ from real asthma in that there is no allergen and symptoms appear much later than typical symptoms of GERD. It is assumed that the origin of these symptoms may be associated with microaspiration or irritation in the wall of the esophagus of the branches of the vagus nerve leads to irritation of the branches of the vagus nerve in the wall of the bronchial tree.

Our patient has a whole bunch of symptoms and risk factors characteristic of GERD. Given the beneficial effect of PPI treatment, the diagnosis of severe GERD is not in doubt. The statement of the attending physicians that the patient does not have a true GERD, unfortunately, is associated with the current state of gastroenterology. Due to the erroneously established boundary of the norm of pH-metry, this method only diagnoses severe forms of the disease. And in cases of a typical GERD pattern, where the results of the study are less than 4-6% pH <4, a hypersensitive esophagus is diagnosed. As a result of this, patients who might бы to receive pathogenetic treatment, and some of them could recover, receive symptomatic treatment until their illness becomes severe enough.

## 2. Diagnostic methods

A) It is known that gastroscopy without a biopsy of the esophagus mucosa does not reveal non-erosive esophagitis.

B) X-ray studies. The radiographs I received correspond to the description of the doctors.

a) The UGI study 05/30/2017 (Figure 1) did not reveal any pathology and could not reveal since the methodology adopted at the dawn of the introduction of the X-ray method was applied. Noteworthy is the delay in barium in the esophagus in the form of two parallel lines, which indicates esophagitis.

b) The UGI study UGI 03/21/2018 (**Figure 2**).

First, in Figure 2b, the red arrow shows the fine-toothed contour of the lesser curvature of the stomach. Secondly, there is a deformation of the antrum of the stomach with a depression on the greater curvature, which is known as the “symptom of the finger”, which indicates a problem (yellow arrows). In Figure 2c, the symptom of the finger is repeated. Thirdly, through “focal narrowing of the third portion which could be seen with SMA syndrome” I draw a red line. This narrowing 1.8 cm long is to the right of D-3 and cannot be the result of pressure between the vessels since the aorta and superior mesenteric artery pass through the center of the vertebra, which corresponds to the location of the spinous processes. This is a typical length and location pattern of Ochsner's sphincter contraction. Cranial to it we see a shorter contraction zone, indicated by

me with the red number "1". This is the contraction sphincter of Kapandji. Fourth, there is no expansion of the stomach and duodenum, barium is evacuated to the jejunum. Therefore, there is no obstruction of the duodenum. **Conclusion:** non-erosive esophagitis, dyskinesia of the stomach and duodenum..

C) CTA - 10/26/2017: MRI - 07/24/2019

SMAS is a special type of duodenal obstruction. Expansion of the stomach and duodenum proximal to the narrowing in the third part of the duodenum is the only reliable symptom of SMAS. If there is no expansion, then there is no obstruction. This is the law of physiology. In this case, SMAS was diagnosed and the operation was performed, even though (1) there was no duodenal obstruction of the, and (2) the clinical symptoms corresponded to a severe form of GERD. The diagnosis of SMAS was made on the basis of a narrow aortomesenteric angle: "There is compression of the third portion the duodenum as it passes between the aorta and superior mesenteric artery with reduced aortomesenteric artery angle of 15 degrees and reduce aortomesenteric distance of 6 mm". However, the narrowing that was described in the X-ray examination on 03/21/2018 (Figure 2) was to the right of the vascular angle.

All articles on SMAS refer to an article by Neri et al [3] as a source of standards for the magnitude of the aortomesenteric angle. In this article, Authors using Color Doppler revealed a significant reduction of the SMA angle ( $<25^\circ$ ) in 29 of 950 patients with dyspepsia and/or abdominal pain; "gastroscopy showed duodenal compressive pulsation in 14 of 29 patients and X-ray revealed compression of the third segment of the duodenum in 28 of 29 patients. All these 29 patients were young adults aged between 19 and 32 years. Dieting had caused rapid weight loss [mean body mass index (BMI)  $18\pm 2$  kg/m<sup>2</sup>] and onset of pain in 10 of 29 (34.5%; all women), whilst 17 of 29 (58.6%; 11 female subjects and 13 male subjects) were tall and underweight (BMI:  $17\pm 3$  kg/m<sup>2</sup>). The remaining two patients presented a normal weight/height ratio (BMI:  $23\pm 1$  kg/m<sup>2</sup>)" [3].

The reliability of the data published in an article by Neri et al is highly doubtful.

Firstly, the authors claim that "the aortomesenteric angle is normally 25–60° [2, 3, 6, 7, 10-12] and the mean aortomesenteric distance of 10–28 mm [1-3, 6, 7, 10-12]". However, in these links, there are no studies of the normal parameters of the aortomesenteric angle. With this lie, the authors wanted to convince the reader of the reliability of their results.

Secondly, in materials and methods, it was stated that the US of the abdomen was performed "in 50 healthy subjects (control group)". However, it turned out that these were patients with various diseases. Thus, neither in the article nor in the references there are normal boundaries of the aortomesenteric angle and the distance between the vessels.



**Thirdly**, the authors claim that in all 29 patients with an aortomesenteric angle  $< 25^\circ$ , SMAS was diagnosed, which was confirmed by X-ray examination. An X-ray and CT were shown to prove this (Figure 4 a, b).

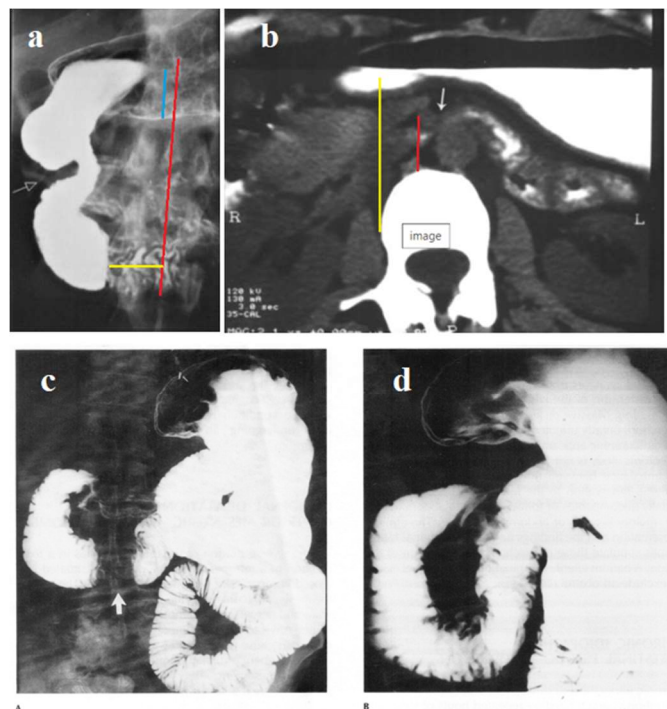


Figure 49.22. Normal patient with transient proximal duodenal dilatation. (A) A frontal projection shows apparent obstruction of the third portion of the duodenum (arrow), suggesting the superior mesenteric artery syndrome. (B) A right anterior oblique view obtained slightly later shows the duodenal sweep to be entirely normal, without any evidence of organic obstruction. (From Eisenberg,<sup>13</sup> with permission from the publisher.)

**Figure 4.** (a) Hypotonic duodenography and (b) CT from article Neri et al [3], presented as SMAS; (c-d) radiographs of the duodenum, performed in different phases of the study, and presented as the norm (from Textbook by Eisenberg) [4].

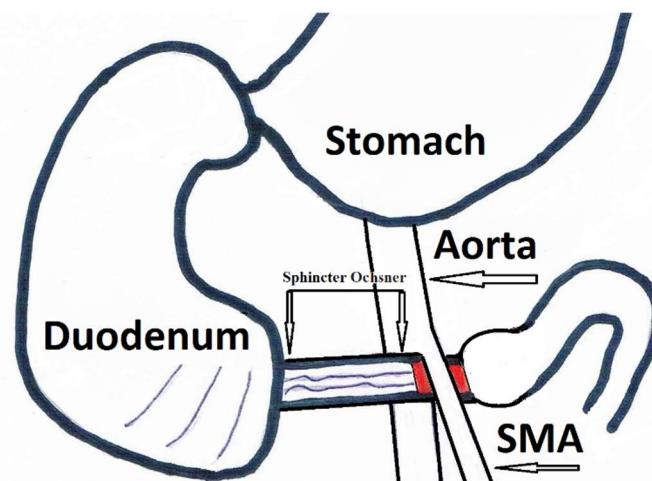
**Analysis.** On radiograph (a) there are no signs of obstruction of the duodenum, since neither the stomach nor duodenum are expanded. The true height of L-1 (blue line) is 2.2 cm. The red line is drawn through the spinous processes where the aortomesenteric angle is located. The distance from the contracted duodenum to the right edge of the SMA (yellow line. See also Figure b) is 2.2 cm. Thus, this narrowing zone in the duodenum, neither in length nor in location, is related to the aortomesenteric angle. The area of narrowing of the duodenum to the right of L-1 is the contraction of Ochsner's sphincter. An area of contraction the proximal to it and indicated by a white arrow is Kapandji's sphincter. X-ray picture indicates dyskinesia of duodenum.

A statistical analysis by Neri et al suggests that patients with symptoms of functional dyspepsia and BMI  $< 20$  often have an aortomesenteric angle  $< 25^\circ$ . This is in line with common sense since it is obvious that thin people have less distance between the navel and the skin of the back, between the stomach and spine, etc. Secondly, Bhagirath Desai et al. produced a prospective study of 100 patients who had undergone a CT scan for various other complaints. A strong positive correlation was found between BMI and the angle between the aorta and

SMA. With BMI increase, the angle also increases. In 25% of patients, these rates were less than the norm, which indicates that the value of the aortomesenteric angle cannot serve as the gold standard for diagnosis SMAS [5]. The hundreds of millions of underweight people of the third world have a "pathologically small" aortomesenteric angle. However, there is no evidence that SMAS more prevailing in the third world than in developed countries.

However, the authors cite two false conclusions. First, they erroneously diagnosed SMAS in patients with duodenal dyskinesia. Secondly, a statement that is not supported by figures and statistical evidence is provided: "Reduced SMA - aorta distance on duodenal stenosis or linear stop of duodenography due to extrinsic compression was not observed in 2672 patients with normal aortomesenteric angle." This statement is not true. Firstly, among patients with functional dyspepsia, as a rule, there is a significant number of patients with weight loss. Consequently, in some of them (2672) the aortomesenteric angle was less than 25°. Secondly, weight loss is not observed in all patients SMAS. Thirdly, it has obvious that the disappearance of symptoms after conservative treatment of 2-59 ( $13.4 \pm 2.9$ ) days is not associated with the appearance of a fat pad in the aortomesenteric angle. It was shown that during the remission this angle does not change [6]. From the article by Neri et al, it follows that a decrease in the aortomesenteric angle is observed only with SMAS. This unscrupulous work opened Pandora's Box, because of which the lie scattered around the world and the surgeons operate on patients without obstruction of the duodenum are on only because they have functional dyspepsia combined with low weight.

In the previous work, we proved that SMAS is an obstruction of the third part of the duodenum because of dyskinesia (achalasia) of Ochsner's sphincter [6,7] (**Figure 5**).



**Figure 5.** The pathophysiology scheme of SMAS. The narrowing in the third part of the duodenum is due to dyskinesia of sphincter's Ochsner. It is located to the right of the aortomesenteric angle, i.e. in length and location, it cannot be caused by compression of the intestine between the vessels.

## VI. Conclusions on the medical history.

A young woman from infancy suffers from a severe form of GERD, because of weak LES and high acidity of gastric juice. She was not diagnosed correctly, so she received only symptomatic treatment. She has a clinical picture of non-erosive esophagitis, gastritis, and duodenitis. In 2019, despite the absence of duodenal obstruction, only based on a decrease in the aortomesenteric angle, the diagnosis of SMAS was erroneously made and duodenojejunoscopy was performed. After surgery, aggressive gastric contents without delay enter the small intestine, causing irritation, which is manifested by new symptoms (pain in the right side of the abdomen, diarrhea, and mucus in the stool). (I cannot explain the periodic temperature rises).

## References

1. Levin MD. Pathophysiology of lactose intolerance. [https://4d90110e-2e9f-4032-b658-72b6d84114fd.filesusr.com/ugd/4d1c1d\\_0fdf98160b544bb2bb46595552886ad1.pdf](https://4d90110e-2e9f-4032-b658-72b6d84114fd.filesusr.com/ugd/4d1c1d_0fdf98160b544bb2bb46595552886ad1.pdf)
2. Levin MD. The development of GERD in the Ashkenazi Jewish family. [https://4d90110e-2e9f-4032-b658-72b6d84114fd.filesusr.com/ugd/4d1c1d\\_b20f340cfb78436f9f1894bc1f721a7f.pdf](https://4d90110e-2e9f-4032-b658-72b6d84114fd.filesusr.com/ugd/4d1c1d_b20f340cfb78436f9f1894bc1f721a7f.pdf)
3. Neri S, Signorelli SS, Mondati E, et al. Ultrasound Imaging in Diagnosis of Superior Mesenteric Artery Syndrome. *J Intern Med.* 2005 Apr;257(4):346-51. doi: 10.1111/j.1365-2796.2005.01456.x.
4. Diagnostic imaging in internal medicine. Ed/ by Ronald I. Eisenberg. McCraw-Hill Book Company. 1985. P. 694.
5. Bhagirath Desai A, Sandeep Shah D, Jagat Bhatt C, et al. Measurement of the Distance and Angle Between the Aorta and Superior Mesenteric Artery on CT Scan: Values in Indian Population in Different BMI Categories. (2015) *Indian J Surg.* Dec;77(Suppl 2):6147. doi: 10.1007/s12262-013-0941-1. Epub 2013 Jul 14. PubMed.
6. Levin MD. Ochsner's Sphincter Dyskinesia Is the Cause of Superior Mesenteric Artery Syndrome. *J Gastrointest Surg.* 2019 Aug;23(8):1714-1716. doi: 10.1007/s11605-019-04246-5. Epub 2019 May 29. PMID: 31144190. [https://4d90110e-2e9f-4032-b658-72b6d84114fd.filesusr.com/ugd/4d1c1d\\_3df651b1d889452c9896f2da5a8c897e.pdf](https://4d90110e-2e9f-4032-b658-72b6d84114fd.filesusr.com/ugd/4d1c1d_3df651b1d889452c9896f2da5a8c897e.pdf)
7. Levin MD. Superior mesenteric artery syndrome: Myths and reality. [https://4d90110e-2e9f-4032-b658-72b6d84114fd.filesusr.com/ugd/4d1c1d\\_fc020ab1e8584a69b75659e9da4e9c13.pdf](https://4d90110e-2e9f-4032-b658-72b6d84114fd.filesusr.com/ugd/4d1c1d_fc020ab1e8584a69b75659e9da4e9c13.pdf)