

Embryological development of the anorectal malformations. Hypothesis

Michael D. Levin MD, PhD.

Abstract

The embryology of anorectal malformations (ARMs) remains largely speculative. While some authors suggest that ARMs arise from abnormal development of the cloaca, the embryonic cloaca never passes through a stage that resembles any form of ARM observed in neonates. Some claims made by clinicians contradict established scientific data. The aim of this study, based on our own functional X-ray studies of the anorectal area in both healthy individuals and those with ARM, as well as an analysis of the existing literature, is to investigate the embryonic development of ARM. Results: The presence of a functioning anal canal in most patients with both low and high types of ARMs can be explained by the migration of the internal anal sphincter (IAS) in the craniocaudal direction, creating an anal canal up to the subcutaneous layer opposite the anal fossa. When the IAS does not encounter the ectodermal primordium, as evidenced by the absence of the anus, it deviates forward and upward, forming a narrow, short, and rigid fistula in the wall of penetration. This process results in the ectopic placement of the anus on the perineum, vestibule of the vagina, urethra, or in the vagina. What surgeons typically remove during the pulling procedure under the guise of fistula excision is, in fact, a functioning anal canal. A thin but long, rigid fistula occurs when the IAS is displaced toward the root of the scrotum. Unlike a true cloaca, a persistent cloaca develops due to the penetration of the IAS through the vaginal wall before a cavity has formed in the vagina. As a result, the IAS creates a narrow, long fistula in the vagina, which in some cases prevents the emptying of the upper vagina, leading to hydrocolpos. These patients usually have a normal bladder and urethra, and in some cases, a functioning anal canal has been documented. Poor outcomes are often the result of unnecessary surgeries. What is often called rectal atresia, and stenosis has also been demonstrated to be in the anal canal, approximately 1 cm from the anal verge. This anomaly likely occurs due to a failure of membrane disruption at the site of the fusion of the endodermal and ectodermal primordia of the anal canal. The membrane can be excised through an anal approach, thereby preserving the anal canal. A classification based on modern scientific data is proposed. Conclusion: This hypothesis is submitted for scientific testing.

Keywords: Anorectal malformations; embryology, anal ectopy; persistent cloaca; rectal atresia; hypothesis; classification.

1. Introduction

Knowledge of embryology is crucial for understanding anorectal malformations (ARMs) [1]. However, there are more hypotheses in the literature than established scientific facts. The embryologist Kluth described this problem as follows: “Today, the normal and abnormal development of the hindgut is still a matter of speculation. (1) the embryonic cloaca never passes through a stage resembling any form of anorectal malformation in neonates, including the so-called 'cloacas' in female embryos, and (2) studies on abnormal embryos are essential to explain abnormal development" [2]. Below are undeniable scientific facts regarding the embryological development of the anorectal zone:

1.1. Indisputable Scientific Facts of Anorectal Embryological Development

1.1.1. The genitourinary septum descends and separates the cloaca into two channels: the rectum posteriorly, and the bladder and urethra (urethra and vagina in females) anteriorly [3,4].

1.1.2. Immediately after cloacal separation, the internal anal sphincter (IAS) is located away from its intended site in the ectoderm (perineum). “Normally, in the post-cloacal period, the endodermal internal anal sphincter migrates in the craniocaudal direction to meet with the ectodermal portion” [5]. This refers to the unique ability of the IAS to create a channel through the tissues of the perineum (self-creation).

1.1.3. The anal canal is divided into superior and inferior parts. The superior two-thirds are derived from the endoderm and are lined by simple columnar epithelial cells. The inferior one-third is derived from ectoderm and is lined by stratified squamous epithelial cells. The junction between these two types of epithelia is called the pectinate line or the dentate line [1,2,3].

1.1.4. During the 10th week, the anal tubercles, a pair of ectodermal swellings around the proctodeal pit, fuse dorsally to form a horseshoe-shaped structure and anteriorly to create the perineal body [4]. This suggests that the formation of the distal ectodermal part of the IAS begins from the perineum and occurs through upward migration to meet the endodermal part of the IAS.

1.1.5. According to the study of Nobles (1984), at the junction of the endodermal and exodermal rudiments, the anal membrane at first appears, which ruptures during embryos with a length of 13.5–135 cm [6].

These undeniably reliable data lead to the conclusion that ARMs may occur during two periods of embryological development: (1) During the formation of the cloaca, when the further development of the anorectum stops, leading to the formation of a cloaca, like that found in birds and reptiles. In these cases, the bladder, uterus, and rectum empty into a wide cavity called the cloaca, and there is no development of the urethra, vagina, and anal canal [4]. (2) In a later period, ARM occurs due to the cessation of development of the exogenous part of the anal canal, as evidenced by the absence of an anus in the anal dimple.

2. Regularities of pathological anatomy and physiologists of ARMs.

2.1. All ARMs, except for a very rare true cloaca, are characterized by the absence of the anus within the subcutaneous portion of the external anal sphincter (EAS). Clearly, this indicates a disruption in the formation of the ectodermal part of the anal canal. Congenital stenosis of the anus, as well as atresia and stenosis of the anal canal rather than the rectum, will be discussed separately.

2.2. All fistulas are in the projection of the central sagittal plane. They are always displaced forward and upward from where the anus is normally located.

2.3. In cases of visible (perineal and vestibular) fistulas, they are slightly displaced upward from the anal dimple. The degree of upward displacement increases in cases of invisible fistulas.

2.4. In all cases of visible (perineal and vestibular) fistulas, there is a normally functioning anal canal, as evidenced by X-ray and manometric studies [7,8], as well as the successful outcomes of the cutback procedure, which does not damage the anal canal [9]. These postulates are discussed in detail below.

3. Radiological studies at ARMs

3.1. ARMs with visible fistula.

On X-ray examination at rest, the anal canal remains in constant contraction, preventing fecal leakage, as it does normally (**Figure 1a, c**). Its length corresponds to the normal length of the anal canal for the child's age. During bowel movements, the anal canal opens widely, as it should, to reduce resistance to the passage of feces (**Figure 1b**). When examined with a Foley catheter, the balloon inflated in the rectum easily passes through the anal canal and is held over

a narrow, rigid fistula, which varies in length from 2 to 4 mm, depending on the child's age (**Figure 1d, e, f**). This length is influenced by the thickness of the skin and subcutaneous tissue.

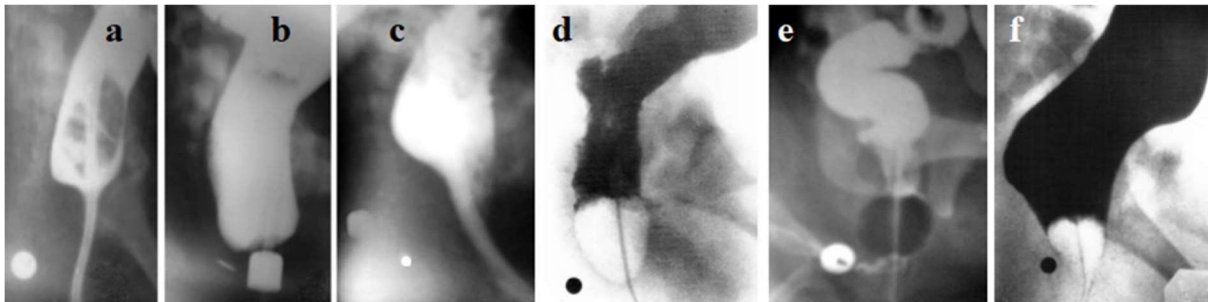


Figure 1. Lateral radiographs of the anorectum in patients with ARMs with visible fistulas. (**a-b**) Images of the same child taken at different times. (**a**) A catheter was inserted through the vestibular fistula into the rectum for enter contrast substance into the intestine. At rest, the anal canal is contracted around the catheter. (**b**) During a follow-up examination, an attempt to defecate resulted in a wide opening of the anal canal. The distance between the marker in the anal dimple and the wall of the opened anal canal is 4 mm. (**c**) During the administration of barium, relaxation of the IAS occurred, allowing barium to enter the upper part of the anal canal, in front of the rectal tube. At this moment, the posterior wall of the anal canal is pressed against the rectal tube by the contracted PRM. This is an X-ray manifestation of the rectoanal inhibitory reflex. The IAS is fixed to the rigid ring through which it extends outward. (**d, e, f**) When the anal canal is opened, the distance from the wall of the anal canal to the marker in the anal dimple ranges from 2 to 4 mm, depending on the patient's age [8].

Thus, in X-ray examinations of patients with visible fistulas, a functioning anal canal was always observed. It differed from a normal anal canal only by the absence of a distal section 2-4 mm in length, which is typically surrounded by the subcutaneous portion of the EAS. The anal canal is opened through a narrow, rigid fistula located in front of the anal dimple on the perineum or in the vestibule. The presence of a normally functioning anal canal is further confirmed by manometric studies. Both the basal anal pressure, and the rectoanal inhibitory reflex were consistent with a normal anal canal function [8,10].

3.2. ARM with long anopenile fistula.

Craniocaudal penetration of IAS along the natural path causes the formation of a normal anal canal. However, the displacement of IAS beyond the limits of this path leads to the formation

of a narrow rigid fistula. This channel can be very short if IAS penetrates through the subcutaneous tissue and skin inside the subcutaneous portion of the EAS, which leads to an congenital stenosis of the anus. But this fistula can be long when IAS is created by a long narrow rigid canal in the subcutaneous tissue until it penetrates outward. This is how anopenile fistula arises, which opens under the scrotum (**Figure 2**).

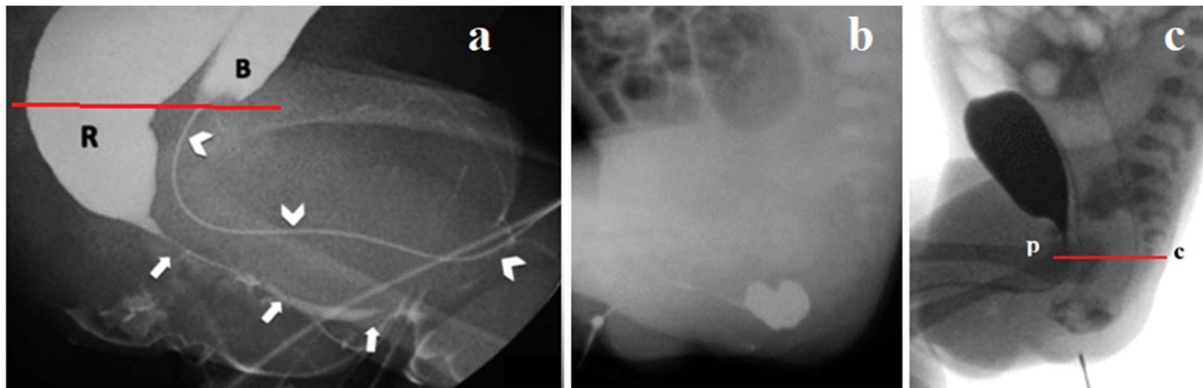


Figure 2. (a). Sfoungaris et al presented the case of a male neonate with imperforate anus and a fistula exiting on the penile skin. "Colostogram and urethrography. Course of rectopenoscrotal fistula (arrows) and urethra (arrowheads). R: rectum, B: urinary bladder» [11]. (b, c) Yang et al described rectopenile fistula [12].

I drew the pubococcygeal line (red). Gas-filled the distal part of the intestine, referred to by the authors as the rectum, is actually the anal canal. In both cases, an open anal canal is visible below the pubococcygeal line. A long, narrow fistula extends under the skin from the already formed anal canal to the root of the scrotum. These typical cases demonstrate that when the IAS penetrates tissues beyond its natural path, it creates a narrow, rigid fistula, the length of which depends on the distance between the anal canal and the point of entry into any cavity or outward. This suggests that the IAS first reaches the subcutaneous tissue opposite the anal fossa. After forming a normal anal canal, if it does not encounter the ectodermal rudiment coming towards it, it turns forward and continues until it penetrates a cavity.

The findings described above are consistent with a recent statement by pediatric surgeons from the ARM-Net Consortium: "According to present knowledge, the 'fistula' in ARM represents an ectopic anal canal and should be preserved as far as possible to improve the chance for fecal continence" [13]. As this definition indicates, the authors do not limit the ectopia of the anal canal to visible fistulas alone, which is confirmed by both manometric and radiological studies [14].

3.3. ARMs Without Visible Fistula

In most cases of ARM without visible fistulas (whether without a fistula, with urethral or vaginal fistulas), a normally functioning anal canal is present, as evidenced by X-ray imaging [8] (Figure 3), manometric studies, and good outcomes after surgery that do not damage the anal canal. For instance, Ohama et al. demonstrated in a canine experiment that the functional IAS, which exists at the rectal end even in high and intermediate anorectal malformations, should be preserved during reconstruction due to its critical role in maintaining anal continence [15]. Kyrklund et al. reported remarkable long-term outcomes using the cutback procedure in boys with perineal fistula. Preservation of the anal canal did not lead to fecal incontinence, and constipation gradually resolved, particularly if the operation was performed before the development of megacolon [9] (Figure 3).

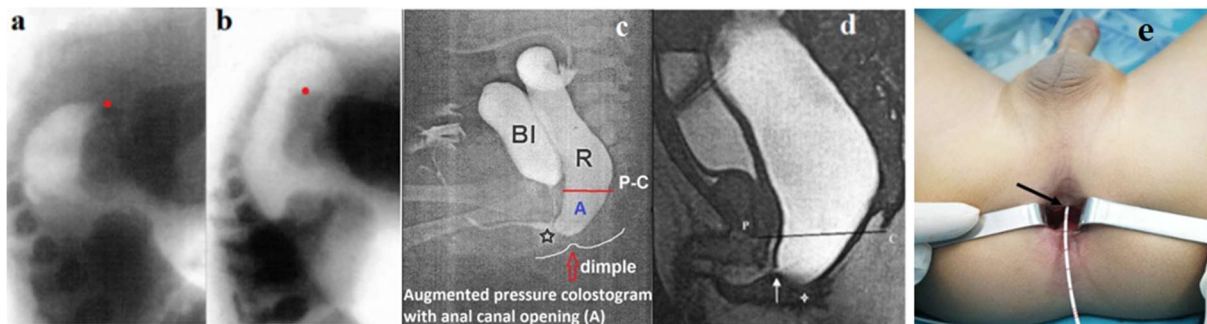


Figure 3. Studies of ARMs without visible fistula

(a, b) Radiographs were taken of a newborn without a visible fistula in a horizontal position: (a) before and (b) during abdominal compression. The red dot indicates the caudal contour of the ischium. During abdominal compression, the anal canal opened completely, allowing gas to approach the skin of the perineum. (c, d) Augmented-pressure distal colostograms: (c-X-ray) and (d-MRI). In both cases, under the influence of very high pressure, the anal canal opened, and its caudal wall approached the anal dimple. (e) The urethral fistula (arrow) was located 1 cm above the anal edge without any obvious scar (from the article by Huang et al.) [16].

A fistula is the short channel in the wall of the organ through which the IAS penetrates organ. Its length equal to the thickness of that wall. Although the site of IAS penetration in urethral and vaginal fistulas is significantly higher than in cases with visible fistulas, by the time of displacement, the anal canal is already formed, and its blind ending is located 2-4 mm from the anal dimple. Since ARMs with urethral and vaginal fistulas, as well as those without fistulas, have a normally formed anal canal, they should be considered low types. Kraus et al. confirm

these observations: "It is extremely important in this regard to understand that the lowest part of the rectum is usually collapsed due to the muscle tone of the funnel-like striated muscle mechanism that surrounds the rectum in 90% of cases..." [17]. However, it is well known from anatomy that there are no muscles around the rectum. The muscles that compress the intestine and prevent the leakage of intestinal contents are located around the anal canal. Since the authors do not cite any specific studies, the 90% figure should be interpreted with caution. From the above data, it follows that the IAS is involved in the formation of the anal canal until it reaches the subcutaneous tissue. It can penetrate outward through the ring of the subcutaneous portion of the EAS. Any such penetration is almost always accompanied by the formation of stenosis at the penetration site, leading to congenital anal stenosis. More often, the IAS moves anteriorly and upward, each time leaving behind a functioning anal canal (Figure 4).

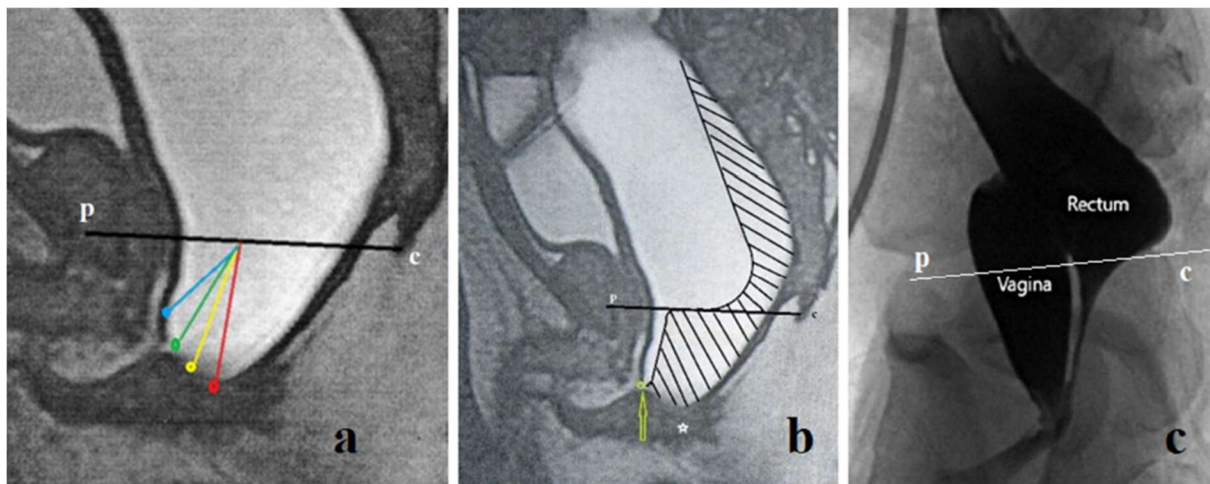


Figure 4 (a) Schematic representation of different variants of ARP in men depending on the degree of upward displacement of the IAS: red indicates the normal position of the anus (congenital anal stenosis); yellow - perineal fistula; green - bulbar fistula; blue - prostatic fistula. At high pressure in the rectum, the anal canal is wide open. **(b)** At rest, the anal canal contracts. **(c)** In a girl with a low vaginal fistula, the rectum is not dilated. The contrast agent introduced through the colostomy passes through the anal canal and comes out of the vagina in a wide stream. The moment of contraction of the anal canal is recorded.

The anal canal is fixed at the point where it penetrates any cavity (**Figure 4a**). Therefore, at rest, when it is in a contracted state, it is far from the anal dimple

and cannot be located during surgery through an incision in the EAS ring (**Figure 4b**). Since the point of attachment is closer to the rectum than normal, the length of the closed anal canal is shorter than the age norm. However, during defecation, the levator plates stretch the walls of the anal canal, bringing its distal wall closer to the anal dimple (**Figure 4a**). Consequently, during defecation, the length of the anal canal from the pubococcygeal line to the marker in the anal dimple is equal to the length of a normal anal canal.

Based on the analysis of the literature, it can be assumed that almost all ARMs, except for true cloaca, have a functioning anal canal and are therefore low-type defects. I was unable to find any radiological studies on bladder neck fistulas. To determine definitively whether ARM with bladder neck fistula is a high anomaly, more research is needed, particularly involving high rectal pressure provocation.

4. Cloaca

4.1. The True Cloaca

From an embryological point of view, "Persistent Cloaca is a rare condition that occurs only in female infants. It results from the total failure of the urorectal septum to descend, and therefore occurs at a very early stage of development (10-mm stage)" [7]. This condition is an example of atavism, where development halts at a stage typical of birds and reptiles. It is characterized by the confluence of the rectum, vagina, and bladder into a urogenital sinus, resulting in the complete absence of the urethra, vagina, and anal canal.

4.2. The So-Called "Persistent Cloaca"

An ARM, now referred to as persistent cloaca, before Hendren's classification was known as ARM with recto-vaginal fistula because feces were expelled from an opening in the perineum in the absence of an anus. The reason for highlighting this anomaly was the existence of two similar types of anomalies. In rare cases, the vagina had a wide lumen (see Figure 4 c). More commonly, a narrow, rigid canal was observed, and in some cases, a closed cavity formed in the upper part of the vagina, leading to the accumulation of a large amount of fluid (hydrocolpos). Hendren termed this second type of anomaly persistent cloaca [18]. Although

the anatomical and physiological descriptions of this defect lack a scientific basis, these children are often treated as though they suffer from a true cloaca [19].

4.2.1. Comparison of the results of different treatment methods.

As shown in the systematic review by Versteegh et al., after treating a “persistent cloaca” as if it were a true cloaca, voluntary bowel movements were reported in 57% of patients, soiling in 71%, and constipation in 51%. Spontaneous voiding was reported in 46%. Additionally, 42% of patients used intermittent catheterization, and 22% had a urinary diversion [20]. First, in the treatment of vaginal fistulas before categorizing them, there were no issues with urinary diversion. Comparisons of outcomes before and after changes in diagnosis from vaginal fistula to persistent cloaca are not described in the literature. Secondly, Kittur and Vora conducted a follow-up study involving one adolescent and eight adult female patients born with cloaca, who had undergone rectal pull-through surgery in infancy, leaving the urogenital region untouched. After full growth, the common channel was used as a vagina with introitoplasty and dilatation, or with additional surgical intervention. All patients retained an intact urogenital complex, and none experienced recurrent urinary tract infections until adolescence. All patients are now beyond adolescence, and five have married. Three reported regular sexual intercourse, and one has conceived. Of the three patients who are not married, introitoplasty was performed to allow for free menstrual flow. Only one of the nine patients reported urinary and fecal incontinence. The authors argue that there is a strong case against subjecting cloaca patients to TUM, as it has a significant potential to cause urinary incontinence. Furthermore, the common channel can be used as a vagina in conjunction with introitoplasty and dilatation [21]. AbouZeid, based on the analysis of long-term results, concluded that in some cases of cloaca, it might be better from both functional and cosmetic perspectives to perform only introitoplasty while leaving the common urogenital sinus uncorrected [22]

3.2.2. Changing the understanding of the anatomy and physiology of the persistent cloaca was not based on scientific research.

Hendren did not conduct any studies to assess the function of the urinary system and lacked a clear understanding of the pathological anatomy of the defect. For example, he believed that hydrocolpos resulted from vaginal distension by urine. He wrote: “Intermittent catheterization of the bladder and/or urine-filled vagina can often provide adequate decompression” [19]. Peña adopted the idea of persistent cloaca. However, neither he nor his colleagues conducted studies on the state of the urinary system. In 1997, Peña proposed the

total urogenital mobilization (TUM) operation to repair cloaca. During the presentation of his article, Hendren asked, "Do you think the external urethral sphincter is of any importance in these patients? And if it is, do you think this mobilization risks any injury to the external sphincter?" Peña responded, "My experience in managing cloaca is that girls who suffer from urinary incontinence do so not because of a lack of urinary sphincter but rather due to the lack of bladder contractility" [23].

First, neither before the presentation nor to this day has Peña or anyone else published any studies on the function of the urinary system in cloaca patients prior to surgery. Everyone, following Peña, attributes the poor surgical outcomes to congenital pathology. If the word "experience" is interpreted as experimenting on sick children, it cannot be deemed ethical. Furthermore, it is an absolute failure when comparing the results operations proposed by Peña with those described by Kittur and Vora [21], as well as AbouZeid [22].

3.2.3. The description of the anatomy of the persistent cloaca contradicts the laws of embryology.

Currently, following Hendren and Peña, it is believed that the urethra, vagina, and rectum are connected during the embryonic period into a single canal called the cloaca. However, the presence of distinct urethral, vaginal, and anal canals suggests that the cloacal membrane has already divided the cloaca into the urogenital sinus and the intestine. In the post-cloacal period of development, three separate canals form within the perineal tissues, with their walls adjacent to each other. There is no evidence to suggest that these three canals can fuse into a single channel, especially not in one specific location. This assumption contradicts common sense. Furthermore, in a study by Runck et al., the molecular pathologies underlying cloacal malformations were examined. Their findings using Shh knockout mice showed that "...the epithelium from the common channel has matured and does not exhibit the same characteristics as cloacal epithelium before septation..." [24]. This means that the epithelial samples taken by pediatric surgeons from the so-called "common canal" were more mature than what would be expected in an undivided cloaca. From an embryological perspective, therefore, the "persistent cloaca" has no relation to the cloaca.

3.2.4. Persistent cloaca from a statistical point of view.

In a retrospective review by Rosen et al. of all girls with ARM treated by Peña from 1980 to 2000, only 6 out of 617 patients were found to have a true rectovaginal fistula, an incidence

of 1%. In numerous cases where a vaginal fistula was diagnosed at other institutions, the authors considered it a misdiagnosis, asserting that it was actually a persistent cloaca [25].

Statistical analysis reveals a surprising pattern in the distribution of different forms of ARM, which is consistently replicated across various studies. For instance, the initial results of a European multi-center registry of patients with anorectal malformations (Figure 5a) [26] found that rectal atresia/stenosis (RA/RS) occurred in 1% of 200 cases. In another statistical study involving 2,619 patients, RA and RS were identified as rare types of ARMs, accounting for 1.3% of patients in the ARM-Net registry [27]. The reason for this remarkable consistency is not yet understood [28]. However, based on the varying frequencies of different ARM forms, the following conclusions can be drawn:

(a) The higher the ectopic anus is located, the less common these ARMs are (perineal fistulas are most common, while bladder neck fistulas are least common);

(b) Among patients of different sexes, the frequency of ectopia of the anus at the same distance from the anal fossa is approximately equal. For example, the frequency of perineal fistulas is almost the same in children of different sexes. Perineal and vestibular fistulas in girls correspond to perineal and bulbar fistulas in boys. The vagina, which is found along the path of IAS ectopia over a large area, suggests that vaginal fistulas cannot be a rare type of ARM (1% - [27]; 0.7% - [28]). The percentage consistency of high ectopia in children of different sexes is restored if we recognize that all cases of persistent cloaca resulted from the penetration of the internal anal sphincter (IAS) through the vaginal wall.

Only in one article the ratios of different types of ARMs are strikingly inconsistent with the above-described patterns, which casts doubt on their reliability. The ratios presented in Peña's article, which was allegedly published in collaboration with Devries but without his consent, show a completely different pattern (Figure 5b) [29]. While scientific statistics indicate that patients with perineal fistulas make up 43% and those with various types of urethral fistulas account for 25% (a difference of 1.7 times), Peña reported 11% of low (i.e., perineal) fistulas and 78% of various fistulas in the urethra (a difference of 0.14). This is a 12-fold more urethral fistula than perineal fistula compared to generally known statistics.

Until 1982, isolated cases of cloaca were described. Okonkwo and Crocker wrote in 1977 that "Cloacal dysgenesis is a rare anomaly. Fifty cases have been reported in the literature" [30]. For a novice surgeon like Peña, the true cloaca, as shown in the diagram, accounted for 1.8%, while RA/RS represented 3.7%. Peña allegedly operated on all types of ARMs, including a

pathology that does not align with the embryology of ARM and has not been described elsewhere (Figure 13, from Peña's article) [29] (Figure 5).

Male	Total n = 98 ^a	%	Female	Total n = 102	%
Perineal	42	43	Perineal	42	41
Recto urethral	28	29	Vestibular	29	28
<i>bulbar</i>	14	15			
<i>prostatic</i>	12	12			
<i>unspecified</i>	2	2			
Bladder neck	6	6	Cloaca	8	8
			<3 cm common channel	2	2
			>3 cm common channel	2	2
			<i>unspecified</i>	4	4
No fistula	15	15	No fistula	4	4
Anal stenosis	3	3	Anal stenosis	5	5
Rare type ^b	4	4	Rare type ^b	14	14

^a For 3 male patients the type of malformation was unknown.
^b Rare type: 1 anterior ectopic syndrome, 2 cloacal extrophy, 1 rectal atresia, 1 rectal stenosis, 2 recto-vaginal fistula, 2 H-type fistula, 3 pouch colon, 6 other.

Male	
Urethral fistula	25
High malf., no fistula	4
Vesical fistula	3
Low malformation	4
Complex malformation*	1
Secondary operation	2
	<u>39</u>
Female	
Vaginal fistula	1
High malf., no fistula	1
Low malf., no fistula	1
Rectal atresia and stenosis	2
Rectovestibular fistula	2
Complex malformation†	7
Secondary operation	1
	<u>15</u>

*Case #3, rectal atresia.
†Includes the cloacas, rectal atresia and rectal stenosis.

Figure 5. (a). An example of the statistical regularity in the distribution of different types of ARMs can be found in the article by de Blaauw et al [26]. The total number of "cloaca" and rectovaginal fistulas (10) aligns more closely with the number of high ectopias in boys (18) (c). The statistics from the surgical experience of the young surgeon Peña, as published in his article [29], show that only the ratio of perineal ectopy with urethral fistulas deviates by 12 times compared to the stable patterns observed in other studies. This article was published two months after the article by de Vries and Peña [31]. During these two months, not only did the name of the co-author change, but the number of children operated on increased from 34 to 54. This is a documentary assessment of Peña's experience.

3.2.5. Radiological diagnostics of the anatomy of the persistent cloaca.

Radiological diagnostics are used to determine the confluence site of the urethra, vagina and rectum. The surgical treatment method depends on the fusion level [32, 33]. Figure 6 shows the assessment methods from MRI studies.

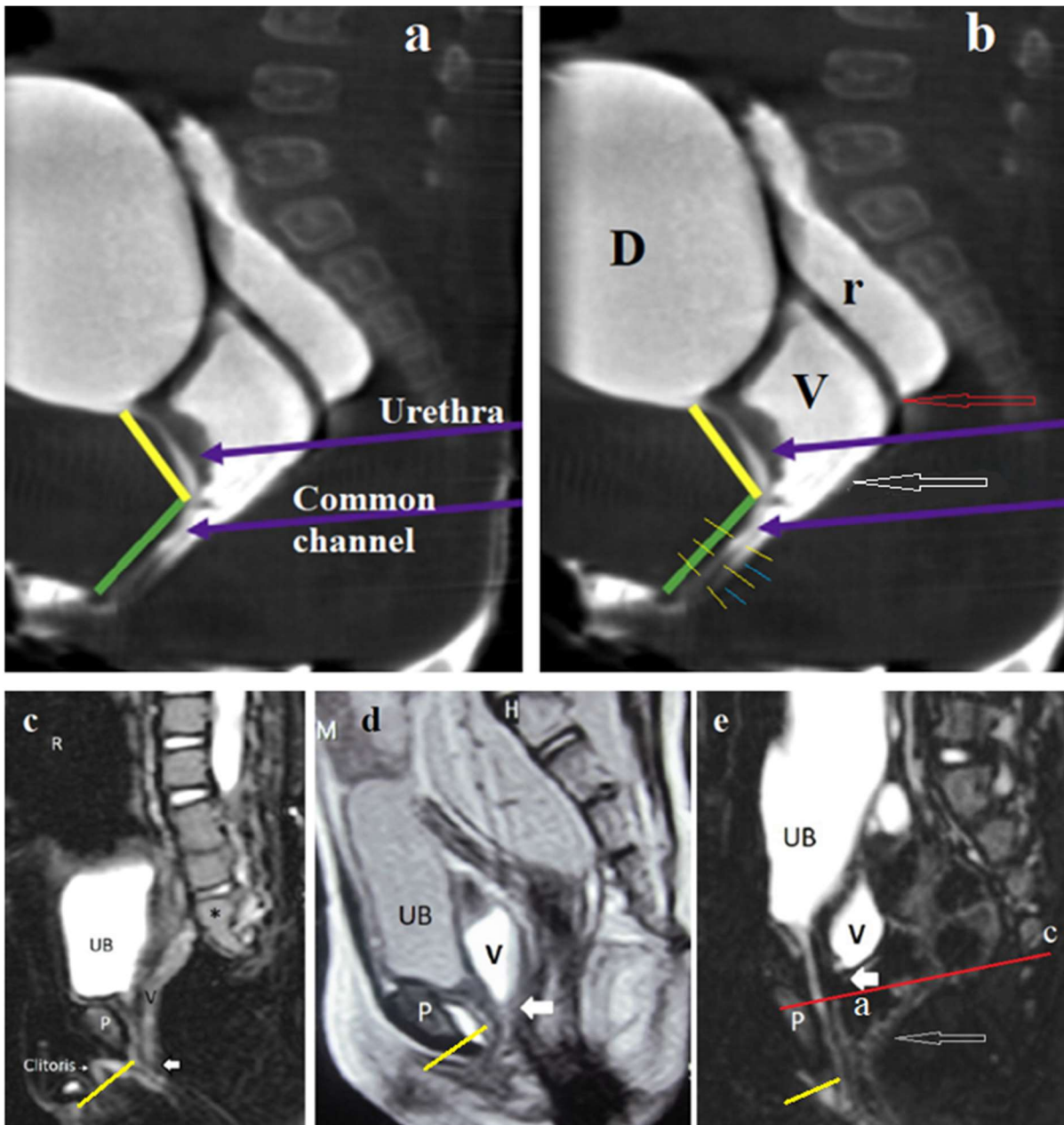


Figure 6. Radiographic anatomy of persistent cloaca. **(a)** MRI study from the article by Wood et al. [32], with the caption "Short common channel cloaca with adequate urethra." The authors suggest that, in the angle between the yellow and green lines, the urethra merges with the vagina to form a common channel. In the copy of the same image **(b)** I have shown the presence of two channels: between the yellow lines, you can see the continuation of the urethra up to the perineum, and next to it, the blue lines indicate the narrow vaginal canal. Between them, a dark dividing line can be observed, representing the fusion of the walls of the urethra and vagina. The upper part of the vagina (V) is dilated (hydrocolpos). The red arrow points to a rectum above the anal canal. The white arrow indicates at the site of the anal ectopy into the vagina. The contracted short anal canal is visible between the red and white arrows. The site of IAS

penetration into the vagina divides the vagina into an upper, widened part and a lower, narrow part. However, the urethra is of normal length and extends to the perineum. (c, d, e) From the article by AbouZeid with the caption "MRI stratification of cloaca based on the level of the urogenital confluence (white arrow)" [22]. I have indicated the urethra with yellow lines. (c) The urethra and narrow vagina run parallel up to the perineum, where the clitoris is located. There is no fusion of the urethra and vagina. (d) The white arrow does not indicate the site of confluence but rather the site of vaginal obstruction, above which hydrocolpos is observed. (e) The white arrow shows the site of vaginal obstruction, above which hydrocolpos is observed. The yellow line shows a long and normally positioned urethra. Gas is visible in the rectum, which is also present in the upper part of the anal canal (a) (arrow).

The interpretation of these cases by the authors of the articles was influenced by the erroneous concept of the possibility of already formed canals merging into one common channel. Because of this misconception, the authors overlooked the actual anatomical features, mistaking the site of vaginal obstruction for the site of merging. Consequently, clear signs of a normal urethral position were ignored. In case (e), the presence of gas in the anal canal was not mentioned.

Based on the known clinical, embryological, and anatomical studies, it can be hypothesized that vaginal obstruction occurs at the site where the IAS penetrates the vagina. Additionally, as shown in cases (a, e), some patients with vaginal fistulas have a formed anal canal. The presence of the anal canal was not proven in cases (c, d); however, this does not exclude its absence, as conditions for its detection were not created (e.g., creating high pressure in the rectum by compressing the abdomen during fluoroscopy [7, 14, 33]).

Our hypothesis is based on evidence that the so-called persistent cloaca develops in the post-cloacal period, when the fusion of already formed canals is impossible and is not supported by radiological examinations. This is further corroborated by the absence of the anus due to the pathology of ectodermal development. High ectopy of the IAS in females is likely only because of penetration of the vaginal wall. Using the example of a long narrow channel with a penile fistula in males, it can be assumed that such a fistula tract could occur in the vagina if, by the time of IAS penetration, a cavity had not yet formed in the vagina (**Figure 7**).

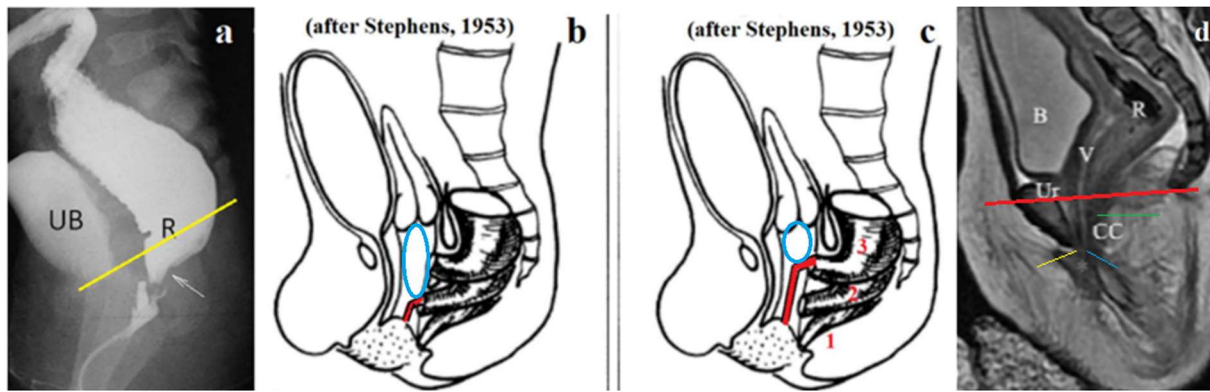


Figure 7. Variants of ARMs with fistulas in the vagina. **(a)** The contrast agent injected through the colostomy penetrates from the rectum (R) to a narrow, uneven channel. The sigmoid colon is narrow, indicating low rectal pressure. The intestine located below the pubococcygeal line (p-c) is the anal canal. The arrow indicates the concavity created by the contracted PRM. The urethra is not visible, as it is in a contracted state, which is normal. **(b-c)** On the diagram of fistula locations in girls, proposed by Stephens (1-vestibular; 2-vaginal low; 3-vaginal high), I have drawn a channel in red, which is created by the IAS in the vagina in cases where an internal cavity has not yet developed. The blue oval shows the location of the hydrocolpos above the site of the IAS ectopy, where the release of fluid from the upper part of the vagina is blocked. **(d)** A case described as "persistent cloaca" by Lin et al., with the caption: "Sagittal MRI of the lower abdomen showed the rectum (R), vagina (V), uterus (Ut), bladder (B), urethra (Ur), and ill-defined common channel (CC)" [34]. The cross-section shows a normal-length urethra with an external opening in the vulva (yellow line). The vagina appears to be a narrow long channel (blue line), and there are no signs of a common channel. This is a typical case of a vaginal fistula with an unusually narrow canal in the vagina. The contracted anal canal is shown as a green line.

All vaginal fistulas form in the post-cloacal period when the IAS, having reached the subcutaneous tissue opposite the anal fossa, and without encountering the ectodermal part of the anal canal, continues to migrate forward and upward. The anterior displacement of the anus always occurs exactly in the projection of the sagittal plane. No observations have described the IAS passing by the urethra. In females, the fistula cannot penetrate the urethra since the vagina is in its path. In cases where the IAS penetrates the vaginal cavity, a typical vaginal fistula occurs (see Figure 4c).

My hypothesis suggests that during ectopy of the IAS into the vagina, in most cases, the internal channel in the vagina has not yet formed. Therefore, the IAS behaves similarly to how it does in males with a penile fistula. It creates a narrow and rigid fistula in the center of the vagina, which in some cases blocks the exit of the liquid from the proximal vagina, leading to hydrocolpos. This canal can be short if the IAS has penetrated the lower vagina (Figure 7b) or long (Figure 7c). Additionally, as shown above (Figures 6e, 7a, d), these patients may have a formed anal canal. A special examination is necessary in each case to confirm the presence of an anal canal.

4. Atresia and stenosis of the anal canal, not the rectum.

We were able to find in the open access 14 x-ray studies of rectal atresia or stenosis. In 8 cases, radiometric analysis showed that atresia or stenosis was in the anal canal approximately 1 cm from the anal verge in the form of a membrane. An example is the case report described by Stenström et al (**Figure 8**) [35].

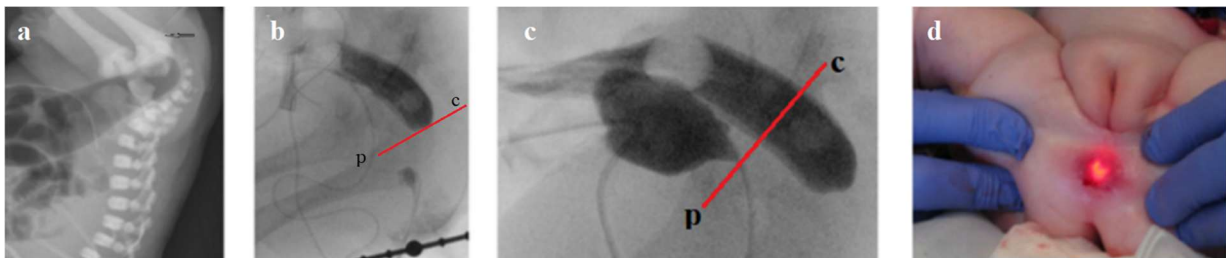


Figure 8. (a) X-ray of the abdomen at 24 hours of age. The distal bowel with gas is at the level of the pubococcygeal line, i.e., in the rectum. The black arrow shows the tip of the probe inserted into the anus until it stops, indicating that the atresia is in the anal canal. (b) The contrast agent, injected through the colostomy as in (a), is visible in the rectum. (c) During a combination of high-pressure colostogram and contrast in the urinary bladder, the upper part of the anal canal distal to the pubococcygeal line (drawn by me) opened widely. (d) "The endoscope was pressed against the rectal atresia, and with the help of external pressure, the endoscope could be seen 1 cm up in the anal canal" [35].

In 6 cases, gas or contrast medium was in the rectum at the level of the pubococcygeal line, as high pressure was not created during the examination to open the anal canal. Although we were unable to localize the site of atresia or stenosis, these data were sufficient to conclude that the pathology was located not in the rectum but in the anal canal [36,37].

From a clinical perspective, this analysis shows that the membrane is accessible for removal through the anus, allowing for the preservation of the anal canal, as was done in the case

described by Stenström et al. [36]. The location of the membrane corresponds to the junction of the endodermal and ectodermal primordia of the IAC and coincides with the location of the anal membrane in the embryonic period. Normally, according to Nobles (1984), the anal membrane ruptures during embryos with a length of 13.5-135 cm [38]. Probably, the disruption of the rupture of the anal membrane during the embryonic period leads to atresia or stenosis of the anal canal.

5. The so-called H-type anorectal malformations

Patients who have a congenital rectourogenital connection and an external anal opening in a normal or ectopic position are considered to have an H-type malformation [38]. In a systematic review by Sharma and Gupta the reported incidence is 1-16% of all ARMs [39]. The European Anorectal Malformation Network (ARM-Net) found it in 0.5% of cases based on 10-year registration [28]. Lawal et al described 8 (0.7%) of 1170 females (1 day to 10 years) [40]. The H-type is 2,5-6 times more common in females [1,2]. In infants, it is diagnosed by the presence of meconium dots/streak on the perineum, in the vestibule of the vagina, or traces of meconium in the urine. Less frequently, the diagnosis was made due to frequent urinary tract infections before the age of 10 years [4]. H-type fistula should be suspected when there is a labial abscess and congenital fistula between labium/vulva and the anus [40, 41, 42,43]. Some authors describe only cases with the location of the fistula opening in the anal canal above or at the level of the dentate line [40, 41, 43, 44, 45,46]. For example, Li et al reported that “In all cases, the internal orifice opened above the dentate line” [46]. According to the Wingspread classification, H-type fistulas were divided into three groups according to their level. Low type double termination included cases in which the fistula was lying between the anal canal and the vestibule, and this was named as “perineal canal”. In the intermediate type, communication was found between the rectum and the vestibule. High type of double termination consisted of a fistula between the rectum and the vagina [citation 4]. In males, the H-type is described not only with perineal ectopia of the anus, but also with urethral ectopia of different levels. For example, Rintala et al described three males who had a rectourethral H fistula and two males had a rectovesical H fistula [38].

5.1. Perineal photos with H-type ARM

When surgeons write about a normal anus or rectum in H-type ARM, they usually mean that it is open for bowel movements. However, in a study by Lawal et al, anal stenosis (caliber smaller than a size 9 Hegar dilator) was found in 3 of 8 patients [40].

In the available literature, I found 7 images of the perineum of patients with low H-type ARM. As an example of the norm, the image from the article by Amerstorfer et al [13] is taken (**Figure 9 a**).

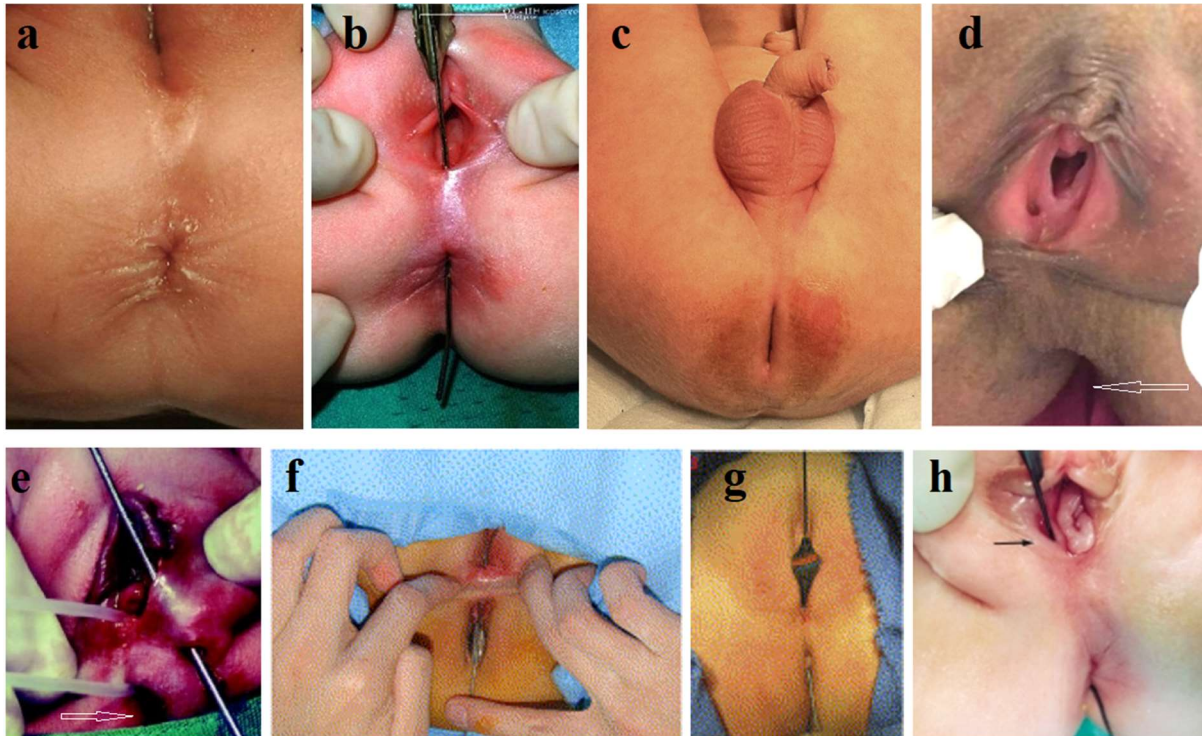


Figure 9. Perineal images of patients with H-type ARM. **(a)** Norma [13]. Skin folds on both sides of the closed anus due to contraction of the subcutaneous portion of the external anal sphincter (EAS). **(b)** Anovestibular fistula from the article by Sanal [48]. Funnel-shaped deepening. **(c)** From the article by Slater et al [49]. Longitudinal cleft with no signs of EAS contraction. **(d)** From the article by Manjiri et al [41]. Perineal canal with anolabial fistula. Deep funnel instead of normal anus (arrow). **(e)** From the article by Yazlcl et al [50]. A light probe was pulled through the anovestibular fistula. The arrow shows the gaping anus. A metal sound was inserted through the left opening, and it was found that it had a subcutaneous continuity with a vulvar abscess. **(f)** From the article by Park [51]. Longitudinal gaping slit instead of anus. Catheter is pulled through anovestibular fistula. **(g)** From the article by Lawal et al [40]. Longitudinal slit without signs of contraction of the EAS. **(h)** From the article by Lee et al [52]. Oblique image shows a longitudinal, although not long, slit. A histological study in all 3 cases revealed squamous epithelium in the wall of the fistula [52].

5.2. Radiological study (Figure 10). An article by Slater et al shows the possibilities of radiographic examination [49]. The newborn male had passed meconium in the first 24 h of life, but on exam was noted to have a slit-like anus (See Figure 9 c).

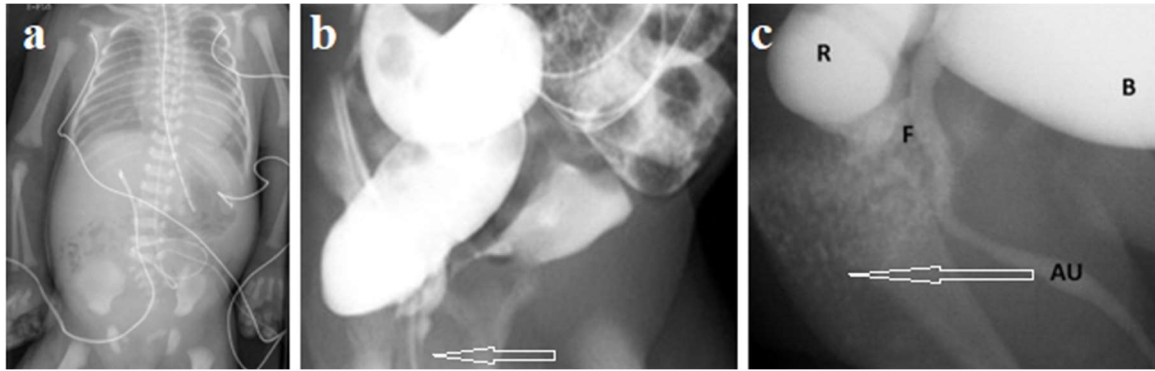


Figure 10. (a) Despite the anal stenosis (the anal opening was patent but admitted only a 9 mm Hegar dilator), the plain radiograph shows that bowel movement was not difficult. An X-ray examination was performed, since particulate matter was also found in the urine. (b) During barium enema the ano-urethral fistula, described as a colourethral fistula, was found. The anal canal is in a contracted state (arrow). (c) Pre-operative voiding cystourethrogram demonstrating colourethral fistula. Contrast medium diluted with urine is seen in the widely open anal canal (arrow). During posterior sagittal anorectoplasty (PSARP), a "quite large and patulous" prostatic fistula was found.

5.3. Analysis of results

As shown above, all types of ARMs, except for the true cloaca, represent ectopia of the anus due to impaired development of the ectodermal rudiment of the anal canal. They are characterized by the presence of a functional anal canal.

H-type ARM differs from the above-described situation by: (1) The damage to anus with frequent presence of stenosis; (2) a slit-like or funnel anus without skin folds on both sides indicate the absence of the subcutaneous part of the EAS. (c) The combination with anolabial fistula and labial abscess, which indicates an unusual pathology of exogenous origin, since not all types of ARMs never shift from the central sagittal plane. (d) The presence of a functioning anal canal with an opening (fistula) on the anterior wall of the anal canal at different distances from the edge of the anus (from the perineal ectopy to the upper third of the anal canal in vaginal ectopy and in ectopy in bladder-neck). (e) Significant predominance of females.

The embryology of this type of ARM can be presented as follows. Unusual damage to the exodermal rudiment of the anal canal leads to a slower formation of the anal canal to meet the endodermal rudiment. By this moment, the endodermal rudiment, not having met the

exodermal one in time, began to shift in search of an exit outward or into the cavity of some organ (**Figure 11**). When the damaged exogenous rudiment joins the endogenous one at the level of the dentate line, the distal third of the anal canal is always pathological, although passable for feces.

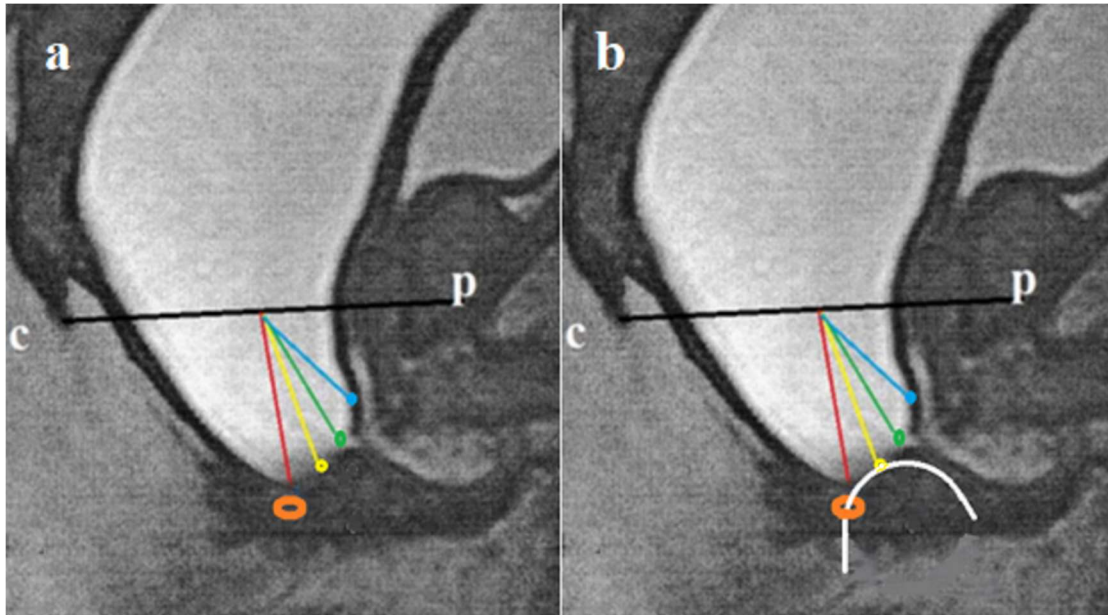


Figure 11. (a) For the diagram of possible variants of H-type ARM in males, a lateral anorectal CT with high-pressure contrast injection from a colostomy was used. High rectal pressure resulted in a wide opening of the anal canal below the pubococcygeal line. An anobulbar urethral fistula is visible as an opening in the anterior wall of the anal canal near the green dot. The distal wall of the anal canal is 2-4 mm from the anal verge, shown as an oval. The site in case of prostatic ectopy is shown in green, and perineal ectopy is shown in yellow. (b) Schematic diagram of ano-perineal ectopy. The catheter (white) inserted from the ectopic fistula (yellow) and comes out through the anus. At rest, when the anal canal is closed, the distance between the openings is smaller than in the diagram when the anal canal is wide open.

5. 4. The main changes in the understanding of the so-called H-type ARM.

Analysis of the literature shows that:

1. There is reason to believe that this type of ARM develops in the embryonic period because of a developmental disorder of the exodermal rudiment of the anal canal. This leads to a delayed formation of the distal third of the anal canal. Therefore, the endodermal rudiment, not having met the ectodermal one on its way, shifts forward and

upward, creating all types of ectopia of the anus. So far, this is the only hypothesis that does not contradict scientific facts.

2. The anatomy of the defect does not correspond to its name, since the ectopic anus is an opening on the anterior wall of the anal canal, and not a canal between two openings.
3. To treat this type of ARM, it is necessary to block the opening. Since the length of the anal canal in a newborn is 1.7 cm [7], this means that the highest ectopia (cervico-urinary bladder) is no more than 1.5 cm from the anal verge and is accessible for blocking from the anal approach.
4. According to the embryology and anatomy of the defect, the correct diagnosis is - ectopy of the anus without an imperforate anus. In each case, the place of penetration is added - perineal, vestibular, vaginal, urethral: bulbar, prostatic or neck-bladder. Such a clarification as anovestibular fistula is correct, but does not make sense, since all options are at the level of the anal canal. The distal third of the anal canal is always pathological, so calling the anal canal normal on the basis that it is open is a mistake.

5. Classification of ARMs

The Wingspread classification (1984) defined perineal and vestibular ARMs as low types in which there is an anal canal that must be preserved to obtain better functional results. The cutback procedure was widely used for this purpose.

The Krickenbeck classification (2005) was proposed by Peña and was adopted with the help of specially selected pediatric surgeons who had no experience with ARMs. Despite the known indisputable scientific evidence, they rejected the idea of the existence of an anal canal and recommended performing posterior sagittal anorectoplasty in all cases of ARM, which is supposedly the ideal operation, although in fact it destroys the anal canal and causes severe complications (fecal incontinence, severe chronic constipation, sexual and urological problems).

Since then, despite the resistance of Peña and his followers, it has been established that the anal canal is present in almost all ARMs. And the distal portion of the intestine that was removed under the names of the fistula or rectal pouch is a functioning anal canal.

Based on modern concepts of normal anatomy and physiology of the anorectum, as well as pathological anatomy and physiology of ARM, I propose a classification that facilitates the diagnosis and treatment of ARM (**Table 1**).

Table 1. Classification of anorectal malformations

Females	Congenital stenosis of the anus	Males
	Ectopy of the anus:	
Perineal	With visible fistula	Perineal
Vestibular		
Vaginal	Without visible fistula	Bulbar
Wide vagina (low or high)		Prostatic
Narrow vagina (low or high)	All types of anal ectopy with open anal canal	Neck - bladder
	Atresia (stenosis) of the anal canal	
	True cloaca	
	Other	

Explanations

1. The names should correspond to the embryology, anatomy and physiology of the defect and not be ambiguous. For example, by “congenital anal stenosis” many pediatric surgeons refer to stenosis of the anal canal. Based on this, they remove the internal anal sphincter and destroy the anal canal. However, the anal canal in these patients is normally developed. The narrow rigid canal in newborns and children of the first year of life occupies only 2-4 mm from the anal canal to the anal dimple and its length depends only on the thickness of the skin and subcutaneous tissue. Simple dissection of stenosis will preserve the anal canal. The correct diagnosis is “Congenital stenosis of the anus”.

2. The names “Rectourethral fistula” or “rectovaginal fistula” et al, erroneously imply that between the rectum and the anal dimple there is a fistula or rectal pouch, which contradicts manometric, radiological, histological and embryological scientific evidence. Based on this misconception, surgeons destroy the anal canal created by nature instead of preserving it. The correct diagnosis is “Ectopy of the anus”. But not anal ectopia, since the anal canal is in place.

3. Most urethral fistulas are very narrow and do not function. If there are no signs of meconium in the urine and gas does not disappear into the urinary tract during abdominal compression, this means that the fistula is not functioning, so there is no point in distinguishing separately "ARM without fistula". Diagnostic methods allow us to accurately divide fistulas into functioning and non-functioning. The colonography, which is performed at high hydrodynamic pressure, cannot be used, since, firstly, it is dangerous due to the possibility of intestinal perforation. If low pressure is used, it does not bring any benefit. Secondly, high

pressure can turn a non-functioning fistula into a functioning one, which leads to more difficult surgical manipulations. A multi-country analysis showed that "The first week mortality proportion was 12.5%, 3.2%, 28.3%, and 18.2% among all, isolated, multiple, and syndromic cases, respectively" [53]. It is obvious that the less surgical trauma, the greater the chances of survival of the newborn. In this sense, the cutback procedure has an advantage over the pull-through, regardless of the access.

4. If women have a urethra and an anal canal, then a narrow vagina is not a common canal, and the pathology is not "Persistent cloaca". This is anovaginal ectopy with a narrow vagina.
5. The defect that was considered atresia or stenosis of the rectum is in the anal canal at 1 cm from the anal verge [5]. It should be called atresia/stenosis of the anal canal. Removal of the membrane is available from the anal approach, because of which the anal canal is preserved, and the operation is better tolerated by patients.
6. The defect that was called "H-type ARM" is different types of ectopy of the anus with an open anal canal. This anal canal is not normal, as some authors write.

References

1. Alamo L, Meyrat BJ, Meuwly JY, et al. Anorectal Malformations: Finding the Pathway out of the Labyrinth. *Radiographics*. Mar-Apr 2013;33(2):491-512. doi: 10.1148/rg.332125046.
2. Kluth D. Embryology of anorectal malformations. *Semin Pediatr Surg*. 2010 Aug;19(3):201-8. doi: 10.1053/j.sempedsurg.2010.03.005.
3. Gupta A, Bischoff A, Peña A, et al. The great divide: septation and malformation of the cloaca, and its implications for surgeons. *Pediatr Surg Int*. 2014 Nov;30(11):1089-95. doi: 10.1007/s00383-014-3593-8.
4. Anatomy and Embryology of the Colon, Rectum, and Anus José Marcio Neves Jorge and Angelita Habr-Gama . In book: *The ASCRS Textbook of Colon and Rectal Surgery* (pp.1-22).
5. Zhang SW, Bai YZ, Zhang D, et al. Embryonic development of the internal anal sphincter in rats with anorectal malformations. *J Pediatr Surg*. 2010 Nov;45(11):2195-202. doi: 10.1016/j.jpedsurg.2010.06.020.
6. *Coloproctology and the pelvic floor*. Edited by M. M.Henry and M. Swash. Butterworths. 1985. (Nobles VP. The development of the human anal canal. *Journal of Anatomy*, 1984, 138, 573).

7. Levin MD. Anatomy and physiology of anorectum: the hypothesis of fecal retention, and defecation. *Pelvipерineology* 2021;40(1):50-57. DOI: 10.34057/PPj.2021.40.01.008 (Open access).
8. Levin MD. The pathological physiology of the anorectal defects, from the new concept to the new treatment. *Eksp Klin Gastroenterol.* 2013; (11):38-48.
9. Kyrklund, K., Pakarinen, M. P., Taskinen, S., & Rintala, R. J. (2015). Bowel function and lower urinary tract symptoms in males with low anorectal malformations: An update of controlled, long-term outcomes. *International Journal of Colorectal Disease*, 30(2), 221-228. <https://doi.org/10.1007/s00384-014-2074-9>.
10. Ruttenstock EM, Zani A, Huber-Zeyringer A, Höllwarth ME. Preand postoperative rectal manometric assessment of patients with anorectal malformations: should we preserve the fistula? *Dis Colon Rectum.* 2013 Apr;56(4):499-504. <https://doi.org/10.1097/DCR.0b013e31826e4a38>.
11. Sfoungaris D, Mouravas V, Lambropoulos V, Kepertis C, Spyridakis I. Imperforate Anus with Fistula Exiting at the Penile Skin. *J Clin Diagn Res.* 2016 Mar;10(3):PD01-2. <https://doi.org/10.7860/JCDR/2016/17730.7334>.
12. Yang G, Wang Y, Jiang X. Imperforate anus with rectopenile fistula: a case report and systematic review of the literature. *BMC Pediatr.* 2016 May 13;16:65. doi: 10.1186/s12887-016-0604-z.
13. Amerstorfer, E. E., Schmiedeke, E., Samuk, I., Sloots, C. E. J., van Rooij, I. A. L. M., Jenetzky, E., ... & Arm-Net Consortium. (2022). Clinical Differentiation between a Normal Anus, Anterior Anus, Congenital Anal Stenosis, and Perineal Fistula: Definitions and Consequences-The ARM-Net Consortium Consensus. *Children (Basel)*, 9(6), 831. <https://doi.org/10.3390/children9060831>.
14. Levin MD, Averin VI, Degtyarev Y.G. Pathological physiology of anorectal malformations (ARM) without visible fistulas. Review. *Novosti Chirurgii (Belarus)* 2022; 30(3): 105-12. <https://doi.org/10.18484/2305-0047.2022.3.298>.
15. Ohama K, Asano S, Nanbu K, Kajimoto T. The internal anal sphincter in anorectal malformation. *Z Kinderchir.* 1990 Jun;45(3):167-77. doi: 10.1055/s-2008-1042575.
16. Huang X, Chen Y, Pang W, Peng C, Wu D. Transanal fistulectomy for postoperative persistent rectourethral fistula in patients with ARM: is simple resection enough? *BMC Surg.* 2021 Apr 2;21(1):179. doi: 10.1186/s12893-021-01186-3.
17. Kraus SJ, Levitt MA, Peña A. Augmented-pressure distal colostogram: the most important diagnostic tool for planning definitive surgical repair of anorectal

- malformations in boys. *Pediatr Radiol*. 2018 Feb;48(2):258-269. doi: 10.1007/s00247-017-3962-2.
18. Hendren WH. Urogenital sinus and anorectal malformation: experience with 22 cases. *J Pediatr Surg*. 1980; 15: 628-641 [https://doi.org/10.1016/s0022-3468\(80\)80514-8](https://doi.org/10.1016/s0022-3468(80)80514-8)gbcfl
 19. Hendren WH. Repair of cloacal anomalies: current techniques. *J Pediatr Surg*. 1986 Dec;21(12):1159-76. doi: 10.1016/0022-3468(86)90032-1.
 20. Versteegh HP, van Rooij IA, Levitt MA, Sloots CE, Wijnen RM, de Blaauw I. Long-term follow-up of functional outcome in patients with a cloacal malformation: a systematic review. *J Pediatr Surg*. 2013 Nov;48(11):2343-50. doi: 10.1016/j.jpedsurg.2013.08.027.
 21. Kittur DH and Vora RM. Persistent Cloaca: A Long-term Follow-up Study. *J Indian Assoc Pediatr Surg*. 2017 Apr-Jun; 22(2): 126–127. doi: 10.4103/0971-9261.202685
 22. AbouZeid AA. Achieving Full Anatomical Correction in Girls with cloacal anomalies: A Necessity or an Overdoing? *The Journal of Genital Surgery*. 2019. Jan; 8(1): 1-10. https://jgs.journals.ekb.eg/article_31544.html.
 23. Peña A. Total urogenital mobilization--an easier way to repair cloacas. *J Pediatr Surg*. 1997 Feb;32(2):263-7; discussion 267-8. doi:10.1016/s0022-3468(97)90191-3.
 24. Runck LA, Method A, Bischoff A, et al. Defining the molecular pathologies in cloaca malformation: similarities between mouse and 14 human. *Dis Model Mech*. 2014 Apr; 7(4): 483–493. doi: 10.1242/dmm.014530.
 25. Rosen NG, Hong AR, Soffer SZ, Rodriguez G, Peña A. Rectovaginal fistula: a common diagnostic error with significant consequences in girls with anorectal malformations. *J Pediatr Surg*. 2002 Jul;37(7):961-5; discussion 961-5. doi: 10.1053/jpsu.2002.33816.
 26. de Blaauw I, Wijers CH, Schmiedeke E, Holland-Cunz S, Gamba P, Marcelis CL, Reutter H, Aminoff D, Schipper M, Schwarzer N, Grasshoff-Derr S, Midrio P, Jenetzky E, van Rooij IA. First results of a European multi-center registry of patients with anorectal malformations. *J Pediatr Surg*. 2013 Dec;48(12):2530-5. doi: 10.1016/j.jpedsurg.2013.07.022.
 27. de Beaufort CMC, Gorter RR, Iacobelli BD, Midrio P, Sloots CEJ, Samuk I, van Rooij IALM, Lisi G; ARM-Net Consortium. Rectal atresia and rectal stenosis: the ARM-Net Consortium experience. *Pediatr Surg Int*. 2023 Jul 28;39(1):242. doi: 10.1007/s00383-023-05518-7.

28. Hageman IC, Midrio P, van der Steeg HJJ, et al; ARM-Net Consortium. The European Anorectal Malformation Network (ARM-Net) patient registry: 10-year review of clinical and surgical characteristics. *Br J Surg*. 2024 Jan 31;111(2):znae019. doi: 10.1093/bjs/znae019. PMID: 38364059; PMCID: PMC10870250.
29. Peña A, Devries PA. Posterior sagittal anorectoplasty: important technical considerations and new applications. *J Pediatr Surg*. 1982 Dec;17(6):796-811. doi: 10.1016/s0022-3468(82)80448-x. PMID: 6761417.
30. Okonkwo JE, Crocker KM. Cloacal dysgenesis. *Obstet Gynecol*. 1977 Jul;50(1):97-101.
31. deVries PA, Peña A. Posterior sagittal anorectoplasty. *J Pediatr Surg*. 1982 Oct;17(5):638-43. doi: 10.1016/s0022-3468(82)80126-7.
32. Wood RJ, Reck-Burneo CA, Dajusta D, Ching C, Jayanthi R, Bates DG, Fuchs ME, McCracken K, Hewitt G, Levitt MA. Cloaca reconstruction: a new algorithm which considers the role of urethral length in determining surgical planning. *J Pediatr Surg*. 2017 Oct 12:S0022-3468(17)30644-9. doi: 10.1016/j.jpedsurg.2017.10.022. Epub ahead of print. Erratum in: *J Pediatr Surg*. 2018 Mar;53(3):582-583. doi: 10.1016/j.jpedsurg.2018.02.051.
33. Levin MD. Pathological physiology of the anorectal malformations without visible fistula. A short review. *Pelvipерineology* 2023;42(2):74-79. DOI: 10.34057/PPj.2022.41.02.2021-9-1.
34. Lin X, Xu X, Yang Y, Wu J, Xian X, Chen X. Preoperative evaluation of persistent cloaca using contrast-enhanced ultrasound in an infant. *Med Ultrason*. 2020 May 11;22(2):250-252. doi: 10.11152/mu-2039.
35. Stenström P, Clementson Kockum C, Arnbjörnsson E. Rectal atresia-operative management with endoscopy and transanal approach: a case report. *Minim Invasive Surg*. 2011;2011:792402. doi: 10.1155/2011/792402.
36. Levin MD. X-ray analysis of published studies of rectal atresia. Review. chrome-extension://efaidnbmnnnibpcajpcglclefindmkaj/https://www.anorectalmalformations.com/_files/ugd/4d1c1d_e299b7ebc8ce447daf57b3c0cd6423c5.pdf.
37. Levin MD, Averin VI, Degtyarev Yu.G. (2023) Diagnosis and Treatment of the Rectal Atresia. *Novosti Khirurgii*. Oct-Dec; vol 31(6)468-477. DOI: <https://dx.doi.org/10.18484/2305-0047.2023.6.468>

38. Rintala RJ, Mildh L, Lindahl H. H-type anorectal malformations: incidence and clinical characteristics. *J Pediatr Surg.* 1996 Apr;31(4):559-62. doi: 10.1016/s0022-3468(96)90496-0.
39. Sharma S, Gupta DK. Diversities of H-type anorectal malformation: a systematic review on a rare variant of the Krickenbeck classification. *Pediatr Surg Int.* 2017 Jan;33(1):3-13. doi: 10.1007/s00383-016-3982-2.
40. Lawal TA, Chatoorgoon K, Bischoff A, Peña A, Levitt MA. Management of H-type rectovestibular and rectovaginal fistulas. *J Pediatr Surg.* 2011 Jun;46(6):1226-30. doi: 10.1016/j.jpedsurg.2011.03.058.
41. Manjiri S, Shetty J, Padmalatha SK, et al. Perineal canal repair using modified Tsuchida's technique. *Annals of Pediatric Surgery* (2020) 16:15.
<https://doi.org/10.1186/s43159-020-00025-z>
42. Meyer T, Höcht B. Kongenitale anorektale H-Fisteln: Zwei Fallberichte [Congenital H-type anorectal fistula: two case reports]. *Klin Padiatr.* 2009 Jan-Feb;221(1):38-40. German. doi: 10.1055/s-2007-984373.
43. Lee YS, Chu SM, Luo CC, Hwang CS, Hsueh C. Anorectal-vestibular fistula without an imperforate anus in female infants: report of three cases. *Chang Gung Med J.* 2005 Jun;28(6):421-4.
44. Banu T, Hoque M, Laila K, Ashraf-Ul-Huq, Hanif A. Management of male H-type anorectal malformations. *Pediatr Surg Int.* 2009 Oct;25(10):857-61. doi: 10.1007/s00383-009-2433-8. PMID: 19662429.
45. Akhparov NN, Aipov RR, Ormantayev KS. The surgical treatment of H-fistula with normal anus in girls. *Pediatr Surg Int.* 2008 Nov;24(11):1207-10. doi: 10.1007/s00383-008-2234-5.
46. Li L, Zhang TC, Zhou CB, Pang WB, Chen YJ, Zhang JZ. Rectovestibular fistula with normal anus: a simple resection or an extensive perineal dissection? *J Pediatr Surg.* 2010 Mar;45(3):519-24. doi: 10.1016/j.jpedsurg.2009.08.010.
47. Kulshrestha S, Kulshrestha M, Prakash G, Gangopadhyay AN, Sarkar B. Management of congenital and acquired H-type anorectal fistulae in girls by anterior sagittal anorectovaginoplasty. *J Pediatr Surg.* 1998 Aug;33(8):1224-8. doi: 10.1016/s0022-3468(98)90155-5.
48. Sanal M. Excision of an Anovestibular Fistula with a Normal Anus Using a Biopsy Punch. *Case Rep Surg.* 2022 Apr 16;2022:4348806. doi: 10.1155/2022/4348806.

49. Slater BJ, Fallon SC, Brandt ML, Lopez ME. H-type anorectal malformation: Case report and review of the literature. *J Ped Surg Case Reports* 2 (2014) 89-92. <http://dx.doi.org/10.1016/j.epsc.2014.02.001>
50. Yazlcl M, Etensel B, Gürsoy H, Ozklsaclk S. Congenital H-type anovestibuler fistula. *World J Gastroenterol*. 2003 Apr;9(4):881-2. doi: 10.3748/wjg.v9.i4.881.
51. Park J. Use of an endorectal mucosal advancement flap to treat H-type rectovestibular fistula in patients with a normal anus. *J Pediatr Surg*. 2013 Jan;48(1):247-50. doi: 10.1016/j.jpedsurg.2012.10.046. PMID: 23331824.
52. Lee YS, Chu SM, Luo CC, Hwang CS, Hsueh C. Anorectal-vestibular fistula without an imperforate anus in female infants: report of three cases. *Chang Gung Med J*. 2005 Jun;28(6):421-4.
53. Kancherla V, Sundar M, Tandaki L, et al. Prevalence and mortality among children with anorectal malformation: A multi-country analysis. *Birth Defects Res*. 2023 Feb 1;115(3):390-404. doi: 10.1002/bdr2.2129.