

Pathophysiology and diagnosis of descending perineum syndrome in children

MICHAEL D. LEVIN

State Geriatric Center, Netanya, Israel

Abstract: The purpose of this study is to offer a safe, simple and accurate method for diagnosing descended perineum syndrome (DPS). **Methods:** 194 patients aged from five days to 15 years were surveyed in the Belarusian Center of Pediatric Surgery. They were divided into two groups. In the 1st group were 65 patients without abnormalities of the anorectal area. In the 2nd group were 129 patients, including 66 children with functional constipation, 55 children with anorectal malformations (ARM) with visible fistulas that were examined before surgery, and 8 patients with ARM investigated after surgery. All patients underwent barium enema, which differed from the standard study by the presence of a radiopaque marker placed near the anus. **Results and Conclusion:** DPS is caused by damage to the muscles and ligaments of the pelvic floor. A method of assessing DPS is proposed on the basis of changes in the distance between the anorectal angle and the marker near the anus. Administering a barium enema with a minimum of radiographs dramatically reduces the dose of ionizing radiation compared with defecography and contributes to a more accurate assessment of DPS not only for adults, but also for children with chronic constipation, fecal incontinence and ARM, both before and after surgery, allowing assessment of the causes of complications.

Keywords: Barium enema; Chronic constipation; Descending perineum syndrome; Defecography; Fecal incontinence; Puborectalis muscle.

INTRODUCTION

The term “descending perineum” or “pelvic floor descent” is used in two very different conditions of the anorectal region. It was first applied by Parks et al, describing normal defecation during defecography. When defecation takes place there is an increase in the anorectal angle and the “descent” of barium from the rectum to the anus. Parks et al also described a “syndrome of the descending perineum”, which is defined as a pathological condition detectable during defecography. In these cases the anorectal angle increases and descends caudal to the pubococcygeal line¹. The etiology of descending perineum syndrome (DPS) is unclear². Defecography is considered the gold standard for identifying DPS, but in recent years dynamic magnetic resonance imaging has increasingly been used for this purpose³.

Parks et al believed that the cause of increased perineal descent is excessive straining upon defecation, causing the anterior wall to protrude towards the anal canal, in turn inducing incomplete defecation and weakness of the pelvic floor muscles⁴. Other authors have noted that abnormal descent of the perineum not only causes constipation, but also frequently causes fecal incontinence, anal pain, and other symptoms⁵. Defecography has two major disadvantages. First, it is associated with a high dose of ionizing radiation, which is unacceptable for the examination of children and patients of childbearing age. Secondly, the measurement of the anorectal angle or perineal descent with defecography has poor reproducibility, and differences exist between examiners².

The purpose of this study is to offer a safe, simple and accurate method of diagnosing DPS.

METHOD

Patients aged from five days to 15 years were divided into two groups. In the 1st group were 65 patients with complaints of abdominal pain, or where there was a suspicion of space-occupying lesions in the abdomen. Pathology of the colon and anorectal area was excluded by barium enema and proctoscopy. The results of the survey in this group of patients were accepted as the norm. The second group consisted of 129 patients, including 66 patients aged from 11 months to 15 years with functional constipation. Hirschsprung’s disease was excluded on the basis of manometric and histochemical studies. This group also included 55 patients aged from 10 days to 12 years who were

examined before surgery and had anorectal malformations (ARM) with visible fistulas. Among them were seven boys. Perineal fistulas were found in six girls, and 42 patients had fistulas opening into the vestibula. 47 patients had chronic constipation, and fecal incontinence was noted in four cases. This group also included eight patients with APM, who were examined after surgery to determine the cause of chronic constipation and/or fecal incontinence.

BARIUM ENEMA

X-ray study. During barium enema a contrast medium was used to fill the colon at least up to the splenic flexure. A radiopaque marker of 1.6 cm diameter with a hole in the center was strung onto the tip of the enema. During the study, patients in the control group had the marker located in contact with the anus, and in patients of the second group with ARM it was located near the fistula. In addition, in children of the second group another radiopaque marker was glued to the place of EAS activity. In patients of the first group, on a lateral radiograph of the anorectal zone we measured the roentgen negative distance (RND) between the barium in the rectum (or anorectal angle) and the marker on the posterior contour of the tip of the enema, and the width of the rectum at the widest part of its vertical branch (Figure 1).

To determine the true anatomical size, all distances measured on radiographs were multiplied by the coefficient of the projection increase. The latter is the ratio of the true diameter of the marker (1.6 cm) to its size on the radiograph image.

The manometric study was carried out with the help of an endotracheal tube, without the use of a rectal balloon. This allowed detection of an inhibitory anorectal reflex in patients with ARM with visible fistulas and the performing of anorectal manometry during the barium enema⁴.

Statistical analysis was performed by the method of the Student’s t-test. Statistical significance was defined as $P < 0.05$.

RESULTS

First group. On lateral radiographs of the anorectal area the distance between the barium in the rectum and the marker near the anus (RND) increased from 1.7 cm in neonates to 3.9 cm in adolescents, and the width of the rectum increased from 1.3 to 4.6 cm (Table 1).

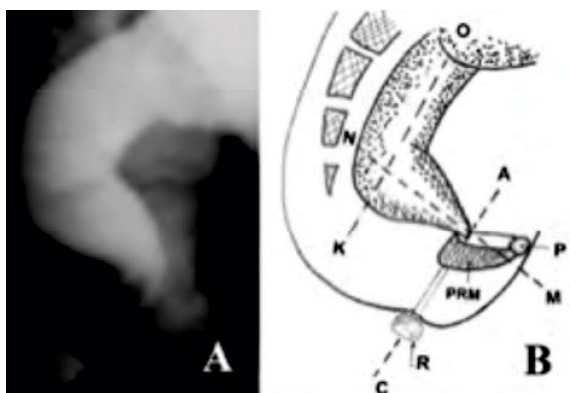


Figure 1. – Lateral x-ray image of the anorectal zone of a healthy child (A) and a schematic representation (B). The axis of the anal canal (AC) is displaced anteriorly from the axis of the vertical branch of the rectum (OK). NM – axis of the horizontal branch of the rectum; PRM – puborectal muscle, P – pubis, R – 1.6 cm diameter radiopaque marker in proximity of the anus. The distance between the rectum and the marker lying along the posterior contour of the tip is the length of the anal canal.

The RND is a zone of contraction of the muscles of the perineum, which prevents leakage of barium from the rectum. Its length is equal to the length of the anal canal according to the results of manometric studies^{5,6}. This proves that the RND is due to anal canal contraction.

Starting from the second half of the year, the caudal end of the rectum is bent forward, resulting in the formation of a horizontal branch of the rectum and an acute anorectal angle (ARA) between the rectum and the anal canal. Its proximal point, i.e. rectoanal compound is near the pubococcygial line. A caudal point, i.e. anus, is determined on the roentgenogram by the location of the marker contacting it. Thus, the RND between the rectum and the marker is an abridged anal canal, whose length represents the length of the anal canal.

The injection of air into the rectum through the endotracheal tube during manometric study caused a momentary decrease in anal pressure of 10-15 mm Hg, which was restored to baseline level within 7-15 seconds (a positive rectoanal inhibitory reflex). In 10 cases in which contrast agent was injected into the rectum during barium enema through the endotracheal tube of the manometric device, a transient penetration of contrast agent into the upper part of the anal canal in front of the enema tip was observed, while the posterior wall tightly pressed to the tip (Figure 2).

TABLE 1. The normal width of the rectum and anal canal length in children of differing ages add caption.

Age	Width of the rectum (cm)	Length of the anal canal (RND) (cm)
5 days - 11 months	n - 12	7
	1.3 – 3.0	1.7 – 2.5
	2.24±0.09	2.21±0.15
1-3 years	9	7
	3.0 – 3.7	2.3 – 2.8
	3.21±0.11	2.55±0.10
4-7 years	9	8
	3.0 – 3.9	2.5– 3.6
	3.43±0.14	3.17±0.14
8-10 years	9	8
	3.2 – 4.1	2.6 – 3.7
	3.72±0.05	3.11±0.10
11-15 years	19	18
	3.6 – 4.6	3.1 – 3.9
	3.95±0.07	3.43±0.10

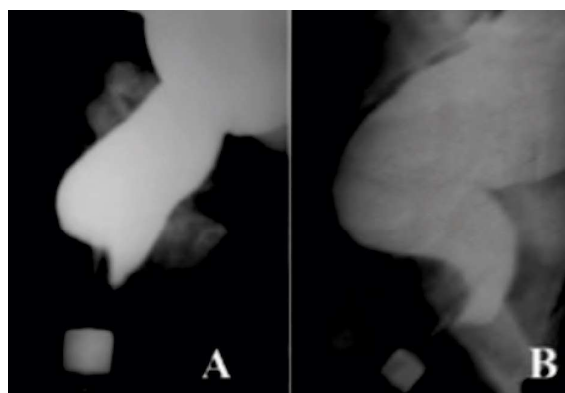


Figure 2. – Radiological representation of the rectoanal inhibitory reflex. Penetration of barium from the rectum into the upper part of the anal canal in front of the enema tip as a result of relaxation of the internal anal sphincter. The posterior wall of the anal canal at this level is pressed against the tip of the enema by the contracted Puborectalis muscle. A. four month old child. B. A 15 year old teenager.

This area occupies 40 to 50% of the entire length of the RND. Within a few seconds, the barium which penetrated into the anal canal returned to the rectum. In the process of the colon filling periodically (one to three times) penetration of contrast medium into the anal canal in front of the enema tip was observed. This lasted a few seconds each time before the barium disappeared from the anal canal. Appearance of barium in the anal canal is always accompanied by a decrease in anal pressure of 10-15 mmHg. When the barium disappeared from the anal canal, the pressure increased back to the basal level.

SECOND GROUP

In two of 66 patients with functional constipation who were surveyed in the first year of life, the width of the rectum was within normal limits. In four patients older than one year, the X-ray pattern did not differ from the norm. These were children with disease durations of less than six months, regularly receiving treatment (enemas and/or laxatives). In other cases a significant expansion of the rectum with respect to age norms was determined. The horizontal branch of the rectum on the lateral radiograph is not differentiated, due to the expansion anteriorly

TABLE 2. Size of the rectum and anal canal in 66 children with functional constipation. P – the reliability of the results compared to the standards in Table 1.

Age	Width of the rectum (cm)	Length of the anal canal (RND) (cm)
Up to 11 months	n - 2	1
	2.9	2.5
1-3 years	11	8
	2.9 – 4.8	2.2 – 3.7
	3.70+/- 0.17	3.09+/-0.15
P	< 0.02	< 0.05
4-7 years	18	8
	2.5 – 6.5	2.2 – 3.7
	4.68+/-0.20	3.17+/-0.14
P	< 0.001	> 0.2
8-10 years	25	22
	3.9 – 7.5	2.3 – 4.6
	5.14+/-0.18	3.21+/-0.12
P	< 0.001	> 0.2
11-15 years	9	9
	4.5 – 8.6	3.0 – 4.2
	5.90+/-0.38	3.44+/-0.15
P	< 0.001	> 0.2

of its vertical branch. Width of the rectum and RND length in different age groups are presented in Table 2.

X-ray study of the anorectal area in each case allows a fairly accurate determination of the function of the anal canal. Three stages of pathological change can be clearly distinguished. These follow one another, each with an increase in the degree of megarectum (Figure 3).

Only in 10 (20%) of 51 studies was the length of the RND within normal limits. In 14 (27%) patients it was longer than the maximum normal limit (Fig. 3, A). The lengthening of the RND can be explained by hypertrophy of the puborectalis muscle (PRM), whose increase in volume causes not only pressure on the posterior wall of the anal canal, but also the distal part of the rectum which pressed to the tip of the enema. Only in the initial stage of the disease, up to three years, is a significant ($P < 0.05$) elongation of the RND defined. In patients older than three years, the average length of the RND was in the normal range ($P > 0.2$), but individual values varied widely. In fifteen (29%) of 51 patients barium penetrated into the anal canal behind the enema tip (Figure 3, B), indicating a weakened PRM was unable to press the posterior wall of the anal canal to the enema tip. In 12 (24%) of the patients a significant shortening of the RND was determined compared to a normal length of the anal canal (Figure 3 C and D). This shortening was sometimes combined with an increase of ARA (Figure 3, B). In other cases, ARA was normal (Figure 3, D).

For babies up to nine months old, in ARM with fistulas on the perineum or vestibule the anorectal area before surgery differed from the norm by the presence of anterior displacement of the anus. The length of the RND between the ARA and a marker near the fistula, or a marker located near activity of the subcutaneous portion of the external anal sphincter, was equal to the length of the age norm of the anal canal ($P > 0.2$). In cases where it was possible to insert and keep the manometric device's endotracheal tube within the rectum, a rectoanal inhibitory reflex was detected. Radiological and manometric data confirmed histological and embryological studies of other authors that this pathology is anal ectopy. In children older than one year, expansion of the rectum occurs due to stenosis of the ectopic anus. This is accompanied by shortening of the RND between the ARA and the marker near the fistula. This process increases with age (Figure 4).

After endorectal pull-through (Figure 5, A) or posterior sagittal anorectoplasty (Figure 5, B) a significant (twofold or more) shortening of the RND was observed compared with the normal length of the anal canal. This was combined with expansion of the rectum beyond the maximum normal limit. In cases where the anal canal was used during surgery to reconstruct the ARM, the length of the anal canal was within normal limits (Figure 5, C).

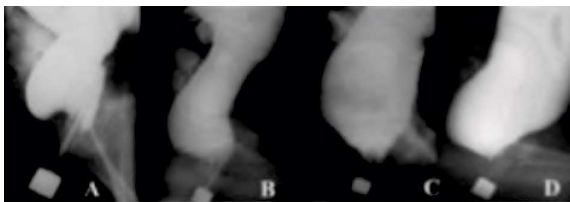


Figure 3. – Radiographs of the anorectal area of children with functional constipation. The true diameter of the marker is 1.6 cm. On all pictures the horizontal branch of the rectum is absent, as its vertical branch is greatly expanded compared to the age norm. A. The length of the RND is 3.5 cm (normal maximum length of the anal canal at the age of three years is 2.8 cm); B. The length of the anal canal is within the age limit, but barium penetrates into the anal canal behind the tip of the enema as a result of weakness of the PRM; C and D. Significant expansion of the rectum is combined with a sharp shortening of the anal canal and insufficiency of the PRM.

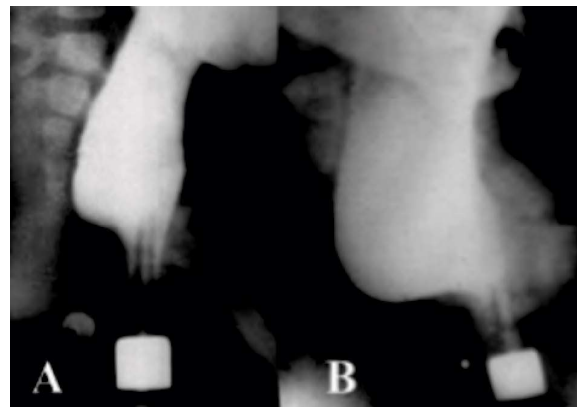


Figure 4. – Lateral radiographs of the anorectal area of the same patient with vestibular fistula. A. At the age of six months. Penetration of barium behind the tip of the enema is observed, testifying to weakness of the PRM. However, the length of the RND is within the limits of the age norm. B. At the age of one year and two months. Expansion of the rectum is combined with a sharp shortening of the RND between the marker near the activity of the external anal sphincter (fraction) and the ARA.

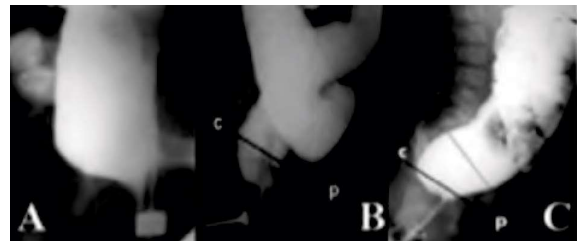


Figure 5. – Radiographs of patients with ARM after surgery. A. After pull-through procedure. Megarectum combined with the lack of PRM action. There is efflux of barium outward from the anal canal. B. After posterior sagittal anorectoplasty. Sharp shortening of the anal canal indicates failure of the PRM. C. After anterior sagittal anorectoplasty. Megarectum in conjunction with the normal length of the anal canal.

DISCUSSION

In healthy subjects the RND is the end zone of the intestinal tract, which in a contracted state prevents leakage of barium from the rectum. Its length ranges from 1.7 cm in newborns to 3.9 cm in adolescents, which according to manometric study corresponds to the length of the anal canal ($P < 0.01$)^{5,6}. It follows that RND is a closed anal canal, and its length is equal to the length of the anal canal. On the radiograph, the highest point of the anal canal is at its junction with the rectum, i.e. at the zero point of the anorectal angle (ARA). In 1953, F. Stephens determined that the place of transition where the rectum passes into the anal canal is at the level of the pubococcygeal line, outstretched from the coccyx to the lower contour of the pubic bone⁷. Anorectal inhibitory reflex is often seen as a reflex relaxation of the internal anal sphincter (IAS) in response to pressure on the rectal wall⁸. However, it is called an inhibitory reflex because despite relaxation of the IAS, emptying of the rectum does not occur, due to contraction of the PRM and the external anal sphincter (EAS)⁹.

With high definition manometry during the rectoanal inhibitory reflex, the peak pressure of the IAS is seen 1.6 cm from the anal verge, which corresponds to the peak relaxation pressure. In addition, two peaks of high pressure are determined. The lower concentric peak is located between 0.5 and 1 cm from the anal margin, caused by contraction of EAS.

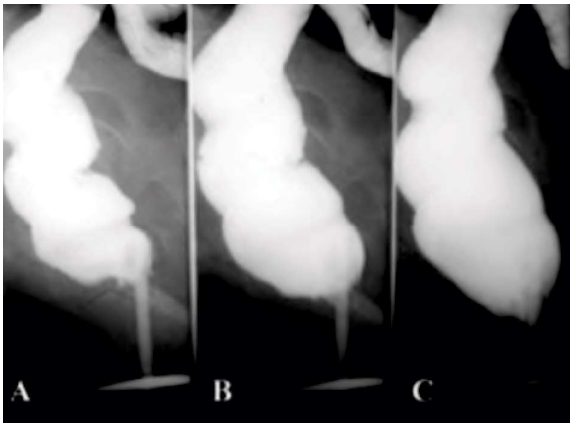


Figure 6. – Stages of rectal filling in a 68 year old patient. **A.** When filling starts the rectum is narrow and the ARA is acute. Barium enters into the anal canal behind of the tip of the enema. Length of RND is equal to 3.8 cm. **B.** Rectum widened, and RNA has become shorter. The ARA is right angled. **C.** At the end of the study the rectum has expanded to a greater extent. The RND has become two times shorter than on Figure 6, A. The ARA has become obtuse.

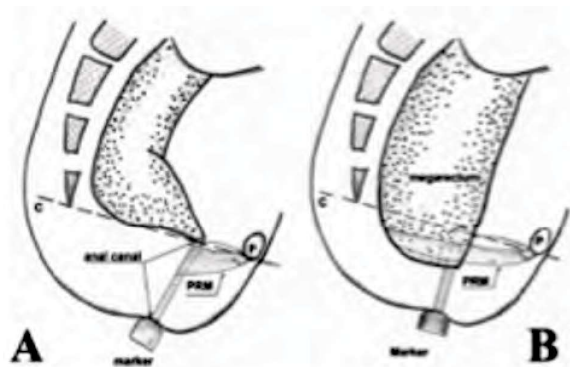


Figure 7. – Scheme of measuring descending perineum from the lowest point of the anal canal, i.e. from ARA to marker, rather than from the upper point. **A.** Healthy patient. The upper point of the anal canal is at the intersection of the axis of the anal canal with pubococcygeal line. The length of the anal canal is within the normal range. **B.** Patient with chronic constipation and “descending perineum” (see Figure 5 diagram, D). The length of the RND (functioning anal canal) is almost two times shorter than the norm.

The second peak pressure is recorded on the posterior wall between 2.4 cm and 4 cm from the anal margin. This is due to contraction of the PRM¹⁰. Thus, the length of the PRM's contraction zone occupies 40% of the proximal part of the anal canal on the posterior wall, which in our study corresponds to the clamping zone of the posterior wall of the anal canal to the tip of an enema.

When the rectum was filled through the manometric device's tube, we found that anal canal pressure decreased during penetration of barium into the anal canal in front of the tip of the enema. At this time, barium does not penetrate into the anal canal behind the tip, because the posterior wall of the anal canal presses to the tip of the enema as a result of contraction of the PRM. It follows that penetration of barium into the anal canal just in front of the tip of the enema is a radiological manifestation of the rectoanal inhibitory reflex.

If ARA in the tension and the more at rest descends relative to the pubococcygeal line, it is denoted by the term “descending perineum syndrome”, and indicates that the PRM is weak and does not perform its function. According to Baek et al. descending perineum syndrome, combined with chronic constipa-

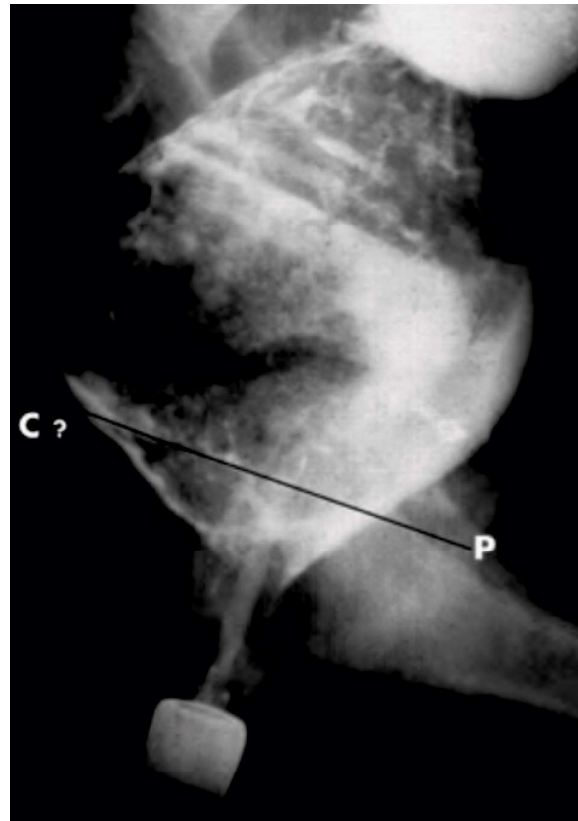


Figure 8. – 10 year old patient with functional constipation and damage to the PRM. Peristalsis of the rectum tries to expel an 8 cm fecal stone through the anal canal. Perineal descent is approximately 1.2 cm. There is shortening of RND length (2.4 cm), compared with the normal anal canal length at this age (3.2 cm).

tion, results from intense tension during bowel movements over a period of several years. It is also observed in faecal incontinence, idiopathic anal pain syndrome, solitary rectal ulcer and rectal intussusception, including rectal prolapse. The degree of the perineal descent can be measured in centimeters on radiographs performed during defecography, as caudal displacement of the ARA relative to the pubococcygeal line. If descent of the ARA is observed at rest, it is defined as a fixed descending perineum¹¹.

In mild cases, when the rectum starts filling with contrast medium the length of the RND is equal to the normal length of the anal canal. However, after the introduction of an additional amount of barium the rectum expands and the pressure therein increases. If the PRM is weak, barium begins penetrating into the anal canal along the posterior contour enema tip, and the RND is shortened to two times shorter than its normal length (Figure 6).

This observation is an example of a non-fixed descending perineum. In its early stage the PRM presses the posterior wall of the anal canal to the tip. But when the pressure rises, this cannot be sustained due to PRM weakness. As a result, the upper part of the anal canal opens fully and fills with barium.

Because of the high doses of ionizing radiation involved, defecography is not normally used in child radiology. We have found only one study¹² since 2003. Another disadvantage is the low reliability of defecography. On figure 3, C and D with a sharp descending perineum shows that ARA can be obtuse and right angled. Furthermore, defining the top of a normal ARA is very difficult, and is not always accurate because the coccyx and pubis are not always visible on the X-ray.

Application of radiopaque markers near the anus and knowledge of the normal length of the anal canal allow accurate determination of the “perineal descent”, not relative to the upper point of the anal canal, but with respect to its lower point (Figure 7). To obtain accurate information about the state of the PRM it is sufficient to make one lateral radiograph of the anorectal area following administration into the colon of between 200 to 500 ml (depending on age) of barium suspension.

To assess defecography on the selected image from the video, we need to find the lower contour of the pubic bone and the last vertebra. This is difficult, especially in anorectal anomalies when there is pathology of the spine. Measuring the distance from the ARA to the marker, we define the same displacement, but without the need to seek landmarks that ensure the accuracy of the measurement. Introducing a rather large amount of barium to the intestine causes high pressure in the rectum, the need to defecate and maximal tension for continence. This load on the PRM provokes its relaxation in cases of weakness.

This technique is especially useful in determining the cause of postoperative complications after surgery for anorectal anomalies. For example, in Figure 7, the anal canal is disclosed showing barium leaking because the PRM and IAS do not function. The state of the EAS is difficult to judge, since it cannot remain in a contracted state for more than one minute. Figure 7, B shows descending perineum syndrome with lack of PRM contraction following posterior sagittal anorectoplasty. Figure 5, C shows megarectum following anterior sagittal anorectoplasty. In this patient all sphincters are functioning normally (PRM, IAS and EAS). Chronic constipation is associated with damage from the act of defecation. The anal canal was divided from the levator ani muscle, which should normally open the anal canal, but being cut off from IAS it failed to disclose the anal canal during defecation. The cause of PRM damage in children with functional constipation is similar to women after childbirth². In figure 8 it is easy to calculate the diameter of the fecal stone, bearing in mind that the diameter of the marker is 1.6 cm. Thus, the diameter of the fecal stone is 8 cm. Passage of such a wide fecal stone through the anal canal in a child 7-10 years old can damage the PRM to the same degree as passage through the birth canal of a newborn's head with a diameter of 10-12 cm.

Stretching and weakness of the PRM in functional constipation and after childbirth is the visible tip of the iceberg. In previous studies we found that in patients with functional constipation¹³ and anorectal malformations⁴, shortening of the RND in descending perineum syndrome was accompanied by violation of the opening of the anal canal during defecation. This indicates that the function of the levator ani muscle, which normally opens the anal canal during defecation¹⁴, is disturbed too. Petros and co-authors have shown the role of stretching the pelvic floor ligaments in the pathogenesis of urinary incontinence in women¹⁵. Thus, all tissues of the pelvic floor are stretched and weakened in descending perineum syndrome.

CONCLUSION

Descending perineum syndrome is caused by damage to the pelvic floor muscle and ligaments. Our modification of the barium enema differs from the standard methodology by the presence of a radiopaque marker near the anus. Using this method we determined the length of the anal canal and the rectal width in children of different ages without pathology of the colon and anorectal area. A method of assessing descending perineum syndrome according to the distance between the anorectal angle and the marker near the anus is proposed. This contributes to a

more accurate assessment of “descending perineum syndrome” and negates the need for defecography. Use of a barium enema with a minimum of radiographs dramatically reduces the dose of ionizing radiation. This method can be applied not only to adults, but also to children with chronic constipation, fecal incontinence and anorectal malformations both before and after surgery, to assess the causes of complications.

DISCLOSURES

I am the only author of this article. In the process of working, I did not receive any help, including financial assistance. Therefore, there can not be any conflicts of interest. This scientific work is a retrospective analysis of the results of a standard X-ray study made at the end of the last century, so there is no need for a decision of the ethics commission. This article has not been sent to other journals.

REFERENCES

1. Parks AG, Porter NH and Hardcastle J. The syndrome of the descending perineum. Proc R Soc Med. 1966 Jun; 59 (6): 477-82.
2. Chang J, Chung SS. An analysis of factors associated with increased perineal descent in women. J Korean Soc Coloproctol. 2012 Aug; 28 (4): 195-200.
3. Foti PV, Farina R, Riva G, Coronella M et al. Pelvic floor imaging: comparison between magnetic resonance imaging and conventional defecography in studying outlet obstruction syndrome. Radiol Med. 2013 Feb; 118 (1): 23-39.
4. Levin MD, Levin MD. The pathological physiology of the anorectal defects, from the new concept to the new treatment. Eksp Klin Gastroenterol. 2013; (11): 38-48.
5. Kumar S, Ramadan S, Gupta V et al. Manometric tests of anorectal function in 90 healthy children: a clinical study from Kuwait. J Pediatr Surg. 2009 Sep; 44 (9): 1786-1790.
6. Gruppo Lombardo per lo Studio della Motilità Intestinale. Anorectal manometry with water-perfused catheter in healthy adults with no functional bowel disorders. Colorectal Dis. 2010 Mar; 12 (3): 220-225.
7. Stephens FD. Imperforate rectum. A new surgical technique. Med J Australia. 1953; 1: 202.
8. Rutenstock EM, Zani A, Huber-Zeyringer A, Höllwarth ME. Pre- and postoperative rectal manometric assessment of patients with anorectal malformations: should we preserve the fistula? Dis Colon Rectum. 2013 Apr; 56 (4): 499-504.
9. Palit S, Lunniss PJ, Scott SM. The physiology of human defecation. Dig Dis Sci. 2012 Jun; 57 (6): 1445-64.
10. Cheehey G, Nguyen M, Valestin J, Rao SS. Topographic and manometric characterization of the recto-anal inhibitory reflex. Neurogastroenterol Motil. 2012 Mar; 24 (3): e147-54.
11. Baek HN, Hwang YH, Jung YH. Clinical Significance of Perineal Descent in Pelvic Outlet Obstruction Diagnosed by using Defecography. J Korean Soc Coloproctol. 2010 Dec; 26 (6): 395-401.
12. Zhang SC, Wang WL, Liu X. Defecography used as a screening entry for identifying evacuatory pelvic floor disorders in childhood constipation. Clin Imaging. 2014 Mar-Apr; 38 (2): 115-21.
13. Levin MD, Degtyarov IG. Perspective of the functional constipation treatment in children. Surgery News (Belarus). 2011; 2: 113-124.
14. Levin MD, Troyan VV. Anatomy and physiology of anorectal zone. Hypothesis of continence and defecation. Novosti chirurgii. 2009; 17 (2): 105-18.
15. Petros P, Swash M, Bush M, Fernandez M, et al. Defecation 1: Testing a hypothesis for pelvic striated muscle action to open the anorectum. Tech Coloproctol. 2012 Dec; 16 (6): 437-43.

Correspondence to:

Michael Levin - Amnon veTavar 1/2 - Netanya 42202 - Israel
E-mail: nivel70@hotmail.com