

Analysis of radiographs of 23 cases published in open access with a diagnosis of rectal atresia and rectal stenosis.

Abstract

The conventional concept of rectal atresia and rectal stenosis (RA/RS) assumes that the obstruction is in the rectum proximal to the dentate line, with preservation of a normal anal canal. This assumption has not been rigorously validated by direct anatomical evidence. In this position paper, a critical radiological re-evaluation of 23 published cases with available imaging is presented. The analysis suggests that, in the examined cases, the obstruction with RA/RS in all 13 (58%) localized within the anal canal, most commonly at or near the dentate line, and is morphologically compatible with a membranous structure. In 5 (22%) cases, RA/RS was misdiagnosed instead of retrorectal mass lesions. In 3 cases (13%), obstruction was absent. Using the example of 2 (9%) cases of late diagnosis of the RS, it was shown that with a relatively large hole in the membrane, patients may suffer from chronic constipation for many years and be treated for functional constipation. This interpretation challenges the traditional classification and has direct surgical implications. If the obstruction is indeed confined to the anal canal, transanal membrane excision may allow preservation of native anorectal structures and avoid the functional consequences associated with more invasive procedures. Although the conclusions are limited by the retrospective and literature-based approach, according to mathematical analysis, the consistency of the results justifies reconsideration of the current paradigm and supports further prospective studies.

Keywords: anorectal malformations; rectal atresia; rectal stenosis; anal atresia; anal stenosis; embryology; surgery.

Abbreviations: RA -rectal atresia; RS – rectal stenosis; ARMs - anorectal malformations; ACA – anal canal atresia; ACS – anal canal stenosis; SOL - space occupation lesion; EAS – external anal sphincter; FC – functional constipation;

Introduction Rectal atresia/stenosis (RA/RS) is a rare disorder. Hamrick et al., believe that these patients are born with a normal anal canal but have a stricture or complete atresia located a few centimeters proximal to the dentate line. They found RA/RS in associated with a presacral mass in 5 patients (29%) out of 17 patients. The authors describe a surgical approach - circular rectorectal anastomosis in 4 cases, and an anterior dentate line sparing procedure in the last 13. All patients over 3 years of age demonstrated the ability to voluntarily empty their bowels [1]. Firstly, the dentate line is not a functional structure. Therefore, it's unclear why it had to be

preserved and how it could have been detected without exposing the intestinal lumen. Secondly, the article doesn't explain how the authors managed to avoid damaging the anal canal during these procedures. The ARM-Net Consortium authors analyzed 36 (1.3%) of 2619 patients with anorectal malformations: RA (n =18) or RS (n =18). However, they believe that patients with RA should be assessed and approached differently than patients with anal stenosis, since they are considered different diseases. The article provides a statistical analysis of cases diagnosed with RA/RS. The authors emphasize that due to the low level of evidence, it is impossible to judge the benefits of a particular treatment method [2] However, no evidence was provided that this was specifically RA/RS. Secondly, only one of the 13 patients with atresia had the anal canal preserved by opening the layer and dilating it under anesthesia. In 12 cases, the anal canal was damaged (3) or destroyed (9) by PSARP. Saenz et al., on behalf of the Pediatric Colorectal and Pelvic Learning Consortium (PCPLC), believe that "Congenital rectal stenosis can be defined as a well-developed, normally positioned anus within an intact sphincter complex but with a pathological narrowing located proximally to the dentate line" [3]. There is no evidence for this definition in the article by these authors, nor in the references they cite. There are no measurements determining the location of the RA/RS. Since the true length of the anal canal in newborns is approximately 1.7 cm [4,5], and the means that the RA/RS is in the rectum. However, P. Upadhyaya justified the transanal, end-to-end, rectorectal anastomosis method by the proximity of the obstruction to the anus. He argued about the presence of an anorectal canal distal to the obstruction and the possibility of intussuscepted of the membrane almost up to the anal verge [7]. Although he called the anastomosis "rectorectal" and the anal canal "anorectal canal," his rationale suggested the location of the obstruction in the anal canal. The statement by Hamrick et al. that RA/RS is associated with a presacral mass contradicts the studies by Malangoni et al., who believe that presacral teratoma, anterior sacral meningocele, or bony anomalies may simulate rectal stenosis. Operative management directed at the presacral lesion will relieve obstructive symptoms [8]. In most cases, diagnosis is based on the results of a digital examination. Almost every article state that a digital examination of the anus "detected atresia 2 cm above the dentate line." This statement is meaningless because it is impossible to locate the dentate line with a finger in a newborn. Secondly, a finger is an imprecise measuring instrument, especially since finger insertion elevates the pelvic floor muscles and the highly mobile membrane. Finally, in pediatric colorectal surgery, coordinates of the anal canal are lacking. Most radiographs do not show the anal canal area at all.

The purpose of this study is to investigate the pathological anatomy and physiology of RA/RS to improve the accuracy of diagnosis and rational treatment of this type of anorectal malformation (ARM). **Material.** I searched PubMed and Google Scholar articles describing the diagnosis of RA/RS with radiological studies. A total of 23 such studies were found, including two cases of stenosis in the anal canal diagnosed at a late stage.

Method of X-ray analysis of radiographs. To obtain accurate measurements, we use a contrast marker attached to the anal dimple. A thin layer of barium paste near the anus can serve as a marker. In such cases, the anus is defined as the intersection of the enema tip and the contrast medium on the perineum. The starting point can be the length of the anal canal from the pubococcygeal line to the marker near the anus. The standards for the anal canal length and rectal width in children of different ages were calculated earlier (**Table 1**) [5,6]. Megacolon is diagnosed when the width of the rectum exceeds the maximum normal values.

Table 1. The true rectal width and anal canal length depending on age.

Age	n	Rectal width (cm)	n	Anal canal length (cm)
5 days-11 months	12	1,3-3.0 (2.24±0.09)	7	1.7-2.5 (2.21±0.15)
1-3 years	9	3.0-3.7 (3.21±0.11)	7	2.3-2.8 (2.55±0.10)
4 – 7 years	9	3.0-3.9 (3.43±0.14)	8	2.3-3.6 (3.11±0.10)
8 – 10 years	9	3.2-4.1(3.70±0.06)	8	2.6-3.7 (3.07±0.11)
11 – 15 years	19	3.6-4.6 (39.5±0.07)	18	3.1-3.9 (3.43±0.10)

In full-term newborns, the length of the anal canal is 1.7 cm, and in premature ones 1.5 cm [6].

The true length of any image on a radiograph can be calculated using the formula: $s = S \times m/M$, where: (s) - the true length (cm), (S) - its length measured on the radiograph, (m) - the true length of the anal canal from the table 1, (M) - the length of the anal canal measured on the radiograph.

Based on the results of analysis of the radiographs, all studies were divided into five groups. The first group consisted of five studies in which it was possible to accurately determine the location of the membrane in the anal canal. The second group consisted of seven studies in which the obstruction was located below the pubococcygeal line, i.e., in the anal canal, but its precise location could not be determined. The third group consisted of five patients in whom the obstruction was caused by anterior displacement of the rectum by a retrorectal mass, leading to torsion of the intestinal tube. The fourth group consisted of three studies in which obstruction

was not proven. The fifth group included descriptions of two cases with late diagnosis of anal stenosis.

Results.

First group. In 6 patients the atresia was in the anal canal and in these cases, it was possible to measure the approximate length of the anal canal above and below the level of obstruction. This was shown best in the article by Stenström et al [9]. (**Figure 1**). A 22-hour-old full-term girl was hospitalized due to abdominal distension and failure to pass meconium. A digital rectal examination revealed a blind end of the anal canal 2 cm above the dentate line. In describing the radiograph (a), the authors note that: - A catheter is placed at the bottom of the anal canal " (a). Rectal atresia was diagnosed, and a sigmoid colostomy was performed. At 4 months of age, an enema from the distal stoma was carried out. The distance between the endings was approximated to 2 cm (Figures b and c). The endoscopic was advanced through the sigmoidostomy down to the blind end of the rectum and then almost protruded through the anus (Figures d). The 2 cm thick wall between the endings of the rectum was divided with a diathermy between two stay sutures after which the coloscope came through the anus. The anastomosis was performed with a total of 6 stitches of resorbable suture material. Two weeks after the operation, a daily dilatation schedule was initiated and continued until Hegar 16 could be used.

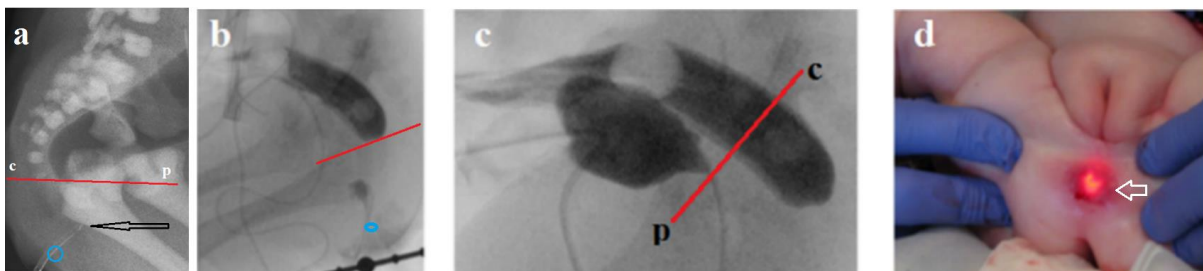


Figure 1. (a). The rectum is located above the pubococcygeal line (red). The arrow indicates the tip of the soft catheter, which could not be advanced further. I have marked the approximate location of the anus with a blue circle. The closed anal canal, 1.7 cm long, is located between the rectum and anus. The arrow indicates that the obstruction is located almost in the middle of the anal canal, not in the rectum. It is approximately 0.8 cm from the anus. **(b)** The authors believe that "a distance of 2 cm between the rectal endings" is present. I have marked the anus with a blue circle, from where the contrast agent fan-shaped over the buttocks. At 4 months of age, the length of the anal canal from the pubococcygeal line to the anus is approximately 2 cm. The anal canal above and below the membrane is closed. **(c)** During a combination of the

high-pressure colostogram with contrast in the urinary systems, the upper part of the anal canal opens distally to the pubococcygeal line and ends blindly above the membrane. **(d)** "The endoscope was pressed against the rectal atresia, and with the help of external pressure, the endoscope could be seen 1 cm up in the anal canal" [9]. However, the image does not indicate that the endoscope light is at any distance from the membrane. Its light is visible because the endoscope has pushed the membrane towards the anus, because the ring of the stretched subcutaneous portion of the external anal sphincter is visible (arrow).

An analysis of this study suggests that the authors' measurement instrument was not the most accurate. They determined through digital examination that the blind end was 2 cm above the dentate line. Since the anal canal length in newborns is approximately 1.7 cm, with the dentate line located approximately 0.7 cm from the anal verge, the blind end should be located 3 cm from the anal verge, i.e., in the rectum. However, on radiographs (a, b), the visible intestine is located at the level of the pubococcygeal line (red). The large gap between it and the end of the anal catheter (arrow) is explained by the fact that the upper part of the anal canal is in a contracted state. Colostogram was made with high rectal pressure, which caused the anal canal to open above the septum. Since the length of the anal canal in a 4-month-old child is approximately 2 cm, then with a wide opening of the upper and lower parts of the anal canal, the narrow septum was located somewhere in the middle of the anal canal, i.e., about 1 cm from the anal verge. This calculation is approximate, since the authors did not use a marker near the anus and did not use other instruments to measure distances. The presence of a membrane in the anal canal was proven during surgery.

Conclusions. 1) The surgeon's finger cannot serve as a measuring instrument because it displaces the membrane in the anal canal and the pelvic floor muscles cranially, leading to false conclusions. 2) The phrase suggesting the atresia is located "2 cm above the dentate line" is a compilation from articles that refer to the anal canal as the rectal sac. Measurements showed this to be incorrect because the membrane was located up to 1 cm from the anal verge in the anal canal, not 3 cm in the rectum. Secondly, it is meaningless because it is impossible to determine the dentate line with a finger. Analysis of other cases shows that the authors, when referring to "dentate line," mean the anal verge. (3) The normal anal canal is in a contracted state and opens only under high rectal pressure. The contracted anal canal above the membrane is erroneously considered the length of the lesion.

Below are 4 of the remaining 5 RA/RS cases (b, c, d) where the membrane level can be seen [10,11,12, 13]. The sixth (RS) case is given in the supplementary material [14] (First Group).

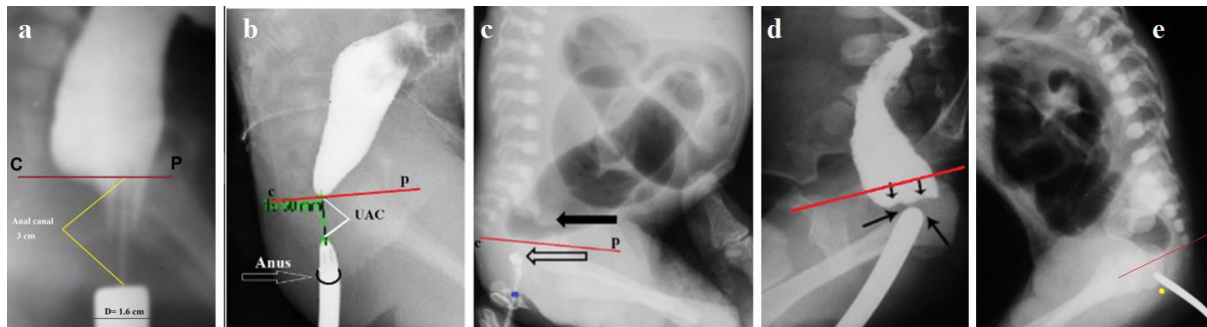


Figure 2. (a) As an example of anal canal function, I've plotted important landmarks on a lateral radiograph of a 3-year-old patient with constipation. The pubococcygeal line (red) is the uppermost point of the anal canal. The anal canal is located between this line and the anus. Knowing the diameter of the marker near the anus (1.6 cm), the length of the anal canal can be accurately calculated as 3 cm. (b) The membrane is in the middle of the anal canal, but its upper part (UAC) is in a contracted state [10]. (c) The catheter inserted through the anus stopped in the middle of the anal canal (hollow arrow) [11]. (d) Although Hegar's dilator has lifted the membrane, it is visible that it is in the middle of the anal canal [12]. (e) A 3-day-old male baby presented with pneumaturia, meconiurea and non-passage of stools through anus since birth. Perineum and anus were normal, but red rubber catheter could not be passed through anus beyond 3 cm as resistance was found beyond it (Figure e). After clinic-radiological diagnosis of rectal atresia, laparotomy was done. Per-operatively congenital pouch colon of unusual anatomy was found. Thereafter, posterior sagittal approach was used with colorectal anastomosis [13]. **Analysis.** I drew a pubococcygeal line, above which there is a rectum of normal width. The yellow dot indicates the approximate location of the anus. Since the anal canal length between the line and the dot in newborns is 1.7 cm, the tip of the rigid probe is 0.7 cm from the anus. The distance between the line and the tip of the catheter, 1 cm, is due to the contraction of the upper anal canal. Therefore, we are talking about a membrane located in the anal canal at the level of the dentate line.

Second group. In 7 cases, the atresia was located below the pubococcygeal line, i.e., in the anal canal, but due to the lack of landmarks or due to the use of hard catheters or Hegar dilators, it was impossible to determine the location of the membrane [14-20]. Radiographic studies of

four patients are presented below [15-18]. The analysis of the remaining three patients [19-21] is given in the supplementary materials after References.

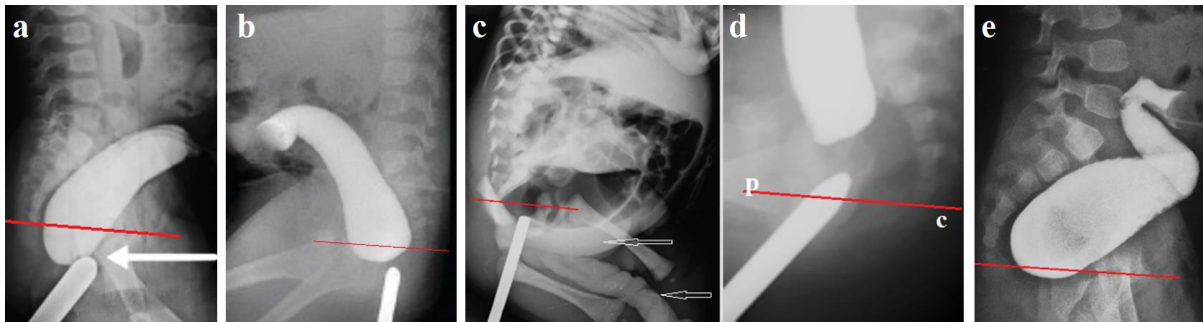


Figure 3. These patients were operated on with a diagnosis of rectal atresia, but in each case the obstruction was located below the pubococcygeal line, i.e., in the anal canal. In three cases (**a**-[15], **b** – [16], (**c-d** – [17]), the use of rigid catheters led to cranial displacement not only the membrane but also the pelvic floor muscle. (**c**) In a newborn, gas in the intestine and the catheter retention is below the pubococcygeal line. The arrows show the diaper that covers the anus. (**d**) After 6 months a contrast agent was introduced through a colostomy with the simultaneous insertion of a Hegar dilator. A cranial displacement of the pelvic floor occurred due to the introduction of a Hegar dilator with great force, as evidenced by the angular displacement of the dilator along with the anal canal [17]. (**e**) The authors captioned this radiograph: - "Distal cologram showing the rectal atresia without any fistula" [18]. However, only the rectum with a fecal stone inside is visible. This radiograph does not carry any evidence of anorectal malformation. Atresia could only be in the anal canal.

In 13 (62%) of 21 newborns operated on for a diagnosis of rectal atresia or rectal stenosis (2), radiographic analysis revealed an obstruction in the anal canal. In 6 (29%), the obstruction was located approximately in the middle of the anal canal. In 7 (33%), the precise location of the atresia could not be determined. In only one case was rectal atresia associated with a congenital pouch colon. No other anorectal malformations or retrorectal space-occupying lesions were detected in any of the 21 newborns. The typical radiographic picture of "RA/RS" is a dilated rectum located above the area where the catheter stops in the anal canal.

Third group. The third group consisted of 5 cases where radiographic examination did not reveal intestinal atresia, and the obstruction was caused by displacement of the rectum by a retrorectal space-occupying lesion [22, 12].

Case description (Figure 4 a-c). Premature baby with a normal appearing anus but there was failure to pass meconium. On digital rectal examination there was a blind ending rectum 2 cm

above the dentate line. A plain abdominal X-ray revealed dilated loops of bowel, and a contrast enema demonstrated rectal atresia [22].

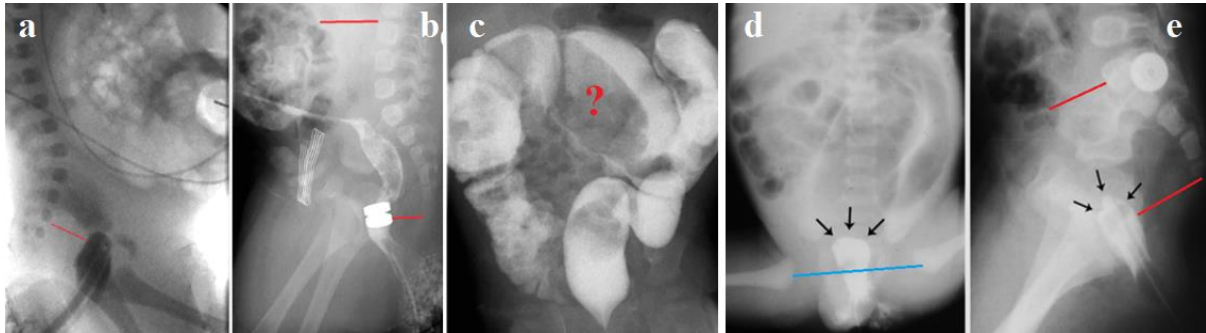


Figure 4. (Case a-c) [22]. (a) On the lateral image, non-dilated bowel loops are in the upper abdomen. Contrast medium injected through the anus outlines the blind-ending bowel above the pubococcygeal line. Sharp dilation of the retrorectal space indicates the presence of a space-occupying lesion that displaces the bowel anteriorly. There is no dilated bowel above it. **(b)** Contrast medium injected from the colostomy penetrates through the magnets to the outside. The course of the colon indicates a large abdominal volume, which is not due to the small volume of intestinal loops. The retrorectal (below) and retroperitoneal (above) spaces are dilated (red lines). **(c)** Post-treatment contrast enema demonstrates indentation of large masses (?) located behind the colon. **(Case d-e) [12]. (d)** The contrast medium injected through the anus terminates blindly above the pubococcygeal line (blue). The dilated sigmoid colon is visible above it. **(e)** The lateral radiograph shows a sharp dilation of the retrorectal space (red line below) and the retroperitoneal space above. There is no dilated colon above the blindly terminating rectum.

Conclusion. Thus, in five (24%) of the 21 newborns diagnosed with rectal atresia, the cause of the obstruction was a retrorectal mass. This mass displaced the rectum anteriorly, resulting in bowel kinking and impaired patency. There are no signs suggesting rectal atresia. Three more similar cases are analyzed in the supplementary materials after the references.

Fourth group. It included three cases in which neither radiographic signs nor clinical picture were consistent with intestinal obstruction.

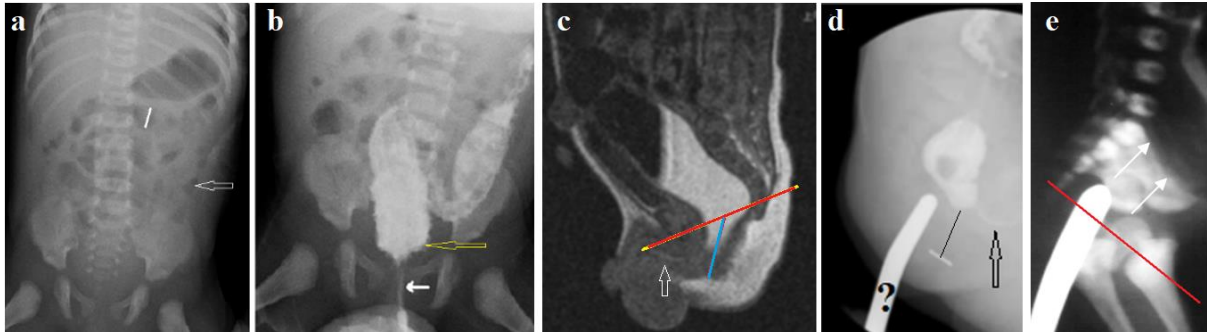


Figure 5. Case (a-b) [23]. From the article we know: A twenty-day-old female child was admitted with a history of chronic vomiting, not passing meconium since birth and a progressive abdominal distension. The perineal examination objectified a normally placed anus. When introducing a thermometer per rectum, it stops at 2 cm from the anal verge. **(a)** Abdominal x-rays showed a massively distended colon with pelvic emptiness. **(b)** A barium enema was performed, showing an atretic inferior rectal segment with a superior rectal pouch and no fistula [23].

Analysis of radiographs: (a) A radiograph shows no dilated gastrointestinal tract. A normal-width transverse colon (line) and a sharply narrowed descending colon (arrow) are visible. (b) After administration of the contrast medium into the rectum, the authors marked the closed anal canal with a white arrow, calling it "an atretic inferior rectal segment." Additionally, a dilated rectosigmoid and eroded colonic contours (yellow arrow) are visible, indicating severe colitis. Thus, a 22-day-old newborn with no dilated intestinal loops and the passing of the contrast medium into the dilated rectum cannot have rectal atresia. A probable diagnosis is enterocolitis due to Hirschsprung disease.

Case 2. (c-d) [24]. It is reported that a full-term newborn boy was admitted to the hospital with abdominal distension after birth. Perineal examination revealed a normal anus; however, a thermometer could only be inserted 2 cm into the anus, indicating rectal atresia. Magnetic resonance imaging revealed rectal atresia (Fig. c). The child was discharged from the hospital after a transverse loop colostomy. He underwent anal dilation with a Hegar dilator at home and was readmitted for surgery at the age of 5 months. Preoperative distal colostomy revealed a rectourethral fistula, and the distance between the two rectal pouches was 0.5 cm (Fig. d). The child underwent posterior sagittal anorectoplasty [24].

Analysis of the article. MRI shows opening of the superior части anal canal below the pubococcygeal line (red) and fluid leakage into the bulbar urethra (my arrow). Diagnosis: ectopia ani into the urethra. No signs of rectal atresia. There is no explanation for why the

"normal" anal canal had to be dilated. (e) Five months later, contrast was administered via a colostomy with the simultaneous insertion of a Hegar dilator through the canal, which was undergoing dilation. The authors observed a bulbar fistula. The tip of the Hegar dilator is located behind the anal canal (black line), outside the puborectalis muscle. There is no doubt that this canal was created to locate the rectum. This artificial canal was an iatrogenic error.

Case 3. (e). A one-day, full term male presented by no pass meconium and abdominal distension. On examination, the anus was looking normal, but a catheter and Hegar dilator could not be introduced beyond 2cm from the anal verge. An invertogram with a metal Hegar dilator in the anal canal was done which revealed high anorectal anomaly (Figure e) [25]. Analysis. Radiographs are of poor quality. The end of the Hegar dilator is in the rectum above the pubococcygeal line. The authors use arrows to indicate the supposedly dilated sigmoid colon. However, this darkening has no contours. Secondly, the sigmoid colon cannot be this wide, especially a day or two after birth. This radiograph is the only document, but it has no diagnostic value. Description of the operation: "The dome of the anus was grasped by a mosquito forceps (Fig2) and two stay sutures are taken at its sides. A transverse incision was done between the stay sutures. The is identified, dissected for a few millimeters, opened and evacuated completely aided by gentle pressure on the lower abdomen. The rectal pouch was intussuscepted through the anus and an end-to-end recto-anal anastomosis performed". The operation is impossible to understand because the anus has no "dome," there is no concept of a rectal pouch in anatomy, and the location of the atresia and its treatment are not described. The patient had a normal anal canal for 2 cm. Since a recto-anal anastomosis was performed, then a normally functioning anal canal was removed. These inconsistencies raise doubts about the reliability of the description.

Fifth group. This group consists of two cases of late diagnosis of rectal (anal canal) stenosis, including our observation [26]. We examined a 78-year-old woman whose severe constipation appeared at early school age. All her life she was helped only by cleansing enemas and digital removal of feces. Defecation was always painless. With age, problems with defecation increased so much that the patient began to have suicidal thoughts. Upon examination, a large belly is noticeable. A digital rectal examination performed because of prolonged defecation retention revealed a narrow, hard, thin-walled ring in the anal canal a few centimeters from the anus. The hole in the ring made it possible to insert an index finger about 2 cm wide into the rectum. A large, very dense fecal stone was felt above the membrane, which, during manual examination, was broken into fragments and removed. Before X-ray examination, the perineum in front and

behind the anus was smeared with barium paste to determine the location of the anus as the point of intersection of the enema tip with the contrast line on the perineum. 300 ml of barium suspension was injected into the rectum (**Figure a**). After removing the enema tip, a No. 20 Foley catheter was inserted into the rectum without any effort. The balloon was inflating to a diameter of ≈ 2.5 cm and pulled into the anal canal as far as it would go. The balloon stopped over the constriction at 1.9 cm from the anus (**Figure b**).

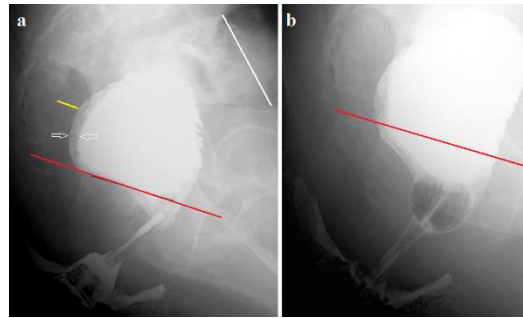


Figure 6. (a) A lateral radiograph was taken after the administration of 300 mL of barium. The true length of the anal canal between the anus and the pubococcygeal line (red line) in adults is known to be ≈ 4 cm. The rectum is only partially filled because the retrorectal space (yellow line) is dilated and the barium is in the mucosal folds between the white arrows. The presence of barium below the pubococcygeal line indicates insufficiency of the puborectalis muscle (descending perineum syndrome). The sigmoid colon (white line) is significantly dilated to 4 cm. **(b)** The balloon of the Foley catheter, inflated in the rectum to a diameter of ≈ 2.5 cm, is lodged in the anal canal above the stenosis, at 1.9 cm from the anus.

Thus, a membrane with a rigid ring approximately 2 cm in diameter was in the middle of the anal canal. Severe constipation was caused by this ring being unable to pass dense fecal matter larger than 2 cm in diameter. Diagnosis: congenital stenosis of the anal canal. Secondary megacolon. The delay in diagnosis of anal stenosis in both this case and the case described by Chowdhury et al. [26] is due to the relatively wide opening in the membrane. The walls of the opening are rigid and do not change with age. In childhood, the opening's width can allow for normal bowel movements. However, with age, the width of the rectum increases, and feces form within it in proportion to its width, inevitably leading to severe constipation.

Discussion

Table 1 presents the results of a mathematical analysis of 23 cases published with a diagnosis of RA/RS, including 2 cases with late diagnosis of anal canal stenosis.

Groups	Results	Number of cases	%	Stenosis
1st	Membrane in the middle of the anal canal	6	26	1
2nd	Atresia in the anal canal	7	30	1
3rd	Retrorectal space-occupying lesion	5	22	
4th	RA/RS absent or conflicting data	3	13	
5th	Late diagnosis of anal canal stenosis	2	9	2
Total		23	100	4

In pediatric colorectal surgery, the presence of a normal anal canal in patients with RA/RS is recognized [1,2,3]. However, pediatric surgeons do not rely on scientific data on the anatomy and physiology of the anorectal area, but on the experience of Alberto Peña. Therefore, they refer to the anal canal as the rectum, rectal sac, or anorectal canal. Most pediatric surgeons stated that “the finger stopped 2 cm above the dentate line” as a mantra, assuming it is proof of rectal atresia. However, it is impossible to detect the dentate line with a finger in a newborn. Only in 6 cases did the anal canal and bony landmarks appear on radiographs. This allowed us to determine that the membrane blocking the intestinal lumen is in the middle of the anal canal. In seven cases (Group 2), the authors not only failed to use a contrast marker near the anus but took radiographs without including the anal canal area, as the contracted anal canal does not contain gas and is not visible. They used rigid catheters or a Hegar dilator, which, with the operator's effort, elevated the membrane and pelvic floor. However, and in these cases, the membrane was also located in the anal canal, although its exact location could not be determined.

Understanding that the membrane is located not in the rectum, but in the anal canal, is crucial. This means that correction can be done through the anus. In three of 7 patients of the second group, correction was corrected using various pull-through techniques, which inevitably leads to damage to the anal canal. In two cases, a transanal anorectal anastomosis was performed. In one case, a transanal membrane excision was performed. One patient, aged 3.5 years, had stenosis in the membrane and megacolon. In this case the #28 EEA gun (without anvil) was inserted transanally. The shaft was guided into the opening by a finger into the proximal rectum, through the opening in the sigmoid colon. The anvil was screwed onto the shaft through the colotomy opening until it was flushed at the site of the central opening. The gun was then fired, resulting in only the membrane being removed. Firstly, the possibility of transanal correction

proves the presence of a membrane in the anal canal. Secondly, membrane excision is the ideal surgical method, as it leaves the normally functioning anal canal intact. To help pediatric surgeons choose the most appropriate correction method, this anorectal defect should be called in accordance with the anatomical location of the membrane, i.e., “anal canal atresia” (ACA) or “anal canal stenosis” (ACS). John Caffey, in his 1978 textbook *Pediatric X-Ray Diagnosis*, wrote that pediatric surgeons had concluded that anorectal malformations were ectopia of the anal canal, but they continued to habitually refer to the anal canal as a fistula [27]. A new generation of pediatric surgeons emerged who began to assert, without evidence, that there was no anal canal in anorectal malformations, except in cases of rectal atresia. This example shows how important it is that the name corresponds to the pathological anatomy.

The theory of vascular insufficiency has been known for over 150 years [28]. It is considered valid for explaining the etiology of duodenal atresia and the intestinal tract. However, impaired blood supply leads to resorption of a portion of the intestine and the formation of atresia with preserved proximal and distal segments. This means that between the normal segments there is not a membrane, but a long cord. In all radiographs with RA/RS, authors describe a gap from the rectum to the site of the rectal catheter stop of 1-2 cm. In fact, the upper part of the anal canal above the diaphragm is in a contracted state. Thus, the theory of vascular insufficiency does not correspond to the pathological anatomy of rectal atresia described above. The present study found the presence of a membrane in the middle of the anal canal in 6 of 12 newborns. In 7 newborns, atresia and stenosis were also located in the anal canal. There is a high probability that in these newborns, the membrane was also located in the middle of the anal canal. Embryological studies show, normally, at the junction, where the endodermal and exodermal parts of the anal canal meet, an anal membrane is formed, which ruptures during embryogenesis with a length of 13.5-135 mm [28, 29]. The dentate line remains at this site. Above it is 2/3 of the anal canal, and below it - 1/3. It is natural to assume that if the membrane is not destroyed, atresia of the anal canal occurs, and if the membrane is partially destroyed stenosis of the anal canal occurs.

Of the 23 radiographic studies, not a single case of atresia in the rectum was found. This fact supports the hypothesis that anal atresia is not a random vascular lesion. Since the true length of the anal canal in newborns is approximately 1.7 cm, the membrane located 6 mm from the anal verge and 11 mm from the rectum. Abdominal distension, vomiting, and failure to pass meconium are not diagnostic symptoms of ACA. In these cases requires insertion of a gastric tube and a soft catheter into the rectum. If the rectal catheter does not pass into the rectum, a

lateral X-ray should be performed in the supine position two days later, when the gas reaches the rectum. Lubricate the skin in front of and behind the anus with barium paste (a mixture of barium and baby cream). Insert the catheter into the anal canal until it stops and inject 2-3 ml of contrast medium. During fluoroscopy, the abdomen compresses between the doctor's palms to increase rectal pressure and to open the upper anal canal. Take an X-ray when the gas from the rectum approaches the contrast medium in the anal canal. The diagnosis of ACA is certain if the distal anal canal terminates blindly, equidistant between the pubococcygeal line and the anus. The same technique is used if a colostomy has already been performed. It is important to know that the posterior wall of the rectum is tight adjacent to the spine.

A precise diagnosis tells the surgeon that the anal membrane is located 7 mm from the anal verge. As demonstrated by the cases described above, anal distension allows the membrane to be visualized, opened between clamps, and removed without damaging the internal anal sphincter. Suturing is a mistake, as it leads to stenosis. Insertion of a tracheostomy tube approximately 1 cm in diameter with an inflatable balloon into the rectum prevents the development of stenosis. The diastasis between the edges of the mucosa fills with elastic tissue within 2 weeks [31, 32], after which the balloon in the rectum deflates and the tube can be removed.

There are two different opinions regarding the combination of RA/RS with abdominal masses. Hamrick et al. found RA/RS associated with a presacral mass in 5 patients (29%) out of 17 patients [1]. They imply that RA/RS and a presacral mass can coexist in a significant percentage of patients. Malangoni et al. believe that presacral teratoma, anterior sacral meningocele, or bony anomalies may simulate rectal stenosis [8]. In our series, in 5 of 21 neonates (24%) in whom the authors diagnosed RA, the cause of rectal obstruction was retrorectal and retroperitoneal space-occupying lesions that displaced the rectum, leading to intestinal torsion. In these cases, space occupation lesions were not diagnosed despite a sharp expansion of the retrorectal space, abdominal distension without intestinal dilation, and the absence of dilated bowel opposite the site of obstruction. These cases differ from typical anal atresia in that the obstruction was in the rectum or sigmoid colon, where the proximal segment of the intestine was posteriorly from the distal segment. Formally, these patients had rectal obstruction. However, in terms of etiology, pathogenesis, clinical symptoms, and radiographic features, they represent different diseases. In membranous anal atresia, treatment involves excision of the membrane, while in tumors, obstruction resolves after removal of the SOL [8].

In the present study, the number of atresia was almost 3 times more than stenosis. Given the common embryonic origin, there is reason to believe that a significant number of patients with congenital anal stenosis, in whom the orifice in the membrane is wide enough, suffer from chronic constipation under the mask of functional constipation (FC). For example, Clayden and Lawson, during anal dilatation, which was performed under general anesthesia by inserting up to 4 fingers of the operator's hand, in 4 (5%) of 79 patients with FC they were unable to insert more than 2 fingers due to the presence of a rigid ring that was 1 cm from the anal verge [33]. Duhamel, with histological examination of the IAS found in some patient fibrous changes in the anal canal, which were like congenital anal stenosis [34]. It follows from this that when examining patients with megacolon, one must consider the possibility of relatively wide stenosis of the anal canal, which cannot be determined by bougienage. Thus, anal distension, which is effective in treating FC, may also be useful for diagnosing secondary megacolon because of congenital stenosis of the anal canal.

This analysis reveals the state of pediatric colorectal surgery. Since leading surgeons claimed that in ARMs the anal canal is absent, except in cases of rectal atresia [34], it was not customary to mention the anal canal in articles. For example, in an article devoted to the augmented-pressure distal colostogram, the authors emphasized: "It is extremely important in this regard to understand that the lowest part of the rectum is usually collapsed from the muscle tone of the funnel-like striated muscle mechanism that surrounds the rectum in 90% of cases..." [35]. These statements contradict the axioms described in anatomy textbooks. There are no muscles around the rectum; muscles are located around the anal canal, and they are in constant contraction, performing the function of fecal retention. The authors refer to the anal canal as the rectum to prove that PSARP does not destroy the anal canal but simply replaces one part of the rectum with another. Publications proclaimed this experience to be more significant than the research of anatomists and physiologists. Research in colorectal surgery in people over 18 years of age is not referenced. Advertising articles convinced pediatric surgeons that PSARP was the ideal procedure for all APMs. This made any scientific research meaningless. An article by de Beaufort on behalf of the European ARM-Net Consortium experience provides statistical data from 13 patients with RA and 10 patients with RS [2]. PSARP was performed in 65% of them. To understand what happened to these patients, it is necessary to turn to pathophysiological analysis of PSARP: 1) Access to the rectum is opened after transecting the puborectalis muscle, which plays an important role in fecal continence; 2) The deep and superficial parts of the external anal sphincter (EAS) are dissected. The subcutaneous part of

the EAS, which is 10 times smaller than the other parts and does not play a significant role in fecal continence, remains intact; 3) The internal anal sphincter, which performs 50% of fecal continence, is removed, and the avascular and denervated rectum is inserted in its place. 4) During dissection of the rectum, the levator plates, which open the anal canal during defecation, are torn away from it. 5) During wide dissection of the perineal tissue, numerous invisible neural connections between the organs responsible for pelvic floor reflexes (anorectal, sexual, and urological) are severed. Thus, instead of a normally functioning anal canal, a perineal fistula arises. These patients inevitably suffer from chronic constipation, fecal incontinence, urological and sexual problems, which worsen with age. This means that pediatric surgeons in Europe lack accurate methods for diagnosing RA/RS and are unaware that the obstruction is caused by a membrane, and that the membrane is in the anal canal. I hope that my analysis will attract the attention of researchers for the benefit of patients with RA/RS, so that the correct choice between rectal pull-through surgery and transanal membrane excision can be determined in practice.

Conclusion The radiometric analysis suggests that in cases of rectal atresia and stenosis, the obstruction is localized within the anal canal, most commonly at near the dentate line, and is morphologically compatible with a membranous structure. This interpretation challenges the traditional classification and has direct surgical implications. If the obstruction is indeed confined to the anal canal, transanal membrane excision may allow preservation of native anorectal structures and avoid the functional consequences associated with more invasive procedures. While the conclusions are limited by the retrospective and literature-based nature of the analysis, the consistency of findings warrants reconsideration of the current paradigm and supports further prospective investigation.

References

1. Hamrick M, Eradi B, Bischoff A, Loudon E, Peña A, Levitt M. Rectal atresia and stenosis: unique anorectal malformations. *J Pediatr Surg.* 2012 Jun;47(6):1280-4. doi: 10.1016/j.jpedsurg.2012.03.036.
2. de Beaufort CMC, Gorter RR, Iacobelli BD, Midrio P, Sloots CEJ, Samuk I, van Rooij IALM, Lisi G; ARM-Net Consortium. Rectal atresia and rectal stenosis: the ARM-Net Consortium experience. *Pediatr Surg Int.* 2023 Jul 28;39(1):242. doi: 10.1007/s00383-023-05518-7.

3. Saenz ZM, Austin K, Avansino JR, al. Pediatric Colorectal and Pelvic Learning Consortium (PCPLC). Can Anorectal Stenosis be Managed With Dilations Alone? A PCPLC Review. *J Pediatr Surg.* 2024 Aug;59(8):1652-1656. doi: 10.1016/j.jpedsurg.2024.04.007.
4. Jorge JMN, Habr-Gama A. Anatomy and Embryology of the Colon, Rectum, and Anus. In: Wolff B.G. et al. (eds) *The ASCRS Textbook of Colon and Rectal Surgery.* Springer, New York, NY 2013; 1-25.
5. Levin MD^{1,2}. Reaction to Koppen et al., 'Assessing colonic anatomy normal values based on air contrast enemas in children younger than 6 years'. *Pediatr Radiol.* 2018 Jun 30. doi: 10.1007/s00247-018-4181-1.
6. Levin MD. Radiological anatomy of the colon and rectum in children. *Gastroenterology & Hepatology.* 2019; 10 (2):82-6.
7. Upadhyaya P. Rectal atresia: transanal, end-to-end, rectorectal anastomosis: a simplified, rational approach to management. *J Pediatr Surg.* 1990 May;25(5):535-7. doi: 10.1016/0022-3468(90)90567-s.
8. Malangoni MA, Grosfeld JL, Ballantine TV, Kleiman M. Congenital rectal stenosis: a sign of a presacral pathologic condition. *Pediatrics.* 1978 Oct;62(4):584-7.
9. Stenström P, Clementson Kockum C, Arnbjörnsson E. Rectal atresia-operative management with endoscopy and transanal approach: a case report. *Minim Invasive Surg.* 2011;2011:792402. doi: 10.1155/2011/792402.
10. Gieballe M, AlKharashi N, Al-Namshan M, AlJadaan S. Outcomes of transanal endorectal pull-through for rectal atresia. *BMJ Case Rep.* 2018 May 18;2018:bcr2017224080. doi: 10.1136/bcr-2017-224080.
11. Ahn M, Cummins CB, Tran S, et al. Laparoscopic repair of long-gap rectal atresia. *Journal of Pediatric Surgery Case Reports.* Volume 42, March 2019, Pages 54-57. doi.org/10.1016/j.epsc.2018.12.018
12. Al-Salem, A. (2014). Congenital Rectal Stenosis and Atresia. In: *An Illustrated Guide to Pediatric Surgery.* Springer, Cham. https://doi.org/10.1007/978-3-319-06665-3_30
13. Singh S, Ahmed I, Wakhlu A. A newer variant of congenital pouch colon with rectal agenesis: management strategy and review of the literature. *BMJ Case Rep.* 2011 Aug 31;2011:bcr1220103635. doi: 10.1136/bcr.12.2010.3635.
14. Hosseini SM, Ghahramani F, Shamsaeefar A, Razmi T, Zarenezhad M. Wind sock deformity in rectal atresia. *Saudi J Gastroenterol.* 2009 Apr;15(2):133-4. doi: 10.4103/1319-3767.48974.

15. Elnour AS, Nugud F, Taha O. Rectal atresia managed by anterior anal canal preserving posterior sagittal approach: A case report. *Journal of Pediatric Surgery Case Reports* Volume 129, June 2026, 103244.
16. Menon R, Saxena R, Jayakumar TK, Sinha A. Minimally Invasive Strategies in Rectal Atresia and Anal Stenosis: A Report of Two Cases. *J Indian Assoc Pediatr Surg.* 2025 May-Jun;30(3):394-397. doi: 10.4103/jiaps.jiaps_251_24.
17. Mehmetoğlu F. Rectal Atresia and Congenital Hypothyroidism: An Association or Coincidence? *European J Pediatr Surg Rep.* 2018 Jan;6(1):e7-e10. doi: 10.1055/s-0037-1612610.
18. Shehata S, ElSawaf M, Kotb M. Transanal recto-anal anastomosis for treatment of rectal atresia: a review of 4 cases. *BMC Pediatr.* 2023 Jan 28;23(1):46. doi: 10.1186/s12887-023-03859-9
19. Kurashima M, Joshi S, Sobrino J, Blewett C. Rectal Atresia Treated Via a Transanal and Posterior Sagittal Approach: A Report of Two Cases. *Cureus.* 2023 May 8;15(5):e38694. doi: 10.7759/cureus.38694.
20. Jayaswal S, Shah H, Murthy K, Bhandarkar K, Makhija OP. Membranous variety of rectal atresia - primary management in a neonate. *J Minim Access Surg.* 2010 Oct;6(4):114-5. doi: 10.4103/0972-9941.72598.
21. Al-Salem AH, Al-Faraj A, Talwalker V. Congenital rectal stenosis: A simple approach to management. *Ann Saudi Med.* 1994 Jan;14(1):56-7. doi: 10.5144/0256-4947.1994.56.
22. Russell KW, Rollins MD, Feola GP, Scaife ER. Magnamosis: a novel technique for the management of rectal atresia. *BMJ Case Rep.* 2014 Aug 5;2014:bcr2013201330. doi: 10.1136/bcr-2013-201330.
23. Laamrani FZ, Dafiri R. Rectal atresia: a rare cause of failure to pass meconium. *Pan Afr Med J.* 2014 Oct 24;19:198. doi: 10.11604/pamj.2014.19.198.4057.
24. Lee C-H, Chou M-C, Yeh H-M. Rectal atresia with rectourethral fistula: a rare anomaly. *World J Pediatr.* 2007;3(02):150–151.
25. Ali Ibrahim I. Transanal End-to-End Recto-anal Anastomosis for Rectal Atresia at Birth. *Annals of Pediatric Surgery*, Vol 2, No 3-4, July- October 2006, PP 180-183.
26. Levin MD, Mendelson G. Late diagnosis of congenital anal canal stenosis. Case report and literature analysis. *Gastroenterol Hepatol Open Access.* 2024;15(4):126–129. DOI: 10.15406/ghoa.2024.15.00589
27. *Pediatric X-Ray Diagnosis* by John Caffey. - Chicago: Springer, 1978-p. 976.

28. LOUW JH. Congenital intestinal atresia and stenosis in the newborn. Observations on its pathogenesis and treatment. *Ann R Coll Surg Engl.* 1959 Nov;25(4):209-34. PMID: 14418455; PMCID: PMC2413911.
29. Nobles VP. The development of the human anal canal. *Journal of Anatomy*, 1984, 138, 573
30. Kromer P, Korzeniowska-Kromer E. Anal canal development in the embryonic and early foetal period. *Folia Morphol.* Vol. 62, No. 3, pp. 285–287
31. BROWNE D. Some congenital deformities of the rectum, anus, vagina and urethra. *Ann R Coll Surg Engl.* 1951 Mar;8(3):173-92.
32. Levin MD. [The pathological physiology of the anorectal defects, from the new concept to the new treatment]. *Eksp Klin Gastroenterol.* 2013;(11):38-48. Russian. PMID: 24933978.
33. Clayden GS, Lawson JO. Investigation and management of long-standing chronic constipation in childhood. *Arch Dis Child.* 1976 Dec;51(12):918-23. doi: 10.1136/adc.51.12.918. PMID: 1015844; PMCID: PMC1546146.
34. Duhamel B. Physio-pathology of the internal anal sphincter. *Arch Dis Child.* 1969 Jun;44(235):377-81. doi: 10.1136/adc.44.235.377. PMID: 5785186; PMCID: PMC2020287.
35. Levitt MA, Peña A. Anorectal malformations. *Orphanet J Rare Dis.* 2007 Jul 26;2:33. doi: 10.1186/1750-1172-2-33. Erratum in: *Orphanet J Rare Dis.* 2012;7:98.
36. Kraus SJ, Levitt MA, Peña A. Augmented-pressure distal colostogram: the most important diagnostic tool for planning definitive surgical repair of anorectal malformations in boys. *Pediatr Radiol.* 2018 Feb;48(2):258-269. doi: 10.1007/s00247-017-3962-2.

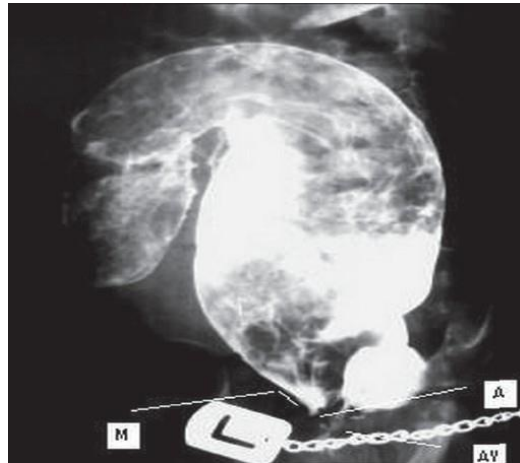
Additional materials

First group

Hosseini SM, Ghahramani F, Shamsaefar A, Razmi T, Zarenezhad M. Wind sock deformity in rectal atresia. *Saudi J Gastroenterol.* 2009 Apr;15(2):133-4. doi: 10.4103/1319-3767.48974.

A two-year-old girl was admitted to the hospital with severe constipation that began after birth. A two-year-old girl was admitted to the hospital with severe constipation that began after birth. Rectal examination revealed a 1.5 cm rectal pouch. She underwent a loop sigmoidectomy with

postoperative proximal and distal irrigation to remove massive tarry stool. Postoperative distal loop colonography revealed a membrane protrusion with a tiny hole (Figure). A small clamp was passed through tiny central aperture via anal canal, and a large rectal tube was easily pulled through the central hole, which made the membrane rupture.



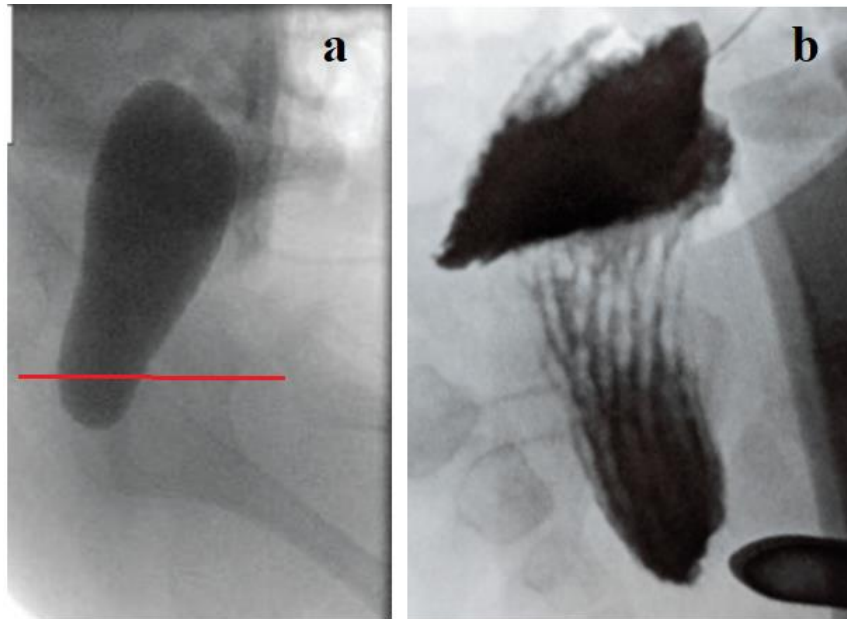
Signature for the radiograph: M-membrane, A-aperture, AV-anal verge.

Conclusion: The x-ray shows that the opening of the membrane is close to the anus. Passing the tube through the opening of the membrane using a clamp from the anal approach confirms the opinion that the membrane was in the middle of the anal canal.

Second group

Kurashima M, Joshi S, Sobrino J, Blewett C. Rectal Atresia Treated Via a Transanal and Posterior Sagittal Approach: A Report of Two Cases. *Cureus*. 2023 May 8;15(5):e38694. doi: 10.7759/cureus.38694.

A one-day-old male was born with a weight of 980 g. and with multiple defects. Meconium had not passed since birth, and abdominal distention was noted on the first day. The anus was in the normal position. A feeding tube inserted in the anal canal met resistance at approximately 1.5 cm from the anal opening without passage of the meconium. His abdominal X-ray was relevant for diffuse intestinal and colonic dilation. The patient was diagnosed with rectal atresia, and a sigmoid colostomy was created. "At the age of 10 months when the patient weighed 8.4 kg. His preoperative distal colostogram showed a blind-ended rectum without any evidence of a fistula, as seen." PSARP was performed.

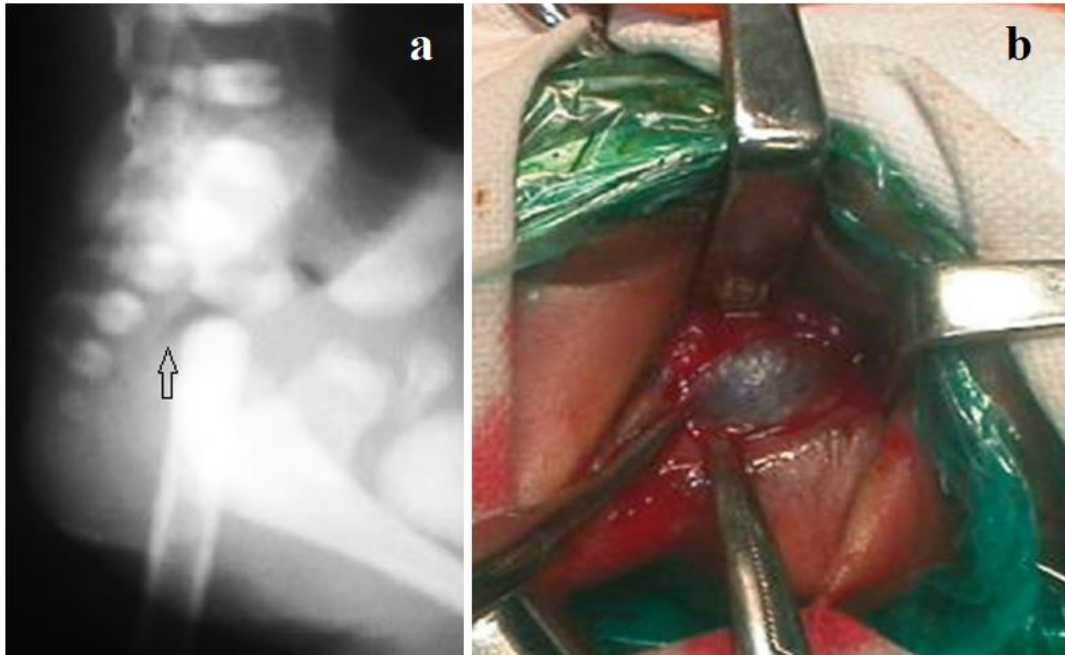


(a) I drew a pubococcygeal line (red), which showed that the intestinal obstruction was in the anal canal, not the rectum. (b) When a Hegar dilator was inserted into the anal canal, a narrow band was identified between the upper and lower portions of the intestine, consistent with the concept of rectal atresia. However, this zone was located at the level of the last sacral vertebra. This could be explained by the fact that the pressure exerted by the Hegar dilator resulted in the intestine and/or membrane being elevated.

Conclusion. Research indicates a membrane in the anal canal, but without a marker near the anus and with the use of the Hegar dilator, the exact location of the membrane could not be determined.

Jayaswal S, Shah H, Murthy K, Bhandarkar K, Makhija OP. Membranous variety of rectal atresia - primary management in a neonate. J Minim Access Surg. 2010 Oct;6(4):114-5. doi: 10.4103/0972-9941.72598.

A three-day-old girl was hospitalized with moderate abdominal distension and there was no meconium passage. On examination, the anus was normal, but a red rubber catheter could not be inserted beyond 3 cm from the anal verge. An X-ray revealed the catheter was resting on an air column in the intestine (a). An endoscopy was done with a 7.5F cystoscope. About 3 cm from the anal verge, the anal canal ended blindly, and a membrane was visualized at the blind end (b). A transanal membranectomy was performed.

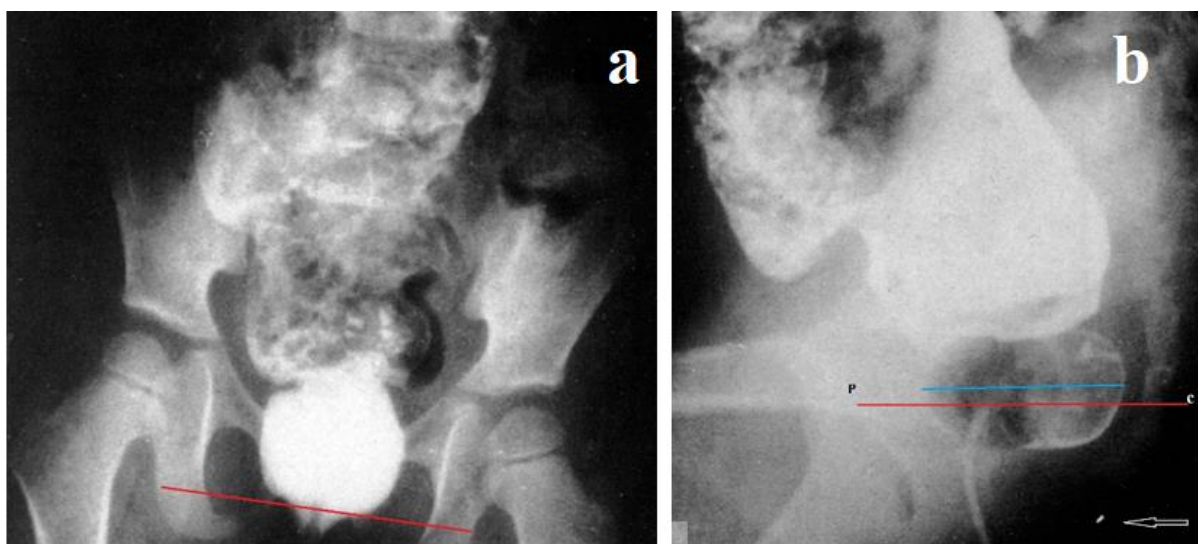


(a) The tip of the red rubber catheter is located well above the distal coccygeal vertebra. The black arrow shows that the catheter has lifted the membrane above the point where the intestine terminates above the membrane. This indicates that the true location of the membrane is lower than the tip of the catheter. (b) The membrane is visible from the anus without dissecting the perineal tissue.

Conclusion. According to the authors' description, the membrane was located approximately 3 cm away. However, many examples showed that the distance measured with a finger or rigid probe determines obstruction 2 cm above the dentate line, when accurately measured, turned out to be 0.7 cm from the anal verge. The radiograph shows that the rigid catheter lifted the membrane and pelvic floor muscles more cranially than their true position. This suggests that the membrane was located in the anal canal. Secondly, the membrane was visible from the anal approach and removed, which is only possible if it was located in the anal canal. Therefore, the membrane was located in the anal canal, but its exact location could not be determined.

Al-Salem AH, Al-Faraj A, Talwalker V. Congenital rectal stenosis: A simple approach to management. *Ann Saudi Med.* 1994 Jan;14(1):56-7. doi: 10.5144/0256-4947.1994.56.

A 3-1/2-year-old female was referred to hospital because of soiling her pants with liquid stools since birth. On examination, she was found to have mild abdominal distention with palpable fecal masses in the abdomen. A hard fecaloma was palpated in the pelvis on rectal examination, while the rectum was empty. The fecaloma was in the proximal part of the rectum immediately above a diaphragm with a central hole about 3 cm from the dentate line. This was confirmed by a barium enema (Figures) [20].



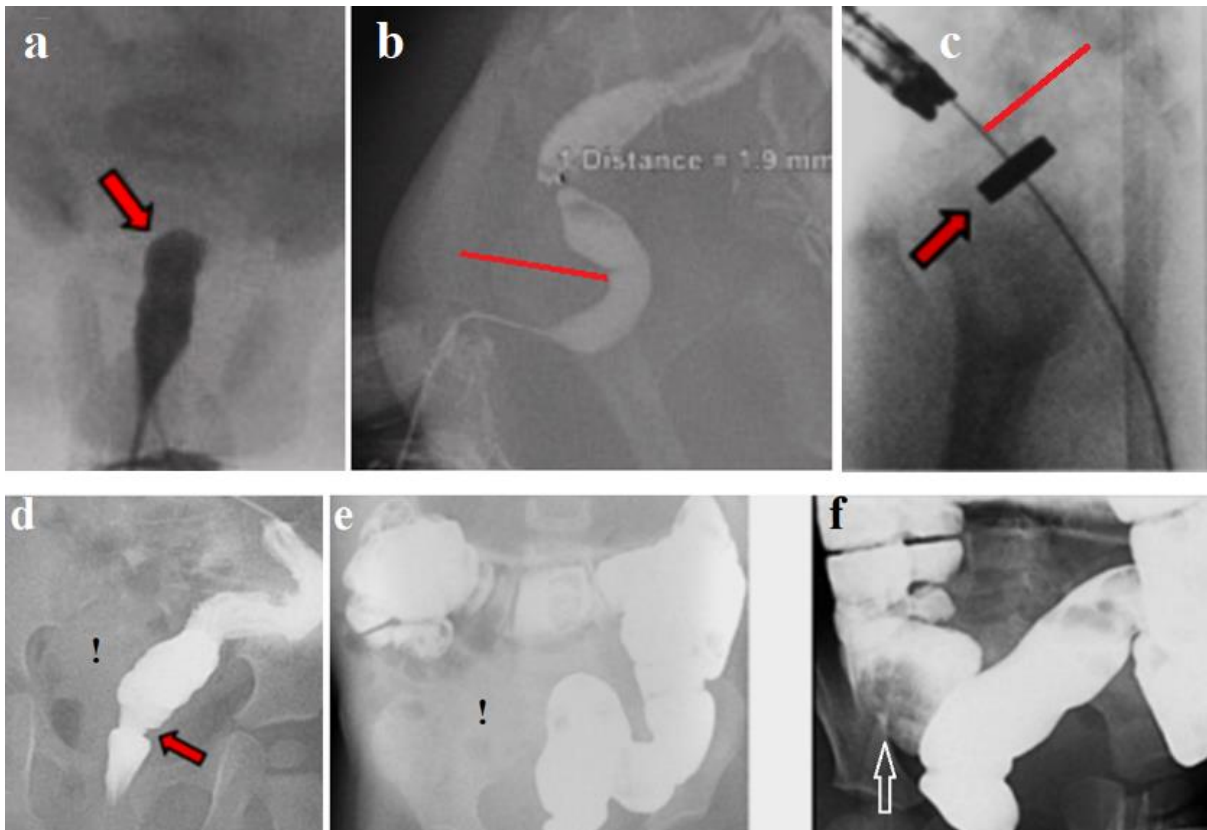
(a) The dilated rectum is above the pubococcygeal line, suggesting that the obstruction is in the anal canal. (b) A Foley catheter was inserted into the rectum. Since the length of the anal canal between the pubococcygeal line (red) and the mark near the anus (arrow) in children of this age is approximately 2.5 cm, the catheter balloon was inflated to a diameter of 4.2 cm. It is partially located below the pubococcygeal line (red), i.e., in the anal canal. However, this does not mean it is above the membrane. Chronic constipation causes stretching of the pelvic floor muscles, known as descending perineum syndrome. A large-diameter balloon cannot penetrate the anal canal. The article does not mention the anal canal. Radiographic analysis shows that the membrane is in the anal canal. Directing the device's rod into the membrane opening with a finger confirms that it was in the anal canal. Surgery: A #28 endoscopic gun (without anvil) was inserted transanally. The shaft was guided with a finger into the opening in the proximal rectum through the opening in the sigmoid colon. The anvil was screwed onto the shaft through the colotomy opening until it aligned with the central opening. The gun was then fired. The head was released, and the entire instrument was withdrawn from the anus. The gun contained a full disk of tissue with a central opening. The analysis indicates that the membrane was in the anal canal, but its exact location has not been established.

Third group

Ajayi AT, Alberti P, Lander A. High rectal atresia anastomosed using magnets: A case report *Journal of Pediatric Surgery Case Reports* 116 (2025) 102978

A full-term baby girl developed abdominal distension and bilious vomiting on the third day of life. Meconium was not passed during the first 48 hours after birth. Upon examination, the

patient's anus appeared normal, but a digital rectal examination revealed resistance at a depth of approximately 3 cm. Based on a contrast enema, the authors diagnosed rectal atresia (a, b). A significant angulation between the proximal and distal pouch was recognized, but its clinical importance was not fully appreciated at first. On post-operative day 5, after some more straining, the patient passed the magnet pair per rectum without blood. A distal colostogram on post-operative day 7 showed that the magnamosis was patent (B).



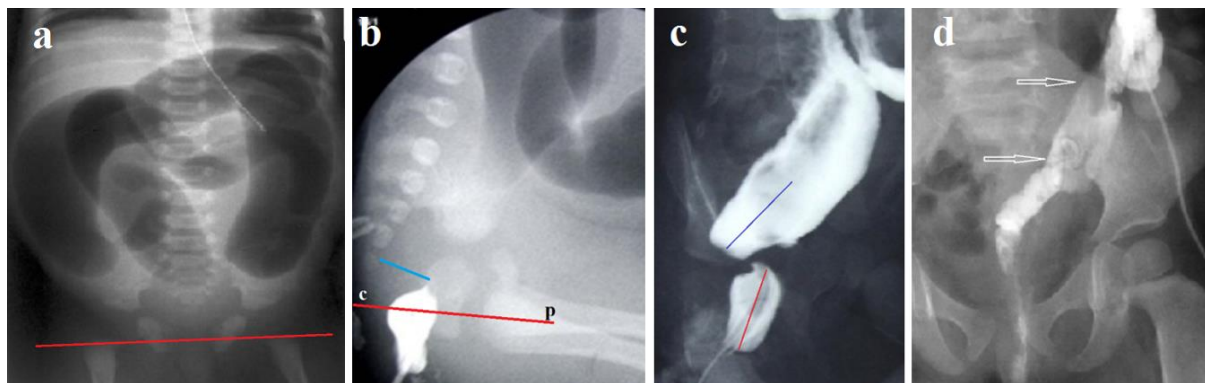
(a) On the 3rd day after birth, the arrow shows the contrast agent stops in the rectum. However, there is no dilated segment of the intestine above the obstruction, which contradicts the diagnosis of rectal atresia. **(b)** During simultaneous contrast from the colostomy and through the anus, a sharp displacement of the rectum anteriorly is visible (red line, caused by a space-occupying lesion located retrorectally). An almost right angle is determined between the rectum and the sigmoid colon, indicating a kink of the intestine at this site. **(c)** Immediately after the introduction of the magnets, no lumen is visible between them. retrorectal space. **(d)** According to the authors, the arrow shows the site of anastomosis. It is located at the level of the femoral head. However, the site of obstruction was located significantly higher. Intestinal stenosis would be possible if the magnets compressed the intestinal wall, but then the lumen between the magnets (c) would be visible and they would not have out on the 5th day. **(e, f)** show a mass

in the right pelvis (!), obscuring the contours of the bones. Figure (f) shows a mass that has displaced the contrast agent in the cecum (arrow).

Conclusion. Obstruction in the sigmoid colon was caused by a space-occupying lesion located retrorectally and on the right side. This caused bowel torsion. The insertion of a guidewire straightened the torsion of the intestine, but the magnets had no therapeutic effect.

Gieballa M, AlKharashi N, Al-Namshan M, AlJadaan S. Outcomes of transanal endorectal pull-through for rectal atresia. BMJ Case Rep. 2018 May 18;2018:bcr2017224080. doi: 10.1136/bcr-2017-224080.

Case 1. In a two-day-old premature boy developed abdominal distension, bile vomiting, and no meconium. A rectal examination revealed a normal anus. **(a)** Abdominal radiography revealed dilated bowel loops without gas in the distal portion. **(b)** A contrast enema showed that the contrast medium did not pass more than 2 cm above the anus. Laparotomy was performed at the age of 3 days. The large bowel was massively dilated, and a rectal web was identified and opened through enterotomy in the rectum. Right transverse colostomy was performed. Follow-up distal loopography revealed persistent distal obstruction **(c)**. Thus, transanal resection of the atretic rectum with primary anastomosis was performed at 7 months of age. **(d)** Postoperative distal loopography.

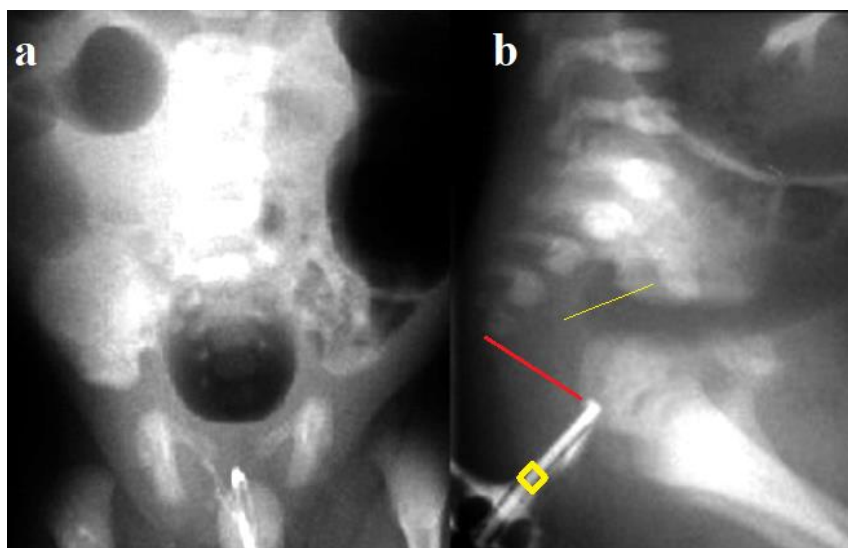


(a) Dilatation of only the colon is determined, which ends blindly above the pubococcygeal line. Bilious vomiting and the absence of gas in the small intestine indicate intestinal volvulus. **(b)** On the lateral radiograph, the anal canal and part of the rectum with a "forelock" are filled with contrast agent. The retrorectal space is dilated (blue line). The dilated sigmoid colon narrows towards the rectum but is located at a large distance from it. **(c)** The authors wrote that they opened the rectal membrane. But the radiographic picture has not changed. The same "forelock" is preserved. The anorectal axis (red) does not coincide with the axis of the sigmoid colon. **(d)** This radiograph contradicts the description of the case: instead of a stoma on the

transverse colon, a stoma is seen in the left iliac region. A significant part of the left half of the colon was removed. A conduit, likely from the small intestine (between the arrows), is inserted into the shortened portion. The anal canal is not functioning.

Conclusion. In this case, there are no signs of rectal atresia. Clinical and radiographic findings suggest intestinal volvulus. Given the widening of the retrorectal space, abdominal mass is the most likely cause of intestinal obstruction. The discrepancy between clinical history and radiographic findings makes this case questionable.

Case 2. The preterm male baby was hospitalized at the age of 3 days with progressive abdominal distention and failure to pass meconium. "A rectal catheter could not be inserted more than 2 cm above the dentate line". Further, study is described as follows: - "Contrast enema showed failure of the contrast to pass more than 2 cm above the anal verge" (Figure a,b). After colostomy, transanal endorectal anastomosis was performed at the age of 6 months. He gained complete bowel control around 5 years of age with intermittent constipation that was controlled well with laxatives. On further follow-ups, he was diagnosed with neurogenic bladder disorder. The cystourethrogram test showed dysfunctional posterior urethral valves.



(a) The end of the catheter is located above the pubococcygeal line, i.e., in the rectum. The dilated intestine is visible above it. (b) The lateral radiograph reveals a marked widening of the retrorectal space (red line), with anterior displacement of the anal canal by the mass lesion. The axis of the dilated rectum (yellow line) is displaced posteriorly relative to the axis of the anal canal. Since the true length of the anal canal in premature infants is ≈ 1.5 cm, it is easy to calculate the location of the anus if the infant were normal. This location is marked with a

yellow square. This indicates that the mass lesion not only displaced the anal canal anteriorly but also pushed the anus caudally.

Conclusion. There is no evidence of rectal atresia in this case. The obstruction of the digestive tract was caused by a mass that pushed the anal canal forward, leading to a kinking of the intestine and obstruction of its lumen. Analysis of the description suggests that the authors of this article, like some others in this review, mistakenly refer to the mucocutaneous junction of the anal verge as the dentate line.