

Reflexes of anorectum

M. D. Levin

Anatomy anorectum . The anorectum and pelvic floor are crucial in maintaining continence, facilitating evacuation, providing pelvic organ support. The anal canal is a multilayered cylindrical structure, including the smooth muscle internal anal sphincter (IAS) and the striated muscle layer. The latter comprises the external anal sphincter (EAS) as the lower outer half and puborectalis muscle (PRM) as the upper outer half of the anal canal. The pelvic floor constitutes four principal layers: endopelvic fascia, the muscular pelvic diaphragm (commonly referred to as levator ani muscle (LAM) or levator plate), the perineal membrane (urogenital diaphragm), and the superficial transverse perineii. Anorectum and pelvic floor have multiple interconnections by fascia and ligaments as well as multiple indirect connections to the bony pelvis. Other structures as the perineal body and a fibro-elastic network add to this support [1] (**Figure 1**).

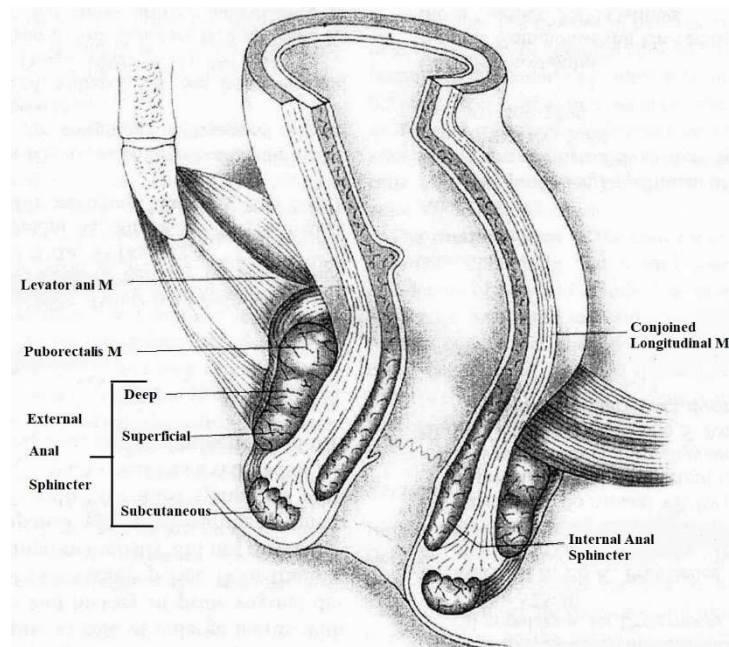


Figure 1. From the Textbook [1].

Reflex definition. A reflex action or reflex is a biological control system linking stimulus to response and mediated by a reflex arc. The primary components of the reflex arc are the sensory-nerve cells (or receptors) that receive stimulation, in turn connecting to other nerve cells that activate muscle cells (or effectors), which perform the reflex action.

History of the issue. In 1877 Gowers found that injection of air into the rectum causes a decrease in the anal canal pressure [2]. As shown by numerous studies, reducing the pressure in the upper part of the anal canal is due to the IAS relaxation (rectoanal inhibitory reflex- RAIR) [3,4,5]. It was found that a pacemaker located in the most gut [6]. This reaction corresponds to the gut law of Bayliss and Starling. The peristaltic contraction carried out by the local nervous mechanism (Auerbach's plexus). The law of the intestine is as follows: - Local stimulation of the gut produces excitation above and inhibition below the excited spot [7]. Lin and Chen found RAIR in patients with anorectal malformations after none internal sphincter-saving surgery [8]. This confirms the view that an increase in pressure in the neorectum (the rectum or sigmoid colon), causes relaxation in the neoanus (the rectum or sigmoid colon), that is, this reaction of any intestine, not just IAS.

Manometric studies were mainly performed by pediatric surgeons for the differential diagnosis of Hirschsprung's disease and functional constipation. The diagnostic test was the IAS reaction to the inflation of the rectal balloon. A drop in pressure in the anal canal because of relaxation of the IAS indicated normal innervation of the rectum and reliably excluded Hirschsprung's disease. These studies indicate that RAIR is coordinated exclusively by the intramural nervous system, is not associated with extraintestinal centers, does not have a reflex arc, and is therefore not a reflex scientifically.

In a fundamental study, Porter proved that contraction of the EAS and PRM "...in response to rectal distension are reflex in origin, the afferent impulses travelling via the pelvic autonomic nerves" [9]. These results have been confirmed in

studies by other authors [3,4,5, 10,11]. A great contribution to the understanding of the processes of continence and defecation was made by Shafik. His research is unique in its simplicity and scientific purity [10,11]. In each identified reflex A.Shafik emphasizes its appropriateness. Surprisingly, the articles of Porter, Shafik et al are almost never quoted. The works dominate in the Internet where authors who are using new devices report the discoveries of "new" reflexes, which have already been described [12,13,14]. Since these works do not meet the criticism of authoritative scientists, the number of fake articles began to prevail, and they are published in PubMed much more often than scientific works. До сих пор, широко тиражируются мнения, которые противоречат известным научным фактам

Thus, for example, there is an unfounded opinion among pediatric surgeons that PRM does not play an important role in fecal retention [15]. The aim of the work is to study and analyze the anorectum reflexes described in the literature.

1. Postural reflex.

Porter proved for the first time that "the pelvic floor muscles are unique in that they are continuously activity at rest", even during sleep. He believed that all other striated muscles show no electrical activity of this type when at rest. In patients with tabes dorsales with destruction of the dorsal horn ganglion cells, Porter discovered interrupts afferent impulses from visceral receptors and from proprioceptive receptors in muscle. In these patients, no resting activity is seen in the pelvic floor muscles, but the appearance of normal potentials on voluntary contraction demonstrates the integrity of the motor pathway. Thus, he proved the presence of a spinal reflex, which provides constant tone to the striated muscles of the pelvis floor. He proved that continuous resting activity requires constant sensory impulses from the pelvis [9].

Physiological role. Postural reflex help to support the weight of the pelvic viscera and help in the preservation of continence at rest [16].

Voluntary contraction produces a marked increase in activity in the external sphincter. This direct cortical effect is at best sustained for not more than a minute [8]. The reflex contraction of the EAS in response to high rectal pressure lasts no more than 9-15 seconds [17].

Thus, we see that the EAS is subject to two different reflexes. In one case, it is in continuous contraction at rest without significant shortening of muscle fibers (tonic contraction under the control of the postural reflex). In another case, it contracts sharply, but like all striated muscles, it quickly gets tired and relaxed (mechanical contraction).

Physiology. Contraction of the muscle fibers is a "work" accompanied by energy consumption, without its renewal muscle, cannot continue to contract. Following the contraction inevitably the muscle relaxation must arise, during which the muscle restores its capacity for subsequent contraction. It is known that the sheaves of smooth muscle fibers anastomosing with each other forming a tightly knit group of fibers, which operate together [18].

Tonic prolonged contraction of the LAM, PRM, and EAS explained by postural reflex [9, 18,19]. Each nervous axon has a connection to the muscle groups scattered throughout the muscle. Therefore, even a small amount of the contracted muscle groups results in a contraction of the whole muscle. The muscle tone is dependent on the number of groups participating in the contraction, i.e. from the percentage of axons activating muscle contraction. The prolonged tonic contraction is due to the continuous replacement of the axons activating the different groups of muscle fibers. At a different time, the different groups of muscle fibers are contracted. At this moment, other muscle fibers restore their contractile potential. All the striated pelvic floor muscles can be involved in mechanical contraction. In such cases, all muscle groups contract simultaneously. Therefore, the force of contraction is much greater than with tonic contraction, but the duration of the contraction is less than 1 minute. The contraction of the circular muscles of the EAS causes a sharp increase in anal pressure. The

contraction of the PRM pulls the upper part of the anal canal to the pubis [20,21,23]. And the levator plates open the anal canal widely during defecation [17].

II. Continence reflex

This reflex is caused by the stretching of the rectal wall. It consists of three related reactions. (1) Stretching the rectum induces a relaxation of the IAS called the rectoanal inhibitory reflex (RAIR), but which, as explained above, it is not scientifically a reflex. (2) Simultaneously with the relaxation of the IAS, a reflex contraction of the EAS and PRM occurs [3,4,5,6,10,11,17,20,21,22,23]. (3) The EAS tone progressively decreases within 8-15 seconds, after which the pressure in the rectum decreases [9]. Shafik and el Sibai showed that the contraction of the EAS occludes the anal canal for a few seconds - enough for the rectum to relax in a reflex manner as an effect of the "voluntary anorectal inhibitory reflex" [10,23].

Physiological role. A slow peristaltic wave delivers fecal boluses into the rectum, which causes the rectal wall to stretch (**Figure 2.a**). This results in relaxation of the IAS and the pressure in the anal canal decreases. However, the contraction of EAS and PRM prevents the possibility of involuntary defecation. A narrow space forms between the rectum and the upper part of the anal canal, into which only gas and liquid can enter. Due to the contraction of the PRM, an acute anorectal angle is formed, which prevents the penetration of the formed dense feces into the anal canal (**Figure 2.b**).

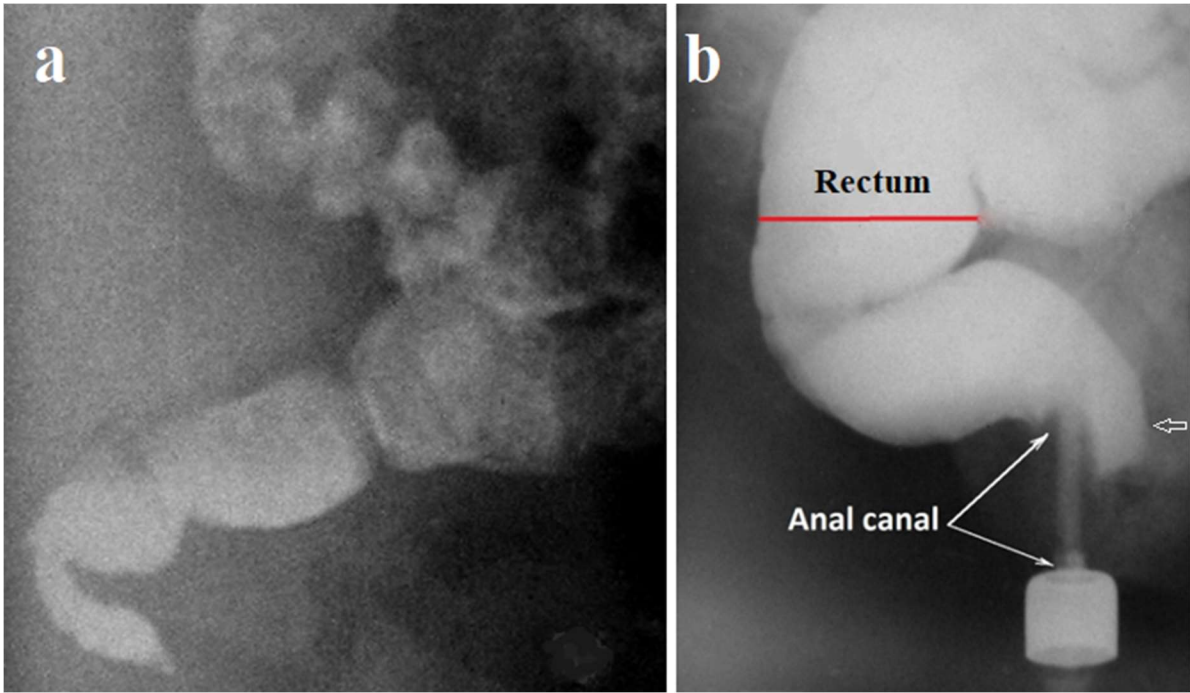


Figure 2. Lateral radiographs of anorectum in the fecal retention phase. (a) The radiograph performed 24 hours after oral administration of barium (passage). During the slow promotion across the rectum, the fecal portions decrease in volume and become more contrast (denser) because of fluid absorption by the rectal wall. (b) During the contrast enema, because of IAS relaxation, barium penetrated the upper part of the anal canal in front of the enema tip (arrow). At this time, the posterior wall of the anal canal is pressed against the tip of the enema by the contracted PRM, which pulls the upper part of the anal canal forward and creates an acute anorectal angle.

In the mucosa at the upper part of the anal canal, there are sensors that allow distinguishing the liquid from the gas. In the presence of gas is enough to strain the abdominal wall to increase rectal pressure and expel gas through the lower part of the closed anal canal. When the liquid feces penetrate the upper part of the anal canal the tone of the EAS and PRM increases, which leads to compression of the IAS and crowding out of the fluid from the anal canal into the rectum, which relaxes, adapting to the new rectal volume [9,10]. The contracted PRM, which pulls the upper part of the anal canal forward and creates an acute anorectal angle, does not allow the dense feces to enter the anal canal. The rectal pressure drops, resulting in the contraction of the IAS and relaxation of the PRM and EAS.

After entering the rectum of another bolus of feces this sequence of reactions is repeated. When the volume of feces reaches a threshold value, rectal pressure rises first to first sensation and then to urgent sensation (**Figure 3**).

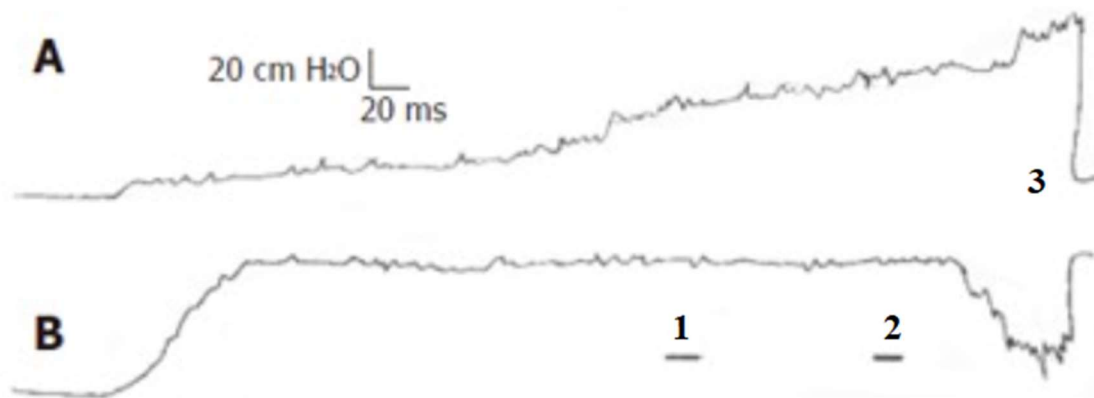


Figure 3. Pressure tracing (rectometrogram) showing the rectal (A) and anal (B) pressure response to balloon rectal distension in increments of 20 mL in 10 seconds. (From an article by Shafik et al [10]). (1) – first sensation, (2) –urgent sensation; (3) – defecation.

Thus, the continence reflex performs important functions in the long-term phase of the continence. Firstly, a continuous analysis of the contents of the rectum is carried out and the individual receives information about the problems. Secondly, the rectum gradually adapts to an ever-increasing volume without an increase in rectal pressure, which contributes to the long-term accumulation of feces without the urge to defecate. Third, different sphincters are contracted at different times. When the IAS contracts, the striated muscles relax and restore the ability to contract again. At a time when the EAS and PRM are contracted, the IAS restores its contractile potential.

Reflex arc. Analyzing the process of prolonged fecal retention, we see that one stimulus, that is, an increase in pressure in the rectum to a certain level, causes 3 reactions. (1) The relaxation of the IAS in response to increased pressure in the rectum is mediated by the intramural nervous system. In congenital agangliosis (Hirschsprung's disease), in response to rectal stretching, not a decrease, but an

increase in pressure in the anal canal is recorded. Thus, relaxation of the IAS is not controlled by the extraintestinal center and therefore is not a reflex. (2) An increase in rectal pressure causes a simultaneous contraction of EAS and PRM. The reflex arc from the sensory elements in the rectum conducts a signal to the nerve center, at the S3-S4 level. And from the center along the motor neuron, a signal arrives at the EAC and PRM, causing their contraction [9,10] (**Figure 4**). (3) The decrease in rectal pressure in response to NAS relaxation is probably part of this reflex.

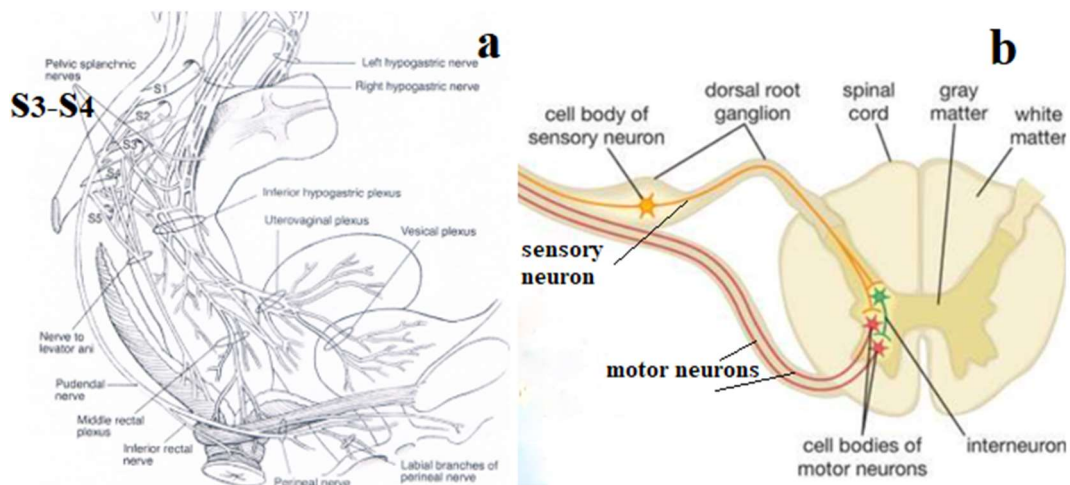


Figure 4. (a) Scheme of the nervous supply anorectum from the article Bharucha [13]. (b) Scheme of the reflex arc.

3. Defecation reflex

The rectum is compliant, i.e. it can accommodate increases in volume with little change in pressure. This allows the rectum to distend in response to incoming fecal, a phenomenon known as adaptive relaxation, which enables it to serve as a temporary storage organ (i.e. its "reservoir" function) [16]. However, the process of adaptation of the rectum to the ever-increasing volume of feces has a border, after which the next portion of feces causes an increase in rectal pressure, which is felt as a need for defecation. Shafik et al found that in many healthy subjects, stools could be palpated in the rectum by digital rectal examination without the subject feeling the desire to defecate [11]. In another study, Shafik et al investigated two types of defecation [10].

Rectal balloon distension with 200 mL of normal saline in 10 s resulted in a significant increase of the rectal pressure and a decrease of the anal pressure. The balloon was expelled to the exterior. The mean rectal pressure was 63.4 ± 8.2 cm H₂O, and the mean anal pressure was 22.4 ± 2.6 cm H₂O. The subjects felt the urgent sensation followed by balloon expulsion but did not feel the first rectal sensation. When the subject upon feeling the urgent sensation, was asked to squeeze the anal sphincters for seconds, the mean anal pressure rose to 146.8 ± 16.2 cm H₂O, resulting in the disappearance of the urgent sensation and a significant decrease in the rectal pressure to 10.8 ± 1.1 cm H₂O. The balloon was not expelled but stored in the rectum. After a few seconds, however, if the patient was asked not to squeeze the sphincters, the urgent sensation recurred, and the balloon was expelled.

During rectal filling with a small volume (20 mL in 10 s), rectometrograms were produced (See Figure 2). The mean rectal balloon distending volume was 78.3 ± 16.6 mL at the first sensation and 152.6 ± 18.9 mL at the urgent sensation. The mean rectal pressure was 51.7 ± 9.8 cm H₂O at the 1st rectal sensation and 62.9 ± 14.2 cm H₂O at the urgent sensation, while the mean anal pressure was 70.6 ± 5.2 cm H₂O and 18.7 ± 2.3 cm H₂O, respectively.

Pressure tracing shows a slight increase in rectal pressure before the injection of about 80 ml of fluid into the rectal balloon, which led to an increase in pressure up to 60 cm H₂O. At this time, the first sensation (1) appeared. Subsequent expansion of the rectal balloon led to a progressive increase in pressure until, after injection of about 150 ml, the urgent sensation (2) appeared at a pressure of about 70 cm H₂O. Anal pressure increased immediately after the introduction of the first 20 ml portion and was the same throughout the study. Defecation was accompanied by a sharp rise in rectal pressure and a drop in pressure in the anal canal.

Based on these studies, the following conclusions can be drawn. First, the authors confirmed a previously published study that the contraction of the EAS occludes the anal canal for a few seconds - enough for the rectum to relax in a reflex manner as an effect of the voluntary anorectal inhibitory reflex [23]. Secondly, it has been proven that IAS and EAS relax during defecation since they have EMG activity disappeared [9]. Third, they found that rectal sensitivity and reflexes were dependent on rectal pressure. Fourth, the healthy individuals have a certain threshold pressure, which causes rectal sensation, as well as a higher threshold pressure, which causes an urgent need for defecation and stimulates the defecation reflex.

There are no voids in the pelvic floor, so relaxation of the anal sphincters (IAS, EAS, and PRM) cannot lead to the formation of a wide anal canal in the perineum, as is observed with a contrast enema (**Figure 5**). If defecation occurred only when the sphincters were relaxed, then the liquid contents of the rectum would come out through a narrow channel. Secondly, the statement that during defecation there is a relaxation of the pelvic floor, by which the levator plates are meant, is not proven and contradicts logic. At rest, the levator plates are in a tonic state. They do not participate, i.e. do not contract, during the retention of feces. What work do they do during the contraction?

The prevailing assumption in the literature is that “Relaxation of the pelvic floor coupled with high intraabdominal pressure causes it to descend [16, 19]. However, this hypothesis contradicts scientific evidence, since ‘The pubovisceral muscles, in addition to supporting the pelvic viscera, can also by active contraction draw these viscera upwards and forwards’ [24].

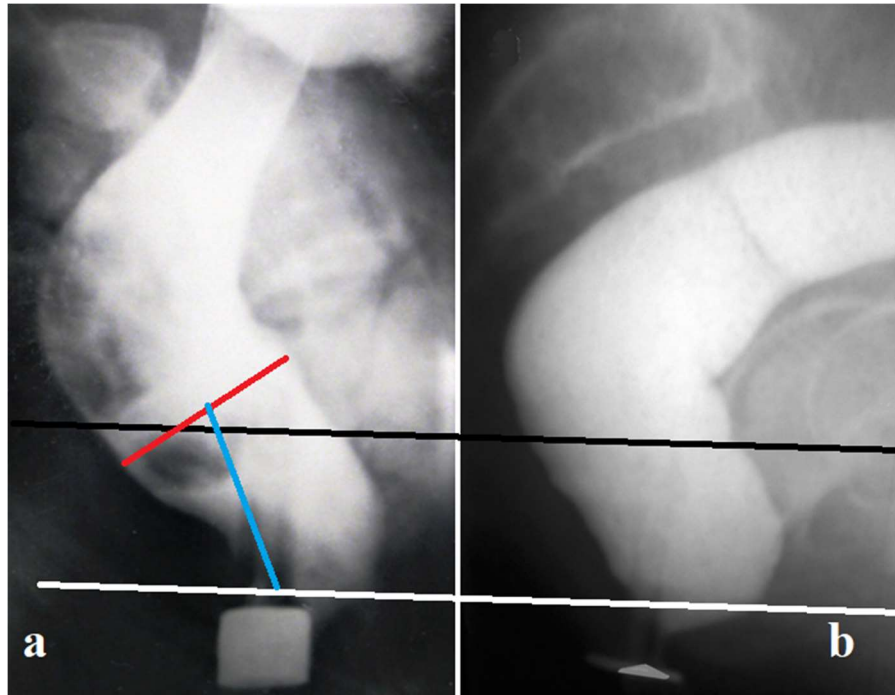


Figure 5. During defecation, between the rectum (black line) and the anus (white line), a cylindrical canal appeared in the tissues of the pelvic floor in place of the previously closed anal canal. Since it is known that the width of the contrast marker near the anus is 1.6 cm, the width of the cylinder (red line) is 3.5 cm, and its length is 3.4 cm. The approximate volume of this not quite regular cylinder is about 30 cm³.

Muscles, in general, have a relatively simple function; they shorten as they contract. Since the posterior ends of the LAM are attached along the posterior semicircle of the pelvic ring, and the anterior ends are attached to the posterior and lateral walls of the longitudinal muscle and EAS, then during mechanical contraction of the LAM, the posterior and lateral walls of the anal canal are stretched, revealing the anal canal to the width of the rectum, which is accompanied by the disappearance of the anorectal angle [17] (**Figure 6**).

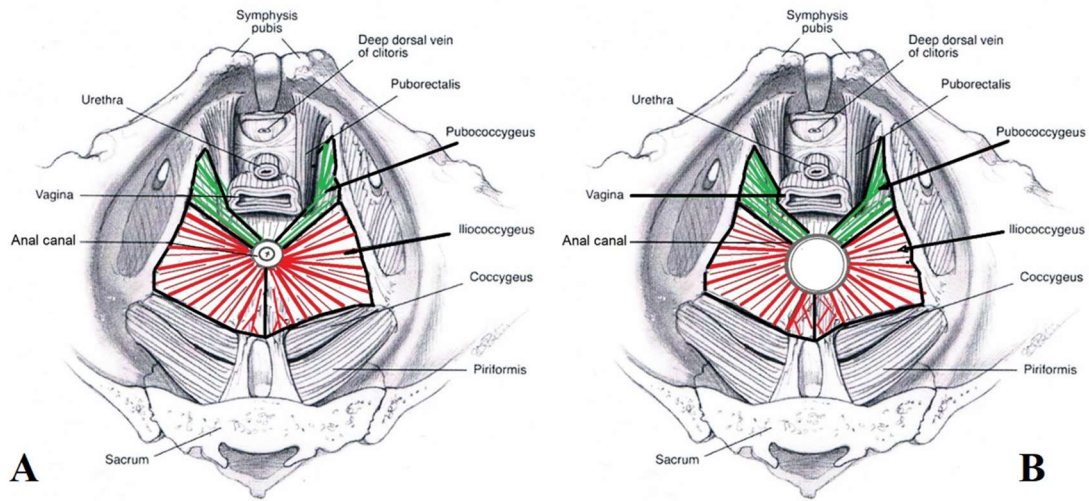


Figure 6. Scheme cross-section of the anorectal region at the level of the deep portion of the EAS. A scheme from the article of Bharucha [21] was used. (A). At rest anal canal is in a closed state. (B). During defecation, the anal canal opened because of the contraction of LAM (pubococcygeus and iliococcygeus).

Professor Shafik and his colleagues have shown in a series of articles that the LAM during contraction participates in the defecation reflex [25,26,27]. On LAM electrostimulation, found that the anal pressures had a significant decline. Since LAM contraction lowers the anal pressures, hence it assists in the evacuation process. They, therefore, propose that the LAM is a muscle of evacuation [10]. In another article, they affected by a needle EMG electrode at PRM и LAM. The stimulation of these muscles produced a no-pressure response in the empty rectum. Upon rectal balloon distension with a mean of 156.6 ± 34.2 ml, the mean rectal pressure was 64.6 ± 18.7 cm H₂O, the subject felt the urge to evacuate and the balloon was expelled to the exterior. On PRM stimulation at rectal distension with the above volume, the subject did not feel the urge to evacuate, the rectal pressure was 8.2 ± 1.6 cm H₂O and the balloon was not expelled. Upon LAM stimulation at the same volume, the urge persisted, the rectal pressure was higher, and the balloon was expelled [27]. Thus, it was shown that stimulation of LAM leads to an increase in rectal pressure and a decrease in pressure in the anal canal, which promotes the process of defecation.

CT defecography showed that the mean area of the genital hiatus was 1,762 mm² at rest, 1,332.4 mm² during squeeze, and 3,126.8 mm² during defecation. It was found that the LAM does not lift the anus; its main function is to open the genital hiatus and the anus during defecation [28]. Bush et al studied normal defecation with video proctography or magnetic resonance imaging. They showed that during defecation the anorectal luminal diameter increases to approximately twice its resting size. If the effective diameter of the anus is doubled, the frictional resistance is reduced by a factor of 8 [29].

Shafik and his co-workers found that anal balloon distension affected notable rectal pressure increase. Distension of the anal canal during bowel movements led to the complete evacuation of fluid from the rectum. After anal anestheztion residual fluid was huge. Rectal contraction at defecation is suggested to be maintained by positive anorectal feedback evoked by continuous passage of stool through the anal canal [30,31].

Role of the rectum. It has been shown above, the stimuli that excite both reflexes (fecal retention and the defecation), act on the rectal receptors. They respond to rectal pressure. The pressure in the rectum determines which reflex will work. "Six cm. of the lower rectum (in adults) appears to be adequate; rectal sensation is preserved, normal responses to filling occur and continence is maintained". "The sensory receptors are necessary for normal coordinated defecation. These receptors are absent from the sigmoid colon" [9].

Role of the striated muscles (EAS and PRM). When measuring anal pressure "The difficulty is that any pressure changes recorded will be the sum of the activities of both external and internal sphincters" [9]. Therefore, it is impossible and meaningless to judge the percentage of the contribution in stool retention of any of the sphincters. The sequence of contraction of different sphincters in the process of keeping feces is controlled by a program emanating from the S2-S4 of the spinal cord. During bowel movements, they relax, as evidenced by the absence of electrical activity [9].

Description of the fecal continence reflex.

At rest, the IAS and striated muscles of the pelvic floor are in a state of tonic contraction. They help to support the pelvic organs and participate in the continuous retention of feces. The pressure in an empty rectum is equal to the intra-abdominal pressure. It is basal rectal pressure (BRP). Its absolute indices are irrelevant, because, firstly, in different articles, they differ significantly from each other, and, secondly, intrarectal catheters distort the true functional characteristics. When the fecal bolus penetrates from the sigmoid colon into the rectum, it stretches the wall of the rectum and rectal pressure increases above the BRP. This pressure we called the threshold pressure of the first-order (TP-1). It causes a reflex relaxation of the IAS and contraction of the EAS and PRM. The PRM during contraction pulls forward the upper part of the anal canal, pushing the back wall against the front. Inside the PRM loop, the anal pressure decreases because of the IAS relaxation. In the upper part of the anal canal, there is a narrow channel arises through which the gas and liquid feces can penetrate the upper part of the anal canal. In the mucosa at this level, there are sensors that allow distinguishing the liquid from the gas. The presence of gas is enough to strain the abdominal wall to increase rectal pressure and expel gas through the lower part of the closed anal canal. When the liquid feces penetrate the upper part of the anal canal the tone of the EAS increase, which leads to a compression of the IAS and crowding out of the fluid from the anal canal into the rectum. The contraction of EAS causes a reflexive decrease in rectal pressure up to BRP, resulting in the contraction of the IAS and relaxation of the PRM and EAS. During this reflex, the dense stool remains in the rectum due to the acute anorectal angle and the narrow hole between the rectum and anal canal. After entering the rectum of another bolus of feces this picture is repeated. It can be observed up to seven per hour. During IAS relaxation, its muscle fibers restore contraction ability. In this period, the fecal retention is performed by the PRM and EAS contraction. During

the rise of the intra-abdominal pressure (rise from the spot, cough, etc.), the reflex contraction of striated sphincters occurs.

When the volume of stool in the rectum reaches a certain value, the rectal pressure rises from TP-1 to the threshold pressure of the second order (TP-2), in which a need for a bowel movement appears. If this need does not coincide with the possibility of its implementation, the rectum continues to relax to a limited extent. At the same time, there is an increase in the tone of the recto-sigmoid sphincter, which prevents the further penetration of feces from the sigmoid colon into the rectum [33].

Description of the defecation reflex. The defecation reflex involves the simultaneous contraction of the rectum, and the LAM, as well as relaxation of the IAS, EAS, and PRM in response to an increase in rectal pressure to the third order (TP-3). After defecation is completed the voluntary sphincters contract activity and normal postural tone is restored.

4. The anal reflex.

The anal reflex is caused by perianal skin stimulation, which leads to an increase in EAS activity, both in normal patients and in patients with paralysis of the lower extremities [9]. The study by Shafik et al has shown that rectal tone increase during digital perineal pressure represents most probably a reflex action [33]. This reflex can be used to diagnose and treat newborns with ARM without a visible fistula. Pressure in the anal dimple can cause the ectopic anal canal to open if enough gas and meconium has accumulated in the rectum to trigger a defecation reflex by the TP-3.

M.D. Levin, MD, PhD, DSc. Radiologist,

nivel70@hotmail.com; michael.levin@dorot.health.gov.il

<https://www.anorectalmalformations.com>

References

1. Anatomy and Embryology of the Colon, Rectum, and Anus. From The ASCRS Textbook of Colon and Rectal Surgery. by J.M.N. Jorge and A Habr-Gama. 2017. p. 1-22.
2. Gowers WR. The autonomic action of the sphincter ani. Proceedings of the Royal Society (London). 1877;26:77-81.
3. Schuster MM, Hendrix TR, Mendeloff AL. The internal anal sphincter response: manometric studies on its normal physiology, neural pathways, and alteration in bowel disorders. *J Clin Invest.* 1963 Feb; 42:196-207.
4. Meunier P, Mollard P. Control of the internal anal sphincter (manometric study with human subjects). *Pflugers Archiv.* 1977; 370: 233-9.
5. Rosenberg AJ, Vola AR. A new simplified technique for pediatric anorectal manometry. *Pediatrics* 1983 Feb; 71(2):240-5.
6. Shepherd JJ, Wright PJ. The response of the internal anal sphincter in man to stimulation of the presacral nerve. *Amer J Dig Dis.* 1968; 13: 421-7.
7. Bayliss WM, Starling EH. The movements and innervation of the small intestine. First published: 11 May 1899
<https://doi.org/10.1113/jphysiol.1899.sp000752>
8. Lin CL, Chen CC. The rectoanal relaxation reflex and continence in repaired anorectal malformations with and without an internal sphincter-saving procedure. *J Pediatr Surg.* 1996 May;31(5):630-3. doi: 10.1016/s0022-3468(96)90662-4.
9. Porter NH. A Physiological Study of the Pelvic Floor in Rectal Prolapse Arris and Gale Lecture delivered at the Royal College of Surgeons of England on 1st November 1960. *Ann R Coll Surg Engl.* 1962 Dec; 31(6): 379–404.
10. Shafik A, Mostafa RM, Shafik I, et al. Functional activity of the rectum: A conduit organ or a storage organ or both? *World J Gastroenterol* 2006 Jul 28;12(28):4549-52. doi: 10.3748/wjg.v12.i28.4549.
11. Shafik A, Ali YA, Afifi R. Is the rectum a conduit or storage organ. *Int Surg.* 1997;82:194–197.
12. Jonker LE, Trzpis M, Broens PMA. Fecal Continence for Solid and Liquid Stool: The Function of the Anal-External Sphincter Continence Reflex and the Puborectal Continence Reflex. *Dis Colon Rectum* . 2020 Oct;63(10):1419-1426. doi: 10.1097/DCR.0000000000001615.
13. Rao SSC. Advances in diagnostic assessment of fecal incontinence and dyssynergic defecation. *Clin Gastroenterol Hepatol.* 2010 Nov;8(11):910-9. doi: 10.1016/j.cgh.2010.06.004.
14. De Ocampo S, Remes-Troche JM, Miller MJ, Rao SSC. Rectoanal sensorimotor response in humans during rectal distension. *Dis Colon Rectum.* 2007 Oct;50(10):1639-46. doi: 10.1007/s10350-007-0257-y.

15. Levitt MA, Peña A. Anorectal malformations. *Orphanet J Rare Dis.* 2007 Jul 26;2:33. doi: 10.1186/1750-1172-2-33.
16. Palit S1 , Lunniss PJ, Scott SM. The physiology of human defecation. *Dig Dis Sci.* 2012 Jun;57(6):1445-64. doi: 10.1007/s10620-012-2071-1. (PubMed).
17. Levin MD. The role of the external anal sphincter in the physiology of the pelvic floor. *Pelviperrineology.* 2017; 36(4):108-112. (Open access).
18. Histology. By edition A.W. Ham and D.H. Cormack Eighth Edition. 1979. JB. Lippincott Company.
19. Parks AG, Porter NH, Hardcastle J. The syndrome of the descending perineum. *Post. Proc R Soc Med.* 1966 Jun;59(6):477-82. (PubMed). (Open access).
20. Raizada V1 , Bhargava V, Karsten A, Mittal RK. Functional morphology of anal sphincter complex unveiled by high definition anal manometry and three dimensional ultrasound imaging. *Neurogastroenterol Motil.* 2011 Nov;23(11):1013-9, e460. doi: 10.1111/j.1365-2982.2011.01782.x. (PubMed).
21. Bharucha AE. Pelvic floor: anatomy and function. *Neurogastroenterol Motil.* 2006 Jul;18(7):507-19. doi: 10.1111/j.1365-2982.2006.00803.x.
22. Cheeny G1 , Nguyen M, Valestin J, Rao SS. Topographic and manometric characterization of the rectoanal inhibitory reflex. *Neurogastroenterol Motil.* 2012 Mar;24(3):e147- 54. doi: 10.1111/j.1365-2982.2011.01857.x. (PubMed).
23. Shafik A, el-Sibai O. Rectal inhibition by inferior rectal nerve stimulation in dogs: recognition of a new reflex--the 'voluntary anorectal inhibition reflex'. *Eur J Gastroenterol Hepatol.* 2001 Apr;13(4):413-8. doi: 10.1097/00042737-200104000-00019.
24. Lawson JO. Pelvic anatomy. I. Pelvic floor muscles. *Ann R Coll Surg Engl.* 1974 May;54(5):244-52.
25. Shafik A. The role of the levator ani muscle in evacuation, sexual performance and pelvic floor disorders. *Int Urogynecol J Pelvic Floor Dysfunct.* 2000 Dec;11(6):361-76. doi: 10.1007/pl00004028.
26. Shafik A, El-Sibai O. Effect of levator ani muscle contraction on urethrovesical and anorectal pressures and role of the muscle in urination and defecation. *Urology.* 2001 Aug;58(2):193-7. doi: 10.1016/s0090-4295(01)01196-7.
27. Shafik A, El-Sibai O. Effect of pelvic floor muscle contraction on vesical and rectal function with identification of puborectalis-rectovesical inhibitory reflex and levator-rectovesical excitatory reflex. *World J Urol.* 2001 Aug;19(4):278-84. doi: 10.1007/s003450100218.
28. Li D, Guo M. Morphology of the levator ani muscle. *Dis Colon Rectum.* 2007 Nov;50(11):1831-9. doi: 10.1007/s10350-007-0265-y.

29. Bush M, Petros P, Swash M, et al. Defecation 2: Internal anorectal resistance is a critical factor in defecatory disorders. *Tech Coloproctol.* 2012 Dec;16(6):445-50. doi: 10.1007/s10151-012-0860-3. (PubMed).
30. Shafik A, Shafik AA, Ahmed I. Role of positive anorectal feedback in rectal evacuation: the concept of a second defecation reflex: the anorectal reflex. *J Spinal Cord Med.* Winter 2003;26(4):380-3. doi: 10.1080/10790268.2003.11753709.
31. Shafik A, Shafik AA, El-Sibai O, Ahmed I. Study of the role of the second defecation reflex: anorectal excitatory reflex in the pathogenesis of constipation. *J Am Coll Surg.* 2003 May;196(5):729-34. doi: 10.1016/S1072-7515(03)00132-7.
32. Shafik A. The hypertonic rectosigmoid junction: description of a new clinicopathologic entity causing constipation. *Surg Laparosc Endosc.* 1997 Apr;7(2):116-20. (PubMed).
33. Shafik A, Ahmed I, El-Sibai O. Effect of perineal compression on the rectal tone: a study of the mechanism of action. *Dis Colon Rectum.* 2003 Oct;46(10):1366-70. doi: 10.1007/s10350-004-6751-6.